

Usefulness of Arterial Spin Labeling in the Evaluation of Moyamoya Disease

Eun Soo Kim¹, and Seung-Koo Lee²

¹Department of Radiology, Hallym University College of Medicine, Pyeongchon, Pyeongchon, Korea, Republic of, ²Department of Radiology, Yonsei University College of Medicine, Seoul, Seoul, Korea, Republic of

Dynamic susceptibility contrast (DSC) enhanced perfusion MRI (PWI) and arterial spin labeling (ASL) are clinically relevant and widely used techniques in the evaluation of occlusive cerebrovascular disease. DSC PWI is more widely used because easy availability of commercial scanners and post-processing programs. ASL provides absolute quantification of cerebral blood flow and it is free from various adverse effects of gadolinium contrast media including nephrogenic systemic fibrosis. Therefore ASL is more suitable with pediatric imaging with safer modality and better information of cerebral hemodynamics. We applied ASL in patients of moyamoya disease and tried to find clinical relevance in occlusive cerebrovascular disease.

Methods and Materials: Retrospective analysis was performed for patients who were diagnosed with moyamoya disease from January 2010 to July 2011, in total 19 patients (male: n=6, female: n=13, age: 6-35, mean age: 19). All patients were Suzuki grade III with preserved posterior circulation. Our routine MRI for moyamoya included T2WI, FLAIR, DWI and PWI including both ASL and DSC PWI. MRI was performed at 3T scanner (MAGNETOM Trio Tim, Siemens Medical Solutions, Erlangen, Germany). After acquisition of routine anatomical MRI, PICORE-Q2TIPS ASL (Arterial Spin Labeling) sequence was applied with the following parameters: TR=2000ms, TE=30ms, flip angle=80°, FOV=24cm, voxel size=4×4×8mm³, T1=700 ms, T1s=1200 ms, T12=1400ms. DSC perfusion MRI was performed by fat suppressed T2*W EPI with the following parameters: TR=1430ms, TE=46ms, FOV=23cm, 5mm thickness, 128x256matrix. Gadolinium contrast (Magnevist, Bayer, Germany) was injected with a power injector at a rate of 5mL/s in patients over age seven, and at rate of 1–2 ml/s in those under seven. Two experienced neuroradiologists (E.S.K., S.-K.L.) reviewed DSC PWI and ASL. We measured rCBF of the vascular territory divided by bilateral ACA, MCA and PCA on axial view of basal ganglia level. As DSC PWI was relative value, rCBF ratio was calculated as each territorial values divided by rCBF of cerebellum. Same measurement was done on ASL map. Bivariate correlation was used for comparison of rCBF between ASL perfusion MRI and the contrast perfusion MRI. P < 0.05 was considered significant.

Results: Bivariate correlation analysis revealed that rCBF ratio of DSC and ASL PWI was well correlated only in PCA territories (p<0.05), i.e. areas of intact proximal vessels. On visual analysis, most cases showed similar pattern of decreased perfusion in the affected territory (arrows in figure 1) and increased perfusion in the areas of basal collaterals (open arrow in figure 1). However, mismatched perfusion between DSC PWI and ASL was frequently seen in ACA and MCA territories (Fig. 2).

Conclusion: In most cases, ASL showed similar perfusion changes compared with DSC PWI. In severe proximal stenosis, ASL results were different from those of DSC PWI. Further investigation is needed to validate the results of ASL in occlusive cerebrovascular diseases.

Figure 1.

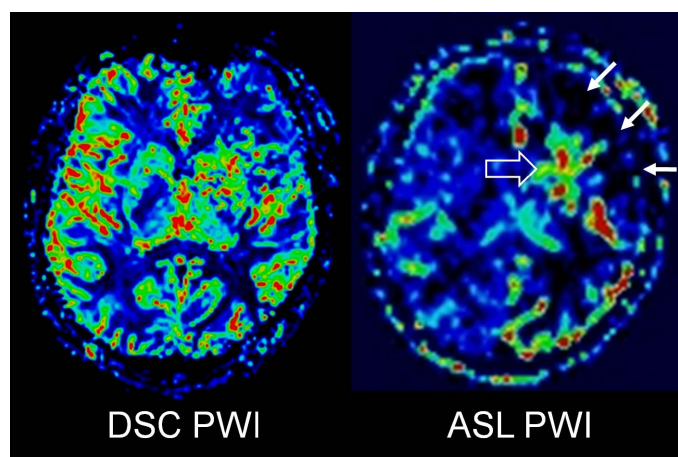


Figure 2.

