

Automatic, rapid, non-invasive and precise localization of thalamic nuclei for Deep Brain Stimulation (DBS) surgery using a combination of Diffusion and Functional MRI

Halleh Ghaderi^{1,2}, Abbas Sadikot³, Jennifer Campbell², and G. Bruce Pike^{2,3}

¹Biomedical Engineering, McGill University, Montreal, Quebec, Canada, ²McConnell Brain Imaging Center, Montreal, Quebec, Canada, ³Neurology and Neurosurgery, McGill University, Montreal, Quebec, Canada

Introduction

Deep brain stimulation (DBS) is a surgical treatment for Parkinson's disease that involves implanting electrodes in the thalamus of awake patients. The success of stereotactic DBS surgery is highly influenced by localization accuracy of the target (i.e. thalamic nuclei) to maximize therapeutic efficiency while minimizing adverse effect.

Current pre-operative DBS planning involves visual inspection of anatomical MRIs by a neurosurgeon to identify the target point for the electrode implant. Due to poor tissue contrast amongst the nuclei of the thalamus, the target is typically calculated based on other anatomical landmarks. In addition to pre-operative target localization, intra-operative microelectrode recording is necessary to physiologically confirm the target. During the surgery, manual refinement of the electrode's position may require multiple insertions, thus increasing the risk of complications. Moreover, the target localization procedure is complex, tedious and time consuming for the surgeon, and very uncomfortable for the patients, who need to stay awake during the whole surgery. In this study, we propose an automatic, rapid and non-invasive technique to accurately localize thalamic nuclei using a combination of diffusion imaging and functional MRI.

Methods

MRI Acquisition: Multi-modal MRI datasets were obtained from twenty-five Parkinson's disease patients using a 3T Siemens TIM Trio with 32-channel coil. First, a sagittal T1-weighted anatomical scan of the entire head with $1 \times 1 \times 1 \text{ mm}^3$ resolution was obtained using a 3D magnetization-prepared rapid gradient-echo (MP-RAGE) sequence (TR=2300ms, TI=900ms, TE=2.98ms, flip angle=9°). Second, two task-based fMRI experiments were performed by the subjects, a motor task and a sensory stimulus. The resolution of the fMRI scans was $4 \times 4 \times 4 \text{ mm}^3$. The motor task involved alternative finger tapping with an auditory signal to control for the frequency of tapping (90 beats per min). For the sensory task, a custom-made hand vibrotactile stimulator [1] was used to activate somatosensory pathways and particularly the sensory thalamus. Finally, High Angular resolution Diffusion Images (HARDI) were acquired ($b = 1000 \text{ s/mm}^2$, 99 directions, resolution $2.0 \times 2.0 \times 2.0 \text{ mm}$ isotropic voxels).

Data preprocessing: Standard data analysis including slice timing correction, spatial registration, linear detrending and spatial smoothing using a 6 mm FWHM Gaussian filter were applied to the fMRI data to extract activated cortical and sub-cortical motor and sensory areas of the brain. Then, we took advantage of the fact that the cytoarchitecturally distinct nuclei of the thalamus have different patterns of anatomical connectivity to cortex [2] to validate our functional localization. To do so, the fMRI-based sensory and motor activation areas in the thalamus (VA and VPL nuclei) were resampled to match the diffusion data and these areas were used as seed regions for diffusion tractography, which was performed using the FACT [3] and Maxima (or Spherical Deconvolution) [4] tractography algorithms.

All the processing has been done using fMRISat and MincDiffusion Toolbox developed at Montreal Brain Imaging Center and McGill department of Mathematics and statistics.

Results

In our cohort of 25 patients, we have been able to reliably parcellate the VA and VPL nuclei of the thalamus via these fMRI experiments. Figure 1 shows sample coronal, sagittal and axial views of the fMRI activations in one patient. The green activation area corresponds to the VPL nucleus of the thalamus and red to the VA nucleus.

Figure 2 shows the thalamocortical pathways that were reconstructed using two different tractography algorithms. In the FACT algorithm, shown in Part A and B, streamline tractography was performed by following the principal eigenvector direction, as described by Mori et al. in 1999. On the other hand, in Maxima algorithm (or spherical Deconvolution), shown in Part C and D, the streamline tractography was performed by following the fibre ODF (orientation distribution function) maximum closest to the incoming vector direction, as described by Campbell et al. in 2006. Using the Maxima algorithm (Spherical Deconvolution approach), we were able to see more lateral cortical connections and the tractography was able to track up to the cortical grey matter.

Discussions and Conclusions

This work combined two imaging modalities (diffusion and fMRI) and demonstrated a novel technique to precisely localize the target for DBS surgery non-invasively and quickly. Each thalamic nucleus has a unique connection to cortex; therefore, the reconstructed thalamocortical pathways not only validate and confirm the precise location of VPL and VA, but they also can be used as anatomical landmarks to guide the surgeon to his target. Consequently, this method could enhance the success of DBS surgery for Parkinson's patients.

References

[1] Chakravarty, M.M.; Rosa-Neto, P.; Broadbent, S.; Evans, A.C.; Collins, D.L.; "Development of fMRI techniques for planning in functional neurosurgery for Parkinson's disease," Biomedical Imaging: From Nano to Macro, 2008. ISBI 2008. 5th IEEE International Symposium on, vol., no., pp.1259-1262, 14-17 May 2008

[2] Jones, E.G., *The Thalamus*, Plenum Press, New York, 1985

[3] Mori S, Crain BJ, Chacko VP, van Zijl PCM. Three-dimensional Tracking of Axonal Projections in the Brain by Magnetic Resonance Imaging. *Ann Neurol*. 1999; 45(2): 265-269.

[4] [Campbell et al, 2006] Campbell, J.S.W., Savadjiev, P., Siddiqi, K. and Pike, G.B. Validation and regularization in diffusion MRI tractography. In IEEE International Symposium on Biomedical Imaging Conference Proceedings, pages 351-354, 2006.

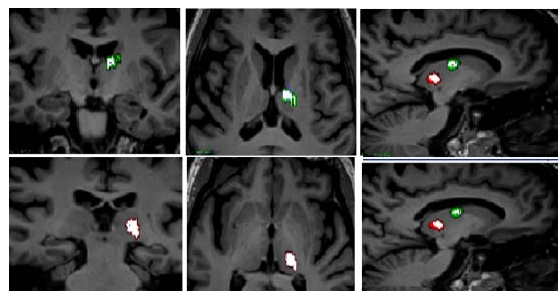


Figure 1-fMRI Thalamic nuclei Activation areas (Hand-sensory nuclei :VPL in Green ,Hand-Motor nuclei :VA in Red)

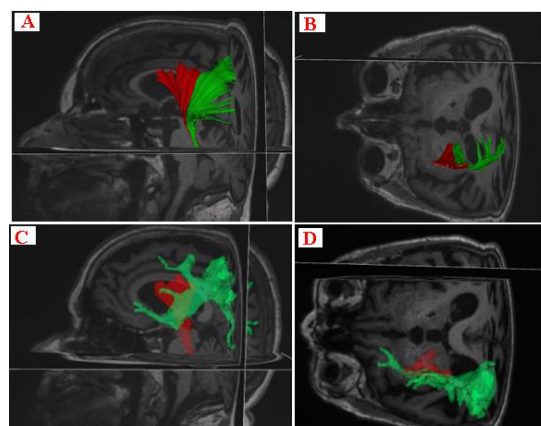


Figure 2-Thalamocortical tracts in Sagittal and Axial View (Green- Sensory tracts, Red: Motor)