

Automated assessment of regional lung perfusion in cystic fibrosis patients by using Fourier decomposition MRI

Grzegorz Bauman¹, Tobias Heimann², Eva Fritzsche³, Wolfhard Semmler¹, Michael Puderbach^{3,5}, and Monika Eichinger⁴

¹Dept. of Medical Physics in Radiology, German Cancer Research Center (DKFZ), Heidelberg, Germany, ²Dept. of Medical and Biological Informatics, German Cancer Research Center (DKFZ), Heidelberg, Germany, ³Division of Pediatric Pulmonology & Allergy and Cystic Fibrosis Center, University Hospital Heidelberg, Heidelberg, Germany, ⁴Dept. of Radiology, German Cancer Research Center (DKFZ), Heidelberg, Germany, ⁵Clinics for Interventional and Diagnostic Radiology, Chest Clinics at the University of Heidelberg, Germany

Introduction

Cystic fibrosis (CF) is the most frequent autosomal recessive disorder responsible for premature death in the Caucasian population. In CF the genetically induced aberrations of volume and composition of airway surface fluid lead to chronic lung infection and impairment of pulmonary perfusion and ventilation [1]. Several magnetic resonance imaging (MRI) techniques have been developed for the assessment of regional lung perfusion. Nowadays, the standard lung perfusion MRI technique is dependent on the administration of gadolinium based contrast agent. An alternative contrast-free method called Fourier decomposition MRI (FD MRI) has been recently proposed [2,3]. FD MRI utilizes very short-echo time imaging of the native proton signal with subsequent image registration and spectral analysis to generate perfusion- and ventilation-weighted images. Since visual scoring of functional lung defects poses a problem for accurate reproducibility [4] an automated assessment is highly desirable. The goal of this work was to validate an automated scoring system of regional perfusion defects for data acquired by using Fourier decomposition MRI in patients with CF.

Methods

MR imaging and postprocessing

Thirty three CF patients (mean age 6.79 years, range: 0.16 – 30 years) were examined. Measurements were performed on a 1.5 T MR-scanner (Magnetom Avanto, Siemens Healthcare, Germany) using a combination of 6-channel body and 24-channel spine matrix coil. In every patient sets of coronal lung images were acquired by using an untriggered time-resolved 2D balanced steady-state free precession (bSSFP) sequence. The imaging parameters were as follows: TR/TE/TA = 1.9/0.8/116 ms, 4 images/s, FA=75°, ST=10 mm, FOV=350-450 mm², GRAPPA factor=3, matrix=128x128, bandwidth=1302 Hz/px. A time interval of TW=134 ms was set between each single image acquisition, which allowed for partial recovery of the longitudinal magnetization. A total acquisition time per slice of T=49.5 s, a spectral resolution of $\Delta f=1/T=0.017$ Hz and a spectral width of $f_B=1/[2(TA+TW)]=2$ Hz were achieved. Respiratory motion was corrected by application of a nonrigid image registration algorithm [5]. Subsequently, the first image in every acquired slice was semi-automatically segmented [6]. The segmentation mask propagated through a whole data set. Fourier decomposition was used to detect and separate periodic changes of lung proton density caused by respiratory and cardiac cycles. Perfusion-weighted (Qw) images were created by pixel-wise integration of cardiac spectral line.

Visual and automated perfusion defects evaluation

A dedicated scoring system was used for visual and automatic evaluation of perfusion defects in FD MRI images. Each lung was divided into three fields equally distanced along the apical-basal direction. The functional scores (F scores) in every field were distributed as shown in table 1. Distributions of pixel values were statistically analyzed to automatically calculate the percentage of pathologic tissue in lung areas. Pixel values in the 20%-quantile were regarded as regions with impaired perfusion. Subsequently, scores were assigned to every field. Visual assessment was independently performed by two readers (R1, R2). Correlations between both evaluation methods were determined.

Results

Figure 1 shows process of segmentation and quantification of perfusion defects in a Qw image. Mean score per slice was 5.46 ± 2.82 (R1), 5.20 ± 2.69 (R2), and 5.24 ± 2.07 for automated assessment. Spearman's correlation coefficient between the visual and automated scoring for corresponding lung areas from all generated Qw images was 0.711 for R1 and 0.701 for R2 with $P<0.05$. The strongest correlation was observed in the upper lung areas 0.810 (R1), 0.775 (R2), and the weakest in the pericardial area 0.566 (R1), 0.593 (R2) due to difficult segmentation and pulsation artifacts in this region. Diagrams in figure 2 present correlations between F-scores assigned per patient using both assessment methods. Prevalence of perfusion defects in the lower lung regions was on average 1.95 (R1), 1.78 (R2), and 1.85 for automated scoring times higher than in the upper lung regions. The ability of this method to quantify regional changes of lung perfusion after an intravenous antibiotic therapy is demonstrated in figure 3.

Discussion

The contrast-media-free FD MRI is a well-suited functional imaging technique for chronically ill children and young adults requiring frequent examinations or patients with renal dysfunction. The technique shows a good agreement with dynamic contrast-enhanced MRI in CF patients [7]. This work proves that automated assessment of regional perfusion defects in CF patients using FD MRI is feasible, accurate and comparable to visual scoring. This diagnostic method could be applicable for reproducible and reader independent detection of early and subtle functional impairment. Hence, it can be used as noninvasive monitoring of therapy response and longitudinal follow-up.

References:

- [1] Gibson RL et al. Am J Respir Crit Care Med 168:918-951
- [2] Deimling M et al. Proc. of ISMRM 2008, Toronto, Canada, p. 2202
- [3] Bauman G et al. Magn Reson Med 2009, 62(3):656-64
- [4] Eichinger et al. Eur J Rad 2011, 21 Mar [Epub ahead of print]
- [5] Ched'hotel C et al. Proc. of IEEE (VLSM'2001), Vancouver, Canada;
- [6] Maleike D et al. Comp Meth Prog Bio 2009 96(1):72-83
- [7] Bauman G et al. Am J Respir Crit Care Med 181(1);2010

Score	Defects in a lung area	
	Automated	Visual
2	$\geq 50\%$	$\geq 50\%$
1	$<50\%$ and $\geq 7.5\%$	$<50\%$
0	$<7.5\%$	no defects

Table 1. F-score distribution for automated and visual assessment (range per slice: 0 – 12).

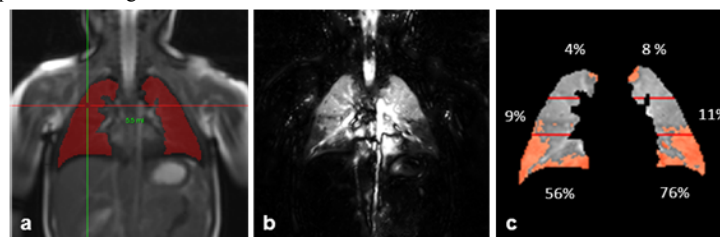


Figure 1. Semi-automatic lung segmentation of SSFP data in a 4 years old male CF patient (a), perfusion-weighted FD MRI (b), quantification of regional perfusion defects (c). Percentage of the impaired tissue has been estimated for every lung area.

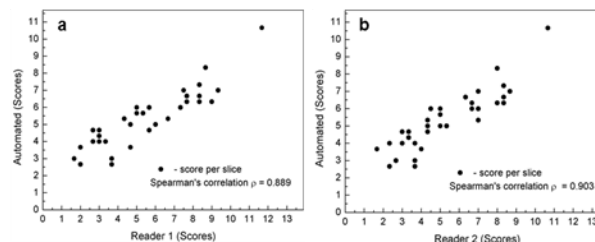


Figure 2. Spearman's correlations between F-scores assigned for each patient with CF by using automated and visual evaluation.

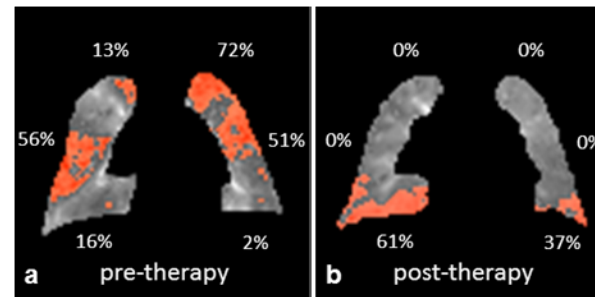


Figure 3. Visualisation and quantification of perfusion defects in a 6 month old boy with CF before (a) and 3 month after a course of intravenous antibiotic therapy in a corresponding slice location (b). The total lung score/slice improved from 8 to 3 after therapy.