

## Significant reduction of grey matter loss with vitamin B treatment in cognitively impaired elderly

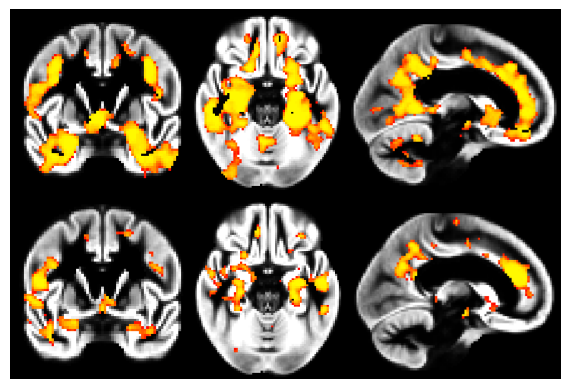
Gwenaëlle Douaud<sup>1</sup>, Helga Refsum<sup>2</sup>, Celeste de Jager<sup>2</sup>, Robin Jacoby<sup>2</sup>, Stephen Smith<sup>1</sup>, and A. David Smith<sup>2</sup>  
<sup>1</sup>FMRIB Centre, University of Oxford, Oxford, Oxfordshire, United Kingdom, <sup>2</sup>OPTIMA, University of Oxford

**Introduction** Moderately raised plasma total homocysteine (tHcy) is found in Alzheimer's disease (AD) and vascular dementia, and is associated with increased risk of dementia and cognitive decline (Dufouil et al., 2003; meta-analysis in Wald et al., 2011). Concentrations of tHcy are largely determined by the body's status of certain B vitamins (folate, B6 and B12), which are cofactors or substrates for enzymes involved in homocysteine metabolism (Refsum et al., 2004). Several clinical trials have investigated the effect of high doses of B vitamins to lower tHcy with inconsistent results on cognitive outcomes (meta-analyses in Dangour et al., 2010 and Wald et al., 2010). This discrepancy might be due to differences in the combination of B vitamins used, their dosage, the duration of treatment, the population size and the population cognitive/clinical status – as most of them included participants who were either healthy or who already had dementia. This study, the VITACOG trial, therefore focused on elderly participants showing cognitive impairment – but not dementia – who were followed for two years. We previously reported that B vitamin treatment reduced *whole-brain* atrophy by 30% (Smith et al., 2010). However, it remains unanswered whether this reduction of atrophy actually corresponds to **regions vulnerable to the AD process and showing significant atrophy in the placebo group**.

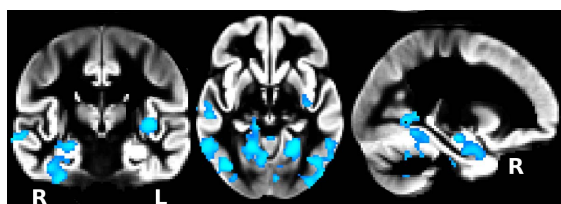
**Methods** Of the initial 223 participants over 70 years old with mild cognitive impairment, 156 volunteers (76 placebo, 80 vitamin) underwent the same imaging protocol with T1-weighted images of sufficient quality at baseline and after 2 years (1.5T MRI Sonata system, 1 mm<sup>3</sup>,  $\alpha=19^\circ$ , TR/TE=12/5.65 ms, 3 averages). To assess differences in the distribution of grey matter (GM) between the vitamin and placebo groups, an optimised FSL-VBM analysis was carried out (Douaud et al., 2007; Smith et al., 2004). Both groups were matched for age, gender and age $\times$ gender. Finally, we used permutation-based nonparametric inference within the framework of the general linear model (5000 permutations) (Nichols & Holmes, 2002) and tested for GM changes between baseline and follow-up scan in placebo and vitamin groups, as well as for *differences* in the GM changes between the two groups. Results were considered significant for  $P<0.05$  corrected for multiple comparisons (after initial cluster-forming thresholding at  $P<0.05$  uncorrected).

**Results** We found significant widespread regional loss of GM in both the placebo and vitamin groups over the 2 year intervention period. However, the GM loss was substantially larger for the placebo group than for the vitamin group, especially in temporo-occipital and cerebellar regions (**Figure 1**). Changes over time were significantly different between the two groups, with a reduction of atrophy in the vitamin group bilaterally in the hippocampus, fusiform gyrus, retrolimbic precuneus, supramarginal gyrus, middle and inferior temporal gyrus, lingual gyrus, cerebellum I, V and vermis, as well as in the left parahippocampal gyrus and right angular gyrus and planum temporale (**Figure 2**). When investigating further by splitting each group into high vs. low level of tHcy at baseline ( $>$  or  $\leq 11$   $\mu\text{mol/L}$ , this threshold being the median tHcy for all participants), we found that: (i) higher levels of tHcy were associated with significantly increased GM loss when compared to low levels in the placebo group, but *not* in the vitamin B group (data not shown), (ii) B vitamins had a significant effect on reducing GM loss in those participants who had high levels of tHcy, but *not* low tHcy levels (**Figure 3**).

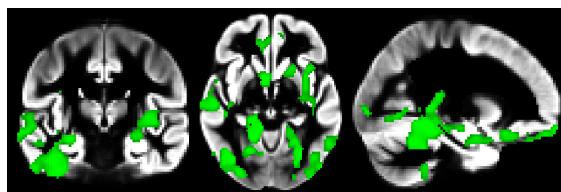
**Discussion and Conclusion** This is the first study reporting a significant benefit of B vitamins in slowing brain atrophy in GM regions consistently affected in mild cognitive impairment and AD (e.g., Fennema-Notestine et al., 2009), but also in regions showing a marked loss of GM over the 2 year period in the placebo group. Remarkably, our results also showed that increased level of tHcy at baseline corresponded to significantly increased GM atrophy (data not shown), but that **this deleterious effect was compensated for by the B vitamin treatment**. We further demonstrated that B vitamin treatment was significantly **beneficial for participants with high tHcy** ( $>11$   $\mu\text{mol/L}$ ) only. Our findings therefore establish the positive effect of B vitamin treatment on disease-targeted regions of the brain in cognitively impaired elderly with high tHcy levels, in line with the beneficial cognitive outcomes shown in the same trial (de Jager et al. 2011).



**Figure 1:** Significant GM loss (*top*: placebo; *bottom*: vitamin)



**Figure 2:** Significant reduction of GM loss in vitamin compared to placebo group



**Figure 3:** Significant reduction of GM loss in vitamin compared to placebo group, high tHcy only