

The Effect of Maternal Smoking on Fetal Organ Growth

Devasuda Anblagan¹, Nia W Jones², Alexander J Parker³, George Bugg², Carolyn Costigan¹, Ruta Deshpande², Lucy Coyne⁴, Rosanne Aleong⁵, Neil Roberts⁶, Zdenka Pausova^{7,8}, Nick Raine Fenning⁹, Tomas Paus^{5,10}, and Penny A Gowland¹

¹Sir Peter Mansfield Magnetic Resonance Centre, University of Nottingham, Nottingham, Nottinghamshire, United Kingdom, ²Nottingham University Hospitals NHS Trust, Nottingham, Nottinghamshire, United Kingdom, ³University of Aberdeen, Aberdeen, United Kingdom, ⁴Liverpool Women's Hospital, Liverpool, United Kingdom, ⁵Rotman Research Institute, University of Toronto, Toronto, Ontario, Canada, ⁶Clinical Research and Imaging Centre, Queens Medical Research Institute, Edinburgh, United Kingdom, ⁷Research Institute of the Hospital for Sick Children, University of Toronto, Toronto, Ontario, Canada, ⁸Universite de Montreal, Montreal, Quebec, Canada, ⁹School of Clinical Sciences, University of Nottingham, United Kingdom, ¹⁰School of Psychology, University of Nottingham, United Kingdom

Introduction: Smoking during pregnancy has been associated with miscarriage, placenta abruption, placenta praevia, low birth weight and perinatal mortality. In the long-term, maternal smoking during pregnancy appears to increase the probability of respiratory disorders, obesity and behavioral problems¹. Cigarette smoke contains two main compounds: carbon monoxide and nicotine; both cross the placenta into the fetus where they reach levels exceeding those found in the maternal circulation². This work studies the effects of maternal smoking on the growth of different fetal organs and the placenta. **Aim:** To investigate the effect of maternal smoking on the growth of the fetal lungs, kidneys, liver, brain and placenta.

Methods: **Scanning:** Following approval by the ethics committee, we recruited 18 healthy pregnant women from Queen's Medical Centre Nottingham: 10 current smokers and 8 non-smokers matched for age, parity, BMI and education level; all gave informed consent to participate in the study. Pregnant women's self-reported smoking habits were recorded. Pregnant women were scanned twice: Visit 1 (22–27 weeks of gestational age [GA]) and Visit 2 (33–38 GA) using 1.5 T Philips Achieva MRI scanner with 5-element SENSE cardiac coil or 4-element SENSE torso coil, depending on the woman's size. Women lay on their right side in the decubitus position to avoid compression of the vena cava. All scans were conducted with a specific absorption rate of $<2.0 \text{ W kg}^{-1}$. Three sequences were acquired to study fetal growth: (1) Half Fourier Single Shot Turbo Spin-Echo for the whole body (HASTEbody, 123 slices in 147 seconds, TE = 120 ms and $0.78 \times 0.78 \times 6.00 \text{ mm}^3$ voxels); (2) high resolution HASTE to study the brain (HASTEbrain, 34 slices in 35.8 seconds, TE = 120 ms and $0.59 \times 0.59 \times 4.50 \text{ mm}^3$ voxels); and (3) Balanced Fast Field Echo for the abdominal organs (bFFE, 130 slices in 167 seconds, TR = 5.8 ms, TE = 2.3 ms, flip angle = 70° and $0.78 \times 0.78 \times 6.00 \text{ mm}^3$ voxels). All sequences were acquired in three orthogonal blocks of images and without a breath hold to allow for motion effects to be averaged out.

Analysis: The volume of the fetal kidneys and lungs were measured on at least two sets of images using a semi automatic segmentation method based on edge detection (Analyze 9.0). These were generally HASTEbrain for lung and bFFE for kidney; HASTEbody was used if these sets of data were seriously affected by artefact (generally motion or image non-uniformity artefacts). Volumes of the fetal liver and fetal brain were measured on three orientations of HASTE images using the Cavalieri method in combination with point counting^{3,4} using EasyMeasure software⁵. Measurements for each organ were averaged; the individual measurements varied by approximately 0–10% of the mean across all fetuses. The total fetal volume was measured by drawing a freehand mask around the fetus using Analyze 9.0.

Results: The effect of exposure on the volume of fetal organs was assessed using a mixed model ANCOVA. Each independent analysis of the six organs included one within-subject variable (Visit) and one between-subject variable (Exposure). Four covariates were included in all analyses: maternal education, gestational age at visit 1, the difference in gestational age between visit 1 and 2, and fetal sex. For lung volume, a significant effect of Exposure was found [$F(1,12) = 7.544, p < 0.05$] with exposed fetuses showing lower lung volume than non-exposed controls across both Visits. For kidney volume, there is a significant interaction between Exposure and Visit [$F(1,12) = 20.857, p < 0.01$], with exposed fetuses showing lower kidney volume compared with non-exposed fetuses at Visit 1 ($p < 0.05$; Cohen's $d = 1.6$) and Visit 2 ($p < 0.001$; $d = 1.9$). For brain volume, exposed fetuses showed significantly lower brain volume than non-exposed controls at Visit 2 ($p < 0.05$; $d = 1.0$) but not at Visit 1 ($d = 0.1$); Exposure by Visit interaction approached significance [$F(1,12) = 3.676, p = 0.079$]. The liver volume did not show a statistically significant effect due to exposure. There is a significant interaction between Exposure and Visit for total fetal volume [$F(1,12) = 9.507, p < 0.01$]. Post-hoc comparisons revealed that exposed fetuses showed lower total volume compared with non-exposed controls at Visit 1 ($p < 0.01$; $d = 1.8$) and Visit 2 ($p < 0.01$; $d = 2.1$). For fetal placenta volume, a significant effect of Exposure was found [$F(1,12) = 6.874, p < 0.05$] with exposed fetuses showing lower placenta volume than non-exposed controls across both visits (Visit 1: $d = 0.88$; Visit 2: $d = 0.37$).

Discussion: Fetal lung, kidney and brain volumes are reduced by maternal smoking during pregnancy; late in pregnancy (33–38 GA), the group differences are of large effect sizes, with Cohen's d values equaling 0.36 (placenta), 1.0 (brain), 1.9 (kidneys) and 2.1 (total fetal volume).

Conclusions: Maternal smoking during pregnancy reduces growth in all organs measured except the liver.

References: [1] R.L. Andres, et al. (2000). *Neonatology* 5 231-241. [2] G. Koren. (1995). *Pediatrics* 7 128-131. [3] N. Roberts, et al. (1994). *The British Journal of Radiology*, 67, 1067-1077. [4] Gong, Q.Y, et al. (1998). *Magnetic Resonance Imaging*, 16, 235-240. [5] N. Roberts, et al. (2000). *The British Journal of Radiology*, 73, 679-697. **FUNDED BY UNIVERSITY OF NOTTINGHAM.**

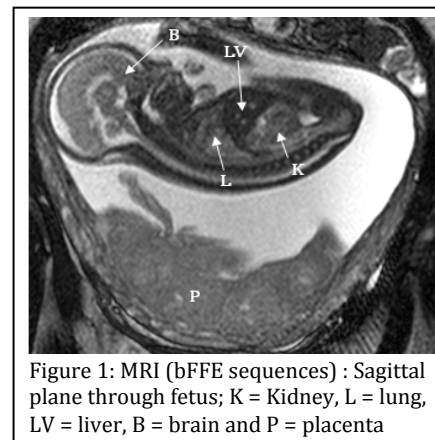


Figure 1: MRI (bFFE sequences) : Sagittal plane through fetus; K = Kidney, L = lung, LV = liver, B = brain and P = placenta

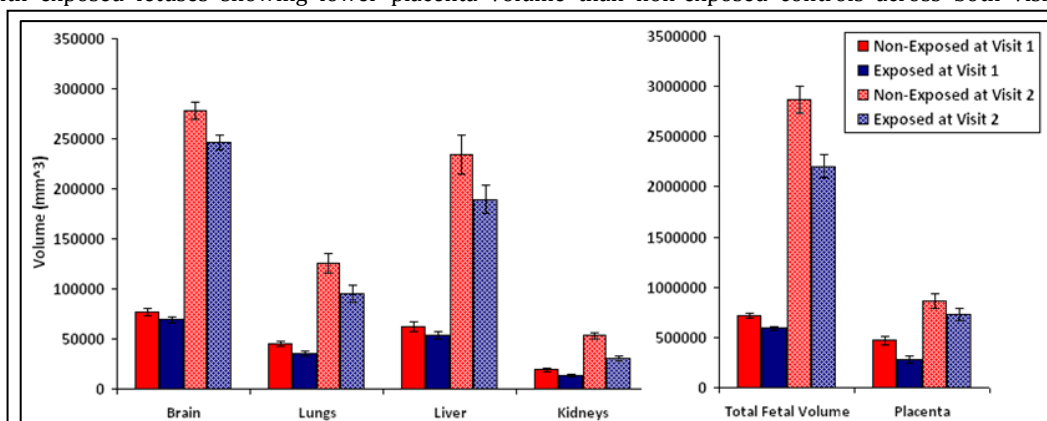


Figure 2: Effect of maternal smoking on fetal brain, lungs, liver, kidneys, placenta and total fetal volume.