

Diffusion properties of uterine fibroids pre- and post- uterine fibroid embolization

Jennifer W Chong¹, Natalie Yang², Sarah J Jenkins³, Errol Colak¹, Shalini Anthwal¹, Andrew A Common¹, Vikram Prabhudesai¹, and Anish Kirpalani¹

¹Department of Medical Imaging, University of Toronto, St. Michael's Hospital, Toronto, ON, Canada, ²Department of Radiology, Austin Health, Heidelberg, Australia,

³Department of Diagnostic Imaging, Memorial University, St. John's, NL, Canada

Background:

Uterine fibroid embolization (UFE) is a non-invasive, safe, and effective method of treating symptomatic uterine fibroids [1, 2]. The current standard of practice is to use gadolinium (GBCA)-enhanced pelvic MRI to help monitor the treatment response by assessing for decrease in volume and vascularity of fibroids post-UFE. Diffusion-weighted MRI (DWI) can yield quantitative data such as the apparent diffusion coefficient (ADC), which has been shown to rise significantly when tumours elsewhere in the body become devascularized or necrotic [3].

Purpose:

To determine if: (a) the ADC of uterine fibroids changes following UFE, and (b) the change in ADC or the pre-UFE ADC value itself can predict response to treatment.

Methods:

In this prospective cohort study, we added a DWI sequence to the 1.5T pelvic MRI examination performed routinely on patients prior to and 6 months following UFE. DWI was performed with free-breathing respiratory-triggered single shot echoplanar imaging using four b-values (0, 250, 500 and 750 s/mm²), and an ADC map was generated using all b-values. The pelvic MRI examinations of 50 consecutive UFE patients (n = 88 fibroids) performed pre- and post-UFE were then analysed. These examinations also included axial T1 FFE, multiplanar T2 TSE, and T1 THRIVE pre- and post-gadolinium imaging (Philips Medical Systems). In patients with more than one fibroid, the two largest fibroids in each patient were assessed both pre- and post- UFE. The location, volume, T1 signal and T2 signal of all 88 fibroids were recorded on both the pre-UFE and post-UFE scans. ADC values were calculated for each of the 88 fibroids both pre-UFE and post-UFE by placing one circular region of interest (ROI) on each ADC map to include as much of the fibroid as feasible without involving artefact (Figure 1). Using this same ROI method, the amount of enhancement in each fibroid (standardized to ischioanal fat signal intensity) was calculated and the difference in enhancement between pre-UFE and post-UFE exams was recorded for each of the 88 fibroids. To avoid statistical bias, each fibroid was then categorized based on the percentage of residual enhancement as either: "no significant residual enhancement" (0-20% residual enhancement; i.e. significant loss of vascularity), "some residual enhancement" (21%-80%), and "no significant change in enhancement" (>80%; i.e. no change in vascularity). Standardized T2 signal intensity was also calculated for each fibroid. Statistical analysis of these calculations on each fibroid in both the pre-UFE and post-UFE scans was performed by a biostatistician using mean, standard deviation, paired t-test, Pearson / Spearman correlation and ANOVA tests.

Results:

The mean ADC of all fibroids pre-UFE was $1.30 \pm 0.20 \times 10^{-3} \text{ mm}^2/\text{s}$. The mean ADC of all fibroids post-UFE was $1.68 \pm 0.24 \times 10^{-3} \text{ mm}^2/\text{s}$, representing a statistically significant increase ($p < 0.0001$). There was a negative correlation between the pre-UFE ADC and the percentage change in ADC post-UFE (Pearson correlation co-efficient = -0.59), seen in Figure 2. We also found a statistically significant correlation between pre-UFE ADC and the change in enhancement following UFE: fibroids which showed no significant residual enhancement (ie, significant loss of vascularity) post-UFE had a mean pre-UFE ADC of $1.28 \pm 0.18 \times 10^{-3} \text{ mm}^2/\text{s}$, while fibroids which showed no significant change in enhancement post-UFE had a mean pre-UFE ADC of $1.45 \pm 0.26 \times 10^{-3} \text{ mm}^2/\text{s}$ ($p = 0.036$). Overall, there was successful devascularization of uterine fibroids post-UFE: 74 of 88 fibroids demonstrated no significant residual enhancement post-UFE and a further 5 of 88 showed only some residual enhancement. No correlation was found between the pre-UFE ADC and change in T2 signal or fibroid volume.

Conclusion:

ADC quantification of uterine fibroids both pre-and post-UFE is a feasible method using multiple b-value DWI in pelvic MRI and our results demonstrate that there is a change in DWI properties of uterine fibroids following UFE. The statistically significant rise in ADC following post-UFE is expected given the cellular necrosis and loss of vascularity post-UFE; this treatment response is also seen in malignant tumours. The negative correlation between pre-UFE ADC and percentage change in ADC suggests that fibroids undergoing some degeneration prior to UFE show relatively less cellular breakdown post-UFE. Finally, we showed that fibroids which have more residual contrast enhancement post-UFE had a higher pre-UFE ADC. This residual vascularity may be clinically significant in patients who present with recurrent symptoms post-UFE due to fibroid regrowth. ADC may thus be important in counselling patients regarding treatment response if loss of vascularity and ADC change correlate with symptomatic relief post-UFE. This additional analysis of patient symptom data pre- and post-UFE is the subject of future work.

References:

1. Worthington-Kirsch, R.L., G.L. Popky, and F.L. Hutchins, Jr., *Uterine arterial embolization for the management of leiomyomas: quality-of-life assessment and clinical response*. Radiology, 1998. **208**(3): p. 625-9.
2. Goodwin, S.C., et al., *Uterine artery embolization for the treatment of uterine leiomyomata midterm results*. J Vasc Interv Radiol, 1999. **10**(9): p. 1159-65.
3. Padhani, A.R., et al., *Diffusion-weighted magnetic resonance imaging as a cancer biomarker: consensus and recommendations*. Neoplasia, 2009. **11**(2): p. 102-25.

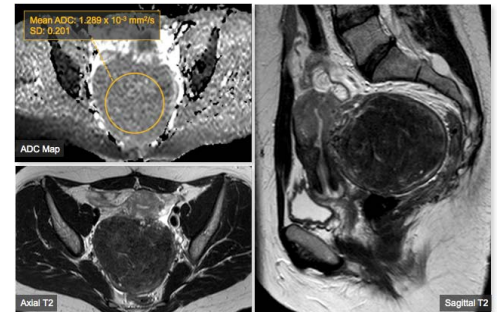


Figure 1: Large subserosal fibroid arising from the posterior uterus, with an ADC value of $1.289 \times 10^{-3} \text{ mm}^2/\text{s}$.

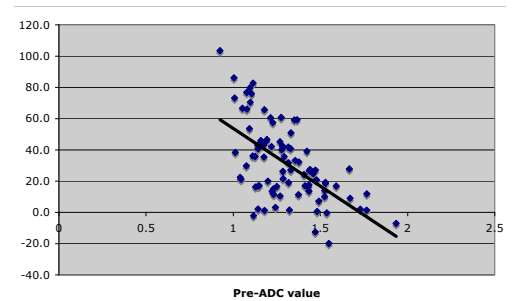


Figure 2: Relationship of % change in ADC (y-axis) and pre-UFE ADC (x-axis). The negative correlation has a Pearson correlation co-efficient of -0.59.