

Sodium Imaging of the Prostate at 3T

Daniel Hausmann¹, Simon Konstandin², Frank G Zöllner², Stefan Haneder¹, Friedrich Wetterling², Armin M Nagel³, Dietmar J Dinter¹, Stefan O Schönberg¹, and Lothar R Schad²

¹Institute of Clinical Radiology and Nuclear Medicine, University Medicine Mannheim, Mannheim, Germany, ²Computer Assisted Clinical Medicine, University Medicine Mannheim, Mannheim, Germany, ³Department of Medical Physics in Radiology, German Cancer Research Center, Heidelberg, Germany

Introduction:

Generally, conventional T2-weighted MRI provides detailed information about the anatomic structures of the prostate with an excellent spatial resolution at 3 Tesla. The multiparametric MR imaging approach of the prostate involves further functional sequences to increase specificity of the examination. There are numerous studies about elevated sodium levels in malignant tumours. Recent studies indicate a potential value of sodium imaging as a radiological biomarker for cancer treatment response (1). To our knowledge, there is only one study on sodium imaging of the prostate in a murine model at 9.4 T. Quantification of sodium of the prostate was feasible due to high sodium levels of the ventral gland (2). The purpose of this study was to evaluate the feasibility of sodium imaging and quantification as a tool of possible additional value for multiparametric imaging of the prostate in a clinical setting in human volunteers at 3 T.

Methods:

All measurements were performed on a 3 Tesla clinical whole-body MR scanner (Magnetom TimTrio 32x102, Siemens Healthcare Sector, Erlangen, Germany). For signal reception a dedicated sodium-tuned cardiac coil with 8 coil elements (Rapid Biomedical, Würzburg, Germany) was used. It consists of two identical halves with a transmit loop and four receive-only channels each. The coil was tightly fixed around the volunteers and covered a coronar field-of-view of 320 x 320 mm². Beside the torso, standardized 0.6% and 0.9% NaCl-dilutions including 2% agarose were covered in the field-of-view serving as calibration phantoms. Based on the comparison of these phantoms, an analog increase of the sodium signal intensities compared to the sodium concentrations was estimated. For adjusting the inhomogeneity of the coil a priori, a homogeneous sodium phantom was measured as reference. According to this reference, all images of the volunteers were corrected. For the sodium concentration map, a density adapted 3D radial trajectory was used for acquisition (3) with the following parameters: TR = 120 ms, TE = 0.55 ms, flip angle = 85°, FOV = 320x320 mm², readout length per spoke = 20 ms, projections = 8000 resulting in a total scan time of 16 min. The nominal isotropic spatial resolution was 5 mm. After institutional review board approval and informed consent, eight healthy volunteers were included. DWI- and T2-images with a ¹H-body-coil are acquired additionally for correlation of the findings.

Results:

Eight healthy volunteers 23-34 years old (mean = 28 years) were enrolled. A T2-weighted, a fusion of ADC map and T2, and a sodium image is shown in axial view (Figure 1). The prostate and its different compartments were identifiable in all eight volunteers, exemplarily shown in Figure 2. A mean ²³Na-concentration of 55 mmol/l (± 15 mmol/l) in the central (range: 24 – 70 mmol/l) and 69 mmol/l (± 16 mmol/l) in the peripheral zone (range: 34 – 85 mmol/l) was measured (Table 1a). In two volunteers the examination was repeated to evaluate the reliability of Na²³-quantification (Table 1b).

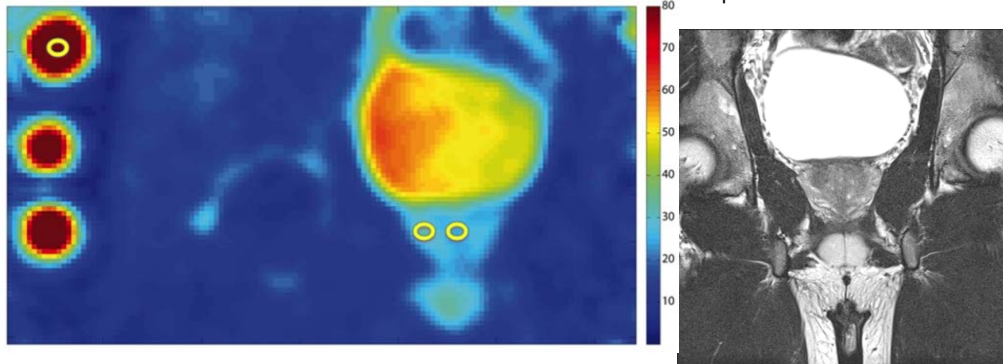


Figure 1: T2 (upper left), fusion of coloured ADC map and T2 (upper right) and sodium (lower) axial images of the prostate of a young healthy volunteer.

Figure 2: Sodium concentration map (left) and T2-weighted image (right) in coronar view. Beside the torso, standardized 0.6% and 0.9% NaCl-dilutions including 2% agarose were covered in the field-of-view serving as calibration phantoms.

Discussion:

²³ Na-concentration [mmol/l] (n=2)	1.	2.	Δ
peripheral zone	74	74	0
central zone	64	52	12
peripheral zone	73	79	6
central zone	60	63	3

²³ Na-concentration [mmol/l] (n=8)	Minimum	Maximum	Mean	SD
central zone	24	70	55	15
peripheral zone	34	85	69	16

Table 1b (upper) and a (lower): The results of sodium quantification within the prostate indicate a higher ²³Na- concentration in the peripheral than in the central zone. Table 1b shows reproducibility of the results of ²³Na-quantification in two probands on a first and a second examination

This study suggests that sodium imaging on a clinical 3T scanner might be an appropriate, noninvasive method for imaging of the human prostate. A double resonant endorectal coil system could contribute to increase spatial resolution, to reduce examination time and to enable a more accurate and reliable quantification. Ex vivo studies on cancerous prostate tissue are necessary to evaluate if changes of the sodium levels are apparent in prostate cancer.

References:

1. Jacobs MA et al. Breast Cancer Res Treat 128(1):119-26. (2011)
2. Near J et al. Magn Reson Med 63(3):822-7 (2010)
3. Nagel AM et al. Magn Reson Med 62(6):1565-73 (2009)