

# SERIAL EFFECTS OF IODINATED CONTRAST MEDIA ON THE RENAL HEMODYNAMICS AND OXYGENATION AS EVALUATED BY ASL AND BOLD MRI

Jing Wang<sup>1</sup>, Yudong Zhang<sup>2</sup>, Xuedong Yang<sup>2</sup>, Xiaoying Wang<sup>2</sup>, Jue Zhang<sup>1,3</sup>, and Jing Fang<sup>1,3</sup>

<sup>1</sup>Academy for Advanced Interdisciplinary Studies, Peking University, Beijing, China, People's Republic of; <sup>2</sup>Department of Radiology, Peking University First Hospital, Beijing, China, People's Republic of; <sup>3</sup>College of Engineering, Peking University, Beijing, China, People's Republic of

## Introduction

As the usage of iodinated contrast media (CM) increases, Contrast-induced nephropathy (CIN) has become one of the most prevalent causes of acute renal failure, especially in patients suffering from diabetes or cardiovascular pathology (1, 2). Previous research on CIN has been limited by the methods to monitor renal blood flow (RBF) and partial pressure of oxygen (pO<sub>2</sub>) (3). Accordingly, we aimed to quantify the functional response to iodinated CM injection in rabbits using FAIR-ASL and BOLD MRI. We hope that these MR techniques could be used as a noninvasive tool to study the pathogenesis associated with CIN.

## Materials and Methods

Fifteen healthy rabbits were randomized into iopamidol (n=10) and control (n=5) groups. Experiments were conducted on a 3T GE MR scanner with a commercial QUADKNEE coil. The single shot FSE (SSFSE) with FAIR preparation was adopted for ASL scans, inversion time (TI) of 1400ms (4). The BOLD images for R2\* evaluation were obtained by using a multi-echo SPGR sequence with 12 TEs (5). The baseline FAIR-ASL and BOLD images were obtained before iodinated CM injection. After a 24-hour control period, the rabbits received an intravenous injection of iopamidol-370 with dosage of 6ml/kg body weight or an equivalent amount of 0.9% saline. A serial MR examination was performed at 1 hour, 24 hours, 48 hours and 72 hours following injection to monitor the dynamic response of intra-renal perfusion and oxygenation. RBF maps were quantified by ASL data (the renal cortex: 0-600 ml/100 g/min, the medulla: 0-250 ml/100g/min). R2\* maps were constructed with GE FUNCTOOL, by fitting the signal intensity values to a mono exponential curve. One-way ANOVA and Fisher's LSD test were used to determine the time-dependent changes of RBF and R2\* in different ROIs.

## Results

The ASL images revealed enough spatial information to visually determine tissue contrast between the renal cortex and medulla (Fig.1). Fig 2 shows a representative baseline BOLD image from a rabbit's left kidney. As shown in Fig.4, the cortical RBF was reduced at 1-24 hours after iopamidol-370 administration ( $P=.04$  and  $P=.01$  vs. baseline), and gradually returned to a relatively baseline level within 48-72 hours ( $P=NS$ ). The medullary RBF was prominently reduced at 1-48 hours after administration ( $P=.00$ ,  $P=.00$  and  $P=.01$ ), but retained at a low level until 72 hours ( $P=.05$ ). There was no significant change in either cortical or medullary RBF at each time point in control group. It reveals that iopamidol-370 produces a more RBF reduction in medulla than in cortex, which implies a more vulnerability of the renal medulla to CM-associated ischemia. Within the kidney IS, the mean R2\* was greatly increased at 1 hour after iopamidol-370 administration ( $P=.00$ ), remained higher than baseline at 24 hours ( $P=.05$ ), and gradually recovered to baseline within 48-72 hours after iopamidol-370 administration ( $P=NS$ ) (Fig.5). The iopamidol did not produce statistically significant changes in R2\* in the kidney CO, OS and IM ( $P=NS$ ). In control group, there was no significant change in R2\* in each kidney structure due to saline injection ( $P=NS$ ).

## Discussion and Conclusion

Evaluation of the iodinated CM effects on renal hemodynamics and oxygenation is critical to help us better understand and prevent CIN. By using noninvasive ASL and BOLD MR techniques, our study demonstrated that non-ionic, high-osmolality iopamidol-370 produces a relatively long-term reduction in kidney function. It has further illustrated that iopamidol induces a significant and protracted hypoxic state of the kidney, particularly within the inner stripe of the outer medulla.

In conclusion, with the usage of a noninvasive ASL and BOLD MRI, the present study reveals a time-course decrease in RBF and oxygen level due to iodinated CM. The finding of extreme and prolonged hypoxic state of the kidney, particularly in the inner stripe of the outer medulla, is valuable to understand the pathogenesis of CIN.

## References

- Sharma SK, et al. Catheter Cardio Inte 2005;65:386-393.
- Bouzas-Mosquera A, et al. Rev Esp Cardiol 2007;60:1026-1034.
- Palm F, et al. Acta Radiol 2003;44:347-353.
- Roberts DA, et al. Radiology 1995;196:281-286.
- Prasad PV, et al. J Magn Reson Imaging 2001;13:744-747.

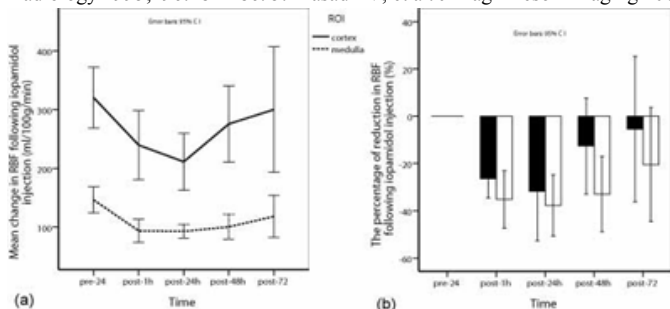


Figure 4: RBF reduction within 72 h following iopamidol administration. The mean cortical RBF decreased by 1 h, reached its minimum by 24 h and gradually returned to baseline by 48 h. a) The medullary RBF decreased to its minimum by 24 h and remained lower than baseline at 72 h; b) Iopamidol produced a greater reduction in RBF within the medulla as compared to the cortex of this kidney (b).

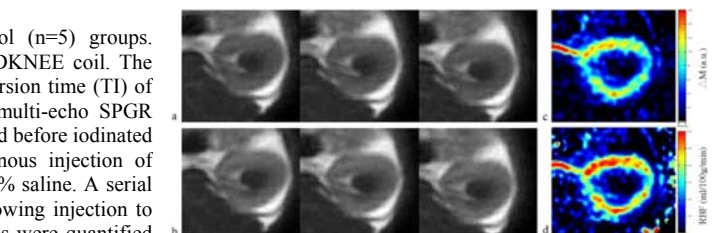


Figure 1: Representative axial ASL images. a) Three raw images with global inversion; (b) corresponding raw images with section-selective inversion; (c)  $\Delta M$  map; (d) RBF map.




Figure 2: Axial multiple-echo SPGR BOLD images. a) The raw image (TE=19ms, 128x128 with 12cm FOV) provides enough spatial resolution to identify CO, OS, IS and IM; (b) TE-dependent signal intensities in four ROIs were fitted by a mono exponential curve; (c) R2\* map; (d) T2\* map.

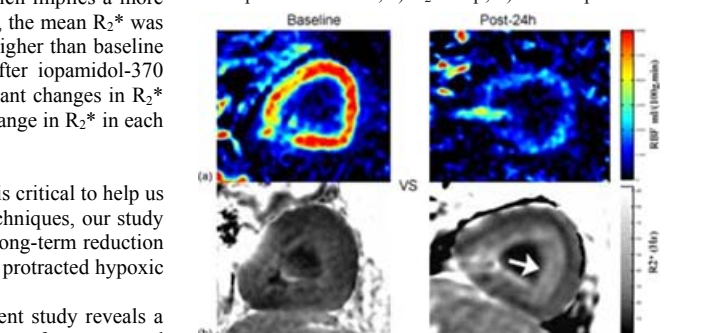


Figure 3: Delayed hypoperfusion and hypoxic state of the kidney induced by iopamidol. Baseline ASL and BOLD imaging shows excellent blood flow and high oxygen level, while post scans at 24 hours revealed RBF was greatly decreased and outer medullary R2\* was greatly increased (arrow).

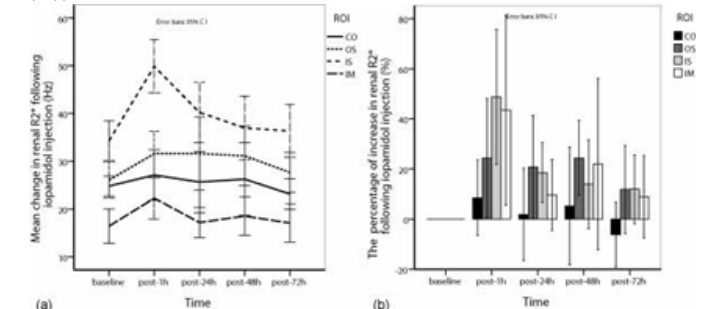


Figure 5: Renal R2\* within 72 h following iopamidol administration. (a) R2\* in the kidney IS increased rapidly to maximum at 1 h ( $P=.00$  vs. baseline), and stayed higher level at 24 h ( $P=.05$ ), while falling to normal within 48-72 h. The R2\* in CO, OS and IM increased slightly ( $P=NS$ ); (b) Iopamidol induced a more great R2\* increase in the kidney IS than the other regions, and the R2\* change in the kidney IM showed a large deviation.