

MR-guided sclerotherapy of vascular and lymphatic malformations: our first year experiences

Paul Allen DiCamillo¹, Wesley D Gilson², Aaron J Flammang², Li Pan², Jonathan S Lewin¹, and Clifford R Weiss³

¹Department of Radiology, The Johns Hopkins University School of Medicine, Baltimore, Maryland, United States, ²Siemens Corporate Research, Baltimore, Maryland, United States, ³Vascular and Interventional Radiology, The Johns Hopkins University School of Medicine, Baltimore, Maryland, United States

Background: Venous malformations (VM) and lymphatic malformations (LM) are congenital lesions that may develop anywhere in the body. Their growth rate and location dictate the age of clinical presentation and chief complaint, which often includes functional or cosmetic impairment, pain or bleeding. These lesions are typically treated percutaneously using ultrasound and fluoroscopic guidance. However, certain lesions cannot be treated using those modalities. These may include lesions that are deep within the body, beneath scars, or located in bone. Additionally, many patients require multiple treatments and are exposed to ionizing radiation each session. Real-time MR-guided intervention serves as a safer alternative, with better visualization of surrounding critical soft tissue structures. We present here our first year of experience with this technique using a short bore 1.5T MRI/X-Ray "Miyabi" suite.

Materials and Methods: 10 female and 4 male patients (8 - 56 years old) with VM or LM previously treated using ultrasound and fluoroscopic guided sclerotherapy were enrolled into this IRB approved study between 9/7/2010 and 9/21/2011. Each was referred for MR guidance for actual or predicted inability to find the lesion using ultrasound. One patient was referred for sclerotherapy of a painful hind gut cyst (HGC). **Intervention:** Imaging was conducted with a MAGNETOM Espree 1.5T MR scanner (Siemens Healthcare, Erlangen, Germany) and an AXIOM Artis dFA (Siemens Healthcare, Forchheim, Germany) "Miyabi" suite. After planning MR (3mm T2 TSE SPAIR), all lesions were punctured under real time MR guidance with Interactive Real-Time TrueFISP imaging (4mm BEAT IRTTT, 465 ms per slice) or Half Fourier Single Shot Turbo SE (4mm HASTE ~ 750 ms per slice) using 20-22 gauge MR-compatible needles (Cook, InVivo, MReye) ranging from 5-20 cm in length. Once access was confirmed by fluid return, VMs were evaluated with a 0.002 mmol/cc gadopentate dimeglumine (gad) injection to assess venous drainage using a dynamic "thick slab" Fast Low Angle Shot (FLASH with subtraction, <2 frames/s). When indicated, patients were transferred to the in-room Artis where a direct injection of ioxilan 350 (Guerbet) was used to confirm MR findings. Patients with VM were treated with anhydrous (100%) ethanol, gad-doped 5% ethanolamine oleate (EO), or gad-doped 3% sodium tetradecyl sulfate (STS). Patients with LMs and HGCs were treated with doxycyclene (10mg/cc). After treatment, confirmatory imaging was conducted (3mm T2 TSE SPAIR or 3mm 3D VIBE).

Results: 23 of 27 targeted lesions were treated as outlined in Table 1. The total procedure time averaged 153 minutes ($\sigma = 69$ minutes), and the intervention time ("skin to skin") averaged 88 minutes ($\sigma = 57$ minutes). In the first 8 sessions, the average needle to target time was 13.1 minutes ($\sigma = 19.6$ minutes) for each attempt, in the last 8 session it improved to 5.1 minutes ($\sigma = 4.8$ minutes): unpaired t-test $p < 0.04$. 13 of 16 sessions were technical successes (the target lesion was accessed). 9 of 14 patients experienced reduced symptoms, with one patient's clinical outcome pending.

Patient #	Age	Gender	Lesion Type	# of Lesions Targeted	Lesion Locations	X-Ray Fluoro Used	Treatment Agent	"Skin to Skin" Time (minutes)	# of Needles Used	Total # of Attempts	Technical Success	Therapeutic Success
1	54	F	VM	1	left breast	no	none	62	1	1	no	n/a
2	20	F	VM	1	right flank	yes	3 cc ethanol	101	2	2	yes	yes - no pain
3	18	F	VM	1	left shoulder	no	none	110	1	1	no	n/a
4	56	M	LM	2	right hip	no	8 cc doxy	137	2	2	yes	yes - reduced pain
5	8	M	LM	2	bladder	no	6 cc doxy	88	2	2	yes	yes - less bleeding
6	22	F	VM	1	left thigh	yes	50.5 cc ethanol	239	6	7	yes	yes - no pain
7	27	M	VM	1	right hip	yes	none	111	4	7	no	n/a
8	48	F	VM	1	left shoulder	no	3 cc ethanol	39	1	4	yes	yes - decreased pain
9	21	M	VM	1	left knee	no	2.5 cc ethanol	115	3	5	yes	yes - decreased pain
10	37	F	VM	1	left foot	no	none	19	3	5	yes**	n/a
11	35	F	HGC	1	posterior sacrum	no	10 cc doxy	24	1	2	yes	yes - decreased pain
12	52	F	VM	1	left triceps	no	2 cc EO	39	1	1	yes	yes - decreased pain
8*	48	F	VM	1	left shoulder	no	2.5 cc EO	49	2	2	yes	yes - no pain
13	40	F	VM	4	intra-abdominal	no	28 cc STS	122	4	4	yes	pending
14	23	F	VM	1	left thigh	no	1 cc STS	25	1	1	yes	yes - decreased pain
13*	40	F	VM	7	intra-abdominal	no	32 cc STS & 6cc ethanol	123	7	8	yes	pending

Table 1: Summary of data on 16 interventions on 14 patients. 2LM, 1 HGC and 20 VM lesions were treated. (*) = results from that patient's second session. (**) = lesion was reached with needle, but was not treated due to its high blood flow.

Discussion and Conclusions: VMs and LMs can be safely and effectively accessed and treated using a short bore 1.5 T MR system, and needle to target times have significantly improved. The MR/angiographic hybrid system provides an additional margin of safety when administering a highly caustic and effective therapeutic (100% ETOH). The faster refresh rate of TrueFISP imaging remains an advantage over HASTE, although the T2/T1 signal characteristics make the visualization of some lesions difficult. We are currently optimizing additional real-time MR pulse sequences (such as HASTE and FLASH) to improve the visualization during lesion targeting and during assessment of lesional blood flow. We are also currently evaluating targeting software to further reduce procedure time.

References:

Fayad L, Hazirolan T, Bluemke D, Mitchell S. *Skeletal Radiol* 2006 Mar; 35: 127-137.
Legiehn GM, Heran MK. *Radiol Clin North Am*. 2008 May; 46(3):545-97.
Lewin JS, Merkle EM et al. *Radiology*. 1999 May; 211(2):566-70.
van der Linden E, Pattynama PM, et al. *Radiology*. 2009 Jun; 251(3):926-32.

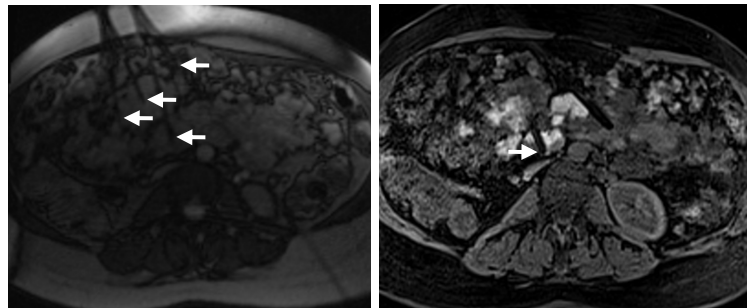


Figure 1: Axial abdominal MR views from 40 yo F with Klippel-Trénaunay-Weber syndrome, untreatable with ultrasound alone. **Left:** real-time BEAT IRTTT guiding multiple needles (arrows) targeting several deep-seated lesions. **Right:** a 15 cm needle (arrow) treating a VM residing adjacent to vena cava and other critical structures. Other treatment needles can be seen in this 3D VIBE. The bright areas highlight where STS/gad treatments have been injected.