

Differentiation of Low- and High-Grade Pediatric Brain Tumors Using High b-Value Diffusion Imaging with A Fractional Order Calculus Model

Y. Sui^{1,2}, H. Wang³, GZ Liu¹, F. W. Damen¹, C. Wanamaker⁴, YH Li⁵, and X. J. Zhou^{1,6}

¹Center for MR Research, University of Illinois Medical Center, Chicago, IL, United States, ²Bioengineering, University of Illinois at Chicago, Chicago, IL, United States, ³Applied Science Lab, GE Healthcare, Shanghai, China, ⁴Radiology, University of Illinois Medical Center, Chicago, IL, ⁵Radiology, Xinhua Hospital, Shanghai, China, ⁶Departments of Radiology, Neurosurgery and Bioengineering, University of Illinois Medical Center, Chicago, IL

Introduction: Over the past few years, diffusion MRI has been increasingly used for brain tumor diagnosis and treatment evaluations [1, 2]. The vast majority of brain tumor applications employed a single b -value (in addition to $b \approx 0$) to yield apparent diffusion coefficient (ADC) and/or fractional anisotropy using a mono-exponential model. This simple model assumes a uniform diffusion process for any given voxel, which is rarely the case for heterogeneous tumor tissues. As such, the mono-exponential model can disguise information such as tissue heterogeneity and microenvironment, which are valuable for differential diagnosis, tumor characterization, as well as treatment guidance and monitoring [1, 3]. Over the past decade, a number of non-monoexponential models have been proposed, such as bi-exponential [4], stretch-exponential [5], statistical [6], q-space [7], kurtosis [8], fractional order calculus (FROC) [9], and other models. In this study, we investigate the feasibility of using a set of new parameters from the FROC model to differentiate low-grade from high-grade pediatric brain tumors.

Methods: The study was performed on 16 boys (age, 4 months to 13 years) and 11 girls (age, 4 months to 7 years) with histopathologically proven brain tumors. According to the latest WHO classification [10], 12 patients had low-grade astrocytic tumors (5 grade I and 7 grade II), and the remaining 15 patients had high-grade tumors (9 embryonal tumors, 2 pineoblastoma, 2 glioblastoma multiforme, 1 anaplastic astrocytoma and 1 ependyoblastoma). With the approval of the institutional review board and the written informed consent, MR examinations were performed on a 3T GE Signa scanner with an 8-channel head coil. The imaging protocol included FLAIR, T2, contrast-enhanced T1 (T1+C), and multi- b -value diffusion-weighted imaging (DWI) sequences. Diffusion-weighted images were acquired with a single-shot spin-echo echo-planar imaging (EPI) sequence using 12 b -values from 0 to 4000 sec/mm^2 . At each non-zero b -value, a Stejskal-Tanner diffusion gradient was applied along the x-, y-, and z- axis, respectively, to obtain trace-weighted images. The key data acquisition parameters were TR/TE = 4700/100 ms, slice thickness = 5 mm, Δ = 38.6 ms, δ = 32.2 ms, average = 1, FOV = 22 cm \times 22 cm and matrix size = 128 \times 128 (zero padded to 256 \times 256 for image reconstruction). The FROC diffusion model was used to fit the multi- b -value diffusion images on a pixel-by-pixel basis using the following equation: $S/S_0 = \exp\{-D\mu^{2(\beta-1)}(\gamma G_a \delta)^{2\beta}[\Delta - (2\beta-1)\delta/(2\beta+1)]\}$, where the spatial fractional order β is correlated to the degree of tissue heterogeneity [5, 9], and the spatial quantity μ (in units of μm) is related to the mean free length [9]. In this model the initial value of D was estimated by a mono-exponential model using data acquired at b -values $\leq 1000 \text{ sec}/\text{mm}^2$, allowing a direct comparison with the conventional ADC value. All image processing and analysis were performed using customized software developed in Matlab (Mathworks Inc, MA). The tumor ROIs were selected by an experienced neuro-radiologist, guided by T1+C, T2, and FLAIR images. Areas of necrosis, cyst, hemorrhage, edema and calcification were avoided. Mean values and standard deviations of D , β and μ were calculated from the tumor ROIs for each patient. Based on these values, the low-grade and high-grade tumor groups were compared using Mann-Whitney U test with a statistical significance set at $p < 0.05$. The performance of each parameter for differentiating the patient groups was evaluated using areas under the curves (AUC) of receiver operating characteristic (ROC) analysis. All statistics was conducted using SPSS (SPSS Inc, Chicago, IL).

Results: Figure 1 shows maps of D (a, b), β (c, d) and μ (e, f) from one representative patient in each of the two groups (left column: low-grade; right column: high-grade). The D , β and μ values for each group are summarized in Table 1. All parameters exhibited a significant difference between low-grade and high-grade tumors ($p < 0.02$). Figure 2 shows the scatter plots between D and β (Fig. 2a) and between D and μ (Fig. 2b). D and β both clearly differentiated the two patient groups. In addition, D and μ showed a strong correlation ($R = 0.87$, $p < 0.01$) as expected. Figure 3 illustrates the ROC curves, in which AUC for D , β , μ were 0.96, 1.0 and 0.86, respectively, indicating β is the best marker for differentiation between the low-grade and high-grade pediatric brain tumors.

Discussion and Conclusion: Our results demonstrate that there is a significant difference in FROC parameters between the low-grade and high-grade pediatric brain tumors. Compared with ADC, the new parameter β , which has been shown to reveal the difference in tissue heterogeneity [5, 9], exhibits better performance in differentiating the two groups. In Fig. 2a, two clusters appeared in the low-grade group, each corresponding to a different tumor grade (I or II). This finding indicates that individual or combined parameters from the FROC diffusion model may also be useful for tumor staging or even characterizing the sub-types of low- or high-grade pediatric brain tumors.

References: [1] Maier, et al., NMR Biomed, 2010. [2] Ross, et al., Mol Cancer Ther, 2003. [3] Rumboldt, et al., AJNR Am J Neuroradiol, 2006. [4] Niendorf, et al., Magn Reson Med, 1996. [5] Bennett, et al., Magn Reson Med, 2003. [6] Yablonskiy, et al., Magn Reson Med, 2003. [7] Assaf, et al., Magn Reson Med, 2000. [8] Jensen, et al., Magn Reson Med, 2005. [9] Zhou, et al., Magn Reson Med, 2010. [10] Louis, et al., Acta Neuropathol, 2007.

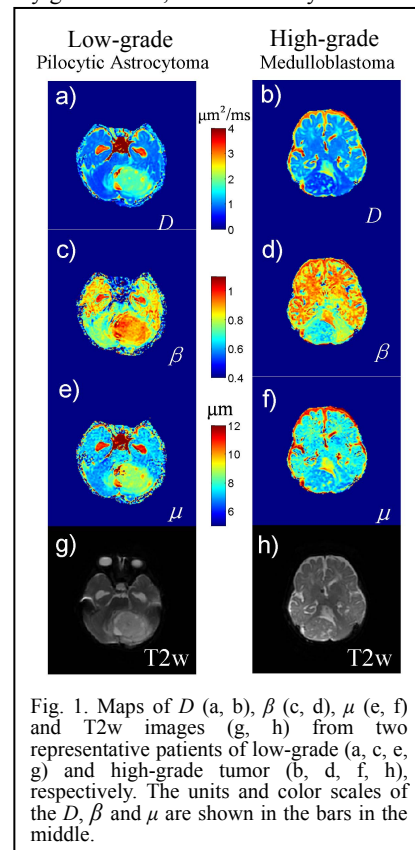


Fig. 1. Maps of D (a, b), β (c, d), μ (e, f) and T2w images (g, h) from two representative patients of low-grade (a, c, e, g) and high-grade tumor (b, d, f, h), respectively. The units and color scales of the D , β and μ are shown in the bars in the middle.

	D ($\mu\text{m}^2/\text{ms}$)	β	μ (μm)
Low-grade	1.53 ± 0.39	0.90 ± 0.03	8.48 ± 0.72
High-grade	0.83 ± 0.19	0.71 ± 0.06	7.52 ± 0.48

Table 1. FROC diffusion parameters of low-grade and high-grade pediatric brain tumors. All parameters show significant difference between the two groups ($p < 0.02$)

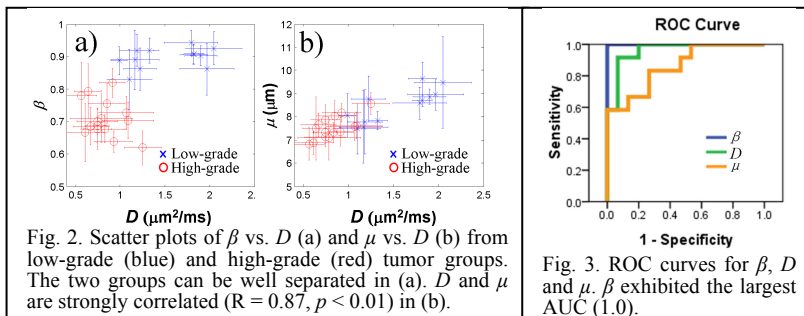


Fig. 2. Scatter plots of β vs. D (a) and μ vs. D (b) from low-grade (blue) and high-grade (red) tumor groups. The two groups can be well separated in (a). D and μ are strongly correlated ($R = 0.87$, $p < 0.01$) in (b).

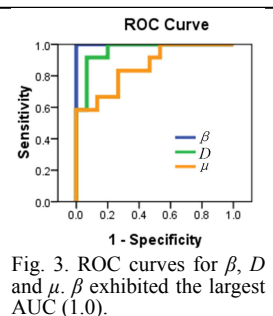


Fig. 3. ROC curves for β , D and μ . β exhibited the largest AUC (1.0).