

## Combined Dual Frequency 19F and 1H MRI in the human digestive tract

Tobias Hahn<sup>1</sup>, Ruben Pellicer Guridi<sup>1,2</sup>, Werner Schwizer<sup>3</sup>, Sebastian Kozerke<sup>1</sup>, Michael Fried<sup>3</sup>, Peter Boesiger<sup>1</sup>, and Andreas Steingöetter<sup>1,3</sup>

<sup>1</sup>Institute for Biomedical Engineering, University and ETH Zurich, Zurich, Switzerland, <sup>2</sup>Department of Biophysics and Bioengineering, University of Barcelona, Barcelona, Spain, <sup>3</sup>Dep. of Internal Medicine, Division of Gastroenterology and Hepatology, Zurich, Switzerland

**Introduction:** Recently, methods have been proposed for the interleaved imaging and tracking of exogenously introduced markers with different resonance frequencies [1-3]. It has been shown that those methods can be of high value for site targeted drug delivery and physioanatomic studies in the intestinal tract [1-4]. Given a relatively large spectral separation of the imaging agents and a low enough excitation bandwidth, independent “multi-frequency” tracking of different imaging agents is possible. In this study, the *in vivo* 3D tracking of two capsules labeled with 19F containing compounds of 80 ppm spectral distance is demonstrated.

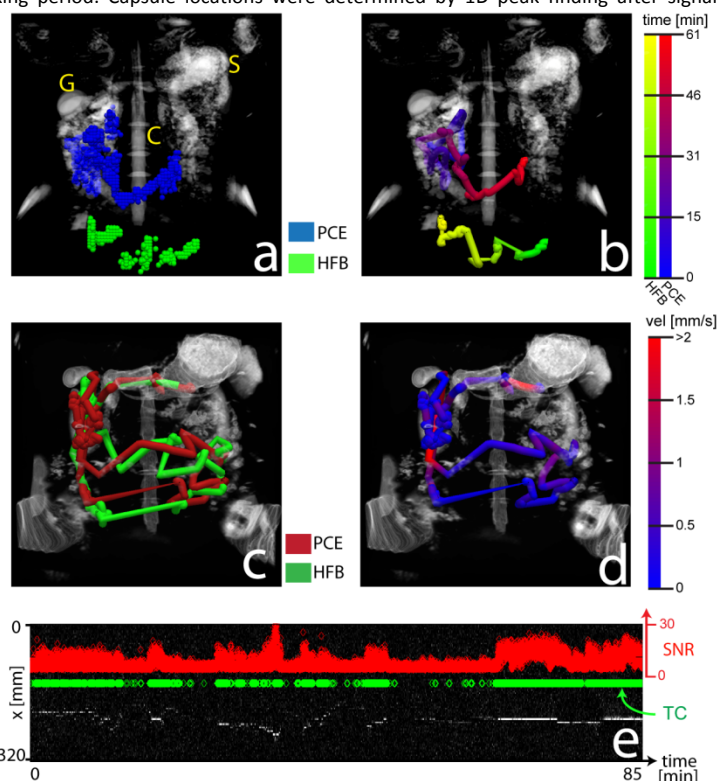
**Methods and Materials: In vivo data acquisition:** All experiments were performed on a 3T whole-body Achieva MR system (Philips Healthcare, Best, The Netherlands). A dual-channel 19F transmit-receive surface coil (PulseTeq Ltd, UK, 20cm diameter) in Quadrature mode was used for 19F imaging. A modified dynamic balanced FFE sequence [3] was used for 19F tracking of the *in vivo* coordinates of ingested fluorine agent filled capsules. Administered insoluble capsules were slightly modified from [3] and filled with 65  $\mu$ l of either Perfluoro-[15]-crown-5-ether (PCE) or Hexafluorobenzene (HFB). Scan parameters were: FOV 32x32x32 cm<sup>3</sup>, TR/TE (ms) 4.2/1.78, spatial resolution (4 mm)<sup>3</sup>, sinc Gaussian pulse with 2735 Hz bandwidth, flip angle 39°. Each dynamic scan consisted of 10 projections in x-, y- and z-direction, respectively. Interleaved PCE and HFB tracking was performed in 5 subjects on two different study days each and with a temporal resolution of 254 ms for each compound. 1H surveys were acquired in between 19F tracking periods for registration, and high-resolution T2 weighted anatomic abdominal scans were acquired before and after tracking for anatomic referencing. **Data analysis:** Using MATLAB, tracking data was automatically coregistered by cross-correlation of the corresponding 1H survey scans acquired immediately before or after each tracking period. Capsule locations were determined by 1D peak finding after signal averaging of 10 k-space profiles for each projection direction. Computed 3D coordinate data was filtered by incorporating acceptance criteria based on SNR and capsule velocity. The intestinal 3D geometry was reconstructed by local regression and polynomial fitting of the trusted capsule coordinates. Anatomic and parametric data was visualized using VTK (Fig. a-d). The spatial variance of the absolute capsule velocity was computed using moving average filtered and breathing compensated capsule coordinates. Filter size was 10s. Intestinal 3D geometry was compared between the PCE and HFB capsules.

**Results:** Reliable interleaved tracking of 2 differently 19F labeled capsules with a temporal resolution of 254 ms in the human intestines was successfully performed. Using the proposed RF pulse, no signal smearing between the PCE and HFB signal was detected that would lead to a non-unique assignment of the different capsule coordinates (Fig.a). Although having been administered at the same time, the two capsules did not always pass through the intestinal tract synchronously (Fig.b). The reconstructed intestinal geometries based on the PCE and the HFB capsule trajectory, respectively, showed a good conformity (Fig.c). As expected, intestinal passage did not occur with a constant mean velocity, but showed a high spatio-temporal dependence; strong local motor activity could be found in the stomach and the right lateral small intestinal loops in one volunteer (Fig.d). Peak SNR of the 1D projections after averaging 10 k-space profiles for each direction was 31 in volunteer 2 (Fig. e).

**Discussion and Conclusion:** This study shows the feasibility of fast unambiguous *in vivo* 3D tracking of small 19F labeled capsules in the human digestive tract. Using the described method, local analysis of functional parameters such as local velocity is possible, as well as global anatomic analysis of intestinal 3D geometry. Both coil design and shimming have to be optimized in order to receive high SNR in the whole abdominal area and consequently reduce interpolation induced errors. For interleaved HFB and PCE excitation, higher than 3kHz bandwidth excitation pulses for overcoming shimming deficiencies are not advised, since such pulses might lead to unwanted signal smearing. Relative freedom with regard to pulse selection is given for single frequency multiple 19F marker tracking, as proposed in [5].

### References:

[1] Partlow et al. FASEB 2007 [2] Caruthers et al. Springer 2006 [3] Hahn et al. MRM 2011 [4] Jiang et al. Chem. Commun., 2011, 47, 7233–7235 [5] Hahn et al. Proc. ISMRM 19 (2011)



**Figure (a)** Dual 19F capsule 3D tracking in volunteer 1. Tracking was performed over 61 min. Gall bladder (G), stomach (S) and spinal cord (C) are denoted in the figure. **(b)** Reconstructed intestines geometry for volunteer 1. The passage of the capsules over time is visualized with 2 different colorbars. **(c)** Reconstructed intestinal tubes of volunteer 2 for HFB and PCE. Tracking was performed over 85 min. **(d)** PCE velocity colored intestinal trajectory in volunteer 2. **(e)** Exemplary 1D PCE projection in x-direction in volunteer 2. SNR over time is shown in orange and the coordinates fulfilling the acceptance criteria (TC) are shown in green.