

Age-related Iron Deposition in Deep Gray Nuclei in Infants Detected by 1.5T MRI: R2* versus Susceptibility Phase Values

Ning Ning¹, Lei Zhang^{1,2}, Yumiao Zhang¹, Zhuanqin Ren², Ed.X Wu³, and Jian Yang¹

¹Department of radiology, the first affiliated hospital of medical college, Xi'an Jiaotong University, Xi'an, Shaanxi, China, People's Republic of; ²Department of magnetic resonance imaging, Baoji central hospital, Baoji, Shaanxi, China, People's Republic of; ³Laboratory of Biomedical Imaging and Signal Processing, The University of Hong Kong, Hong Kong SAR, China, People's Republic of

Introduction

Iron plays an important role in normal brain metabolism. It is essential to many developmental and functional processes in the brain due to the high energy demand to support neuronal activity [1]. Estimating the amount of iron deposition in the brain may provide a new biomarker for assessing the presence and progression of a variety of neural diseases not only in adults but also in infants. Therefore, it is potentially important to quantify the iron content in infant brains in vivo. Susceptibility weighted imaging is a high resolution 3D gradient-echo MRI technique. It probes the tissue paramagnetic properties such as iron content by post-processing phase information [2], giving a negative phase shift, T2* decrease or R2* ($R2^*=1/T2^*$) increase relative to the surrounding parenchyma [3]. The purpose of this study is to measure the R2* and phase values of the deep gray nuclei in infants, examine the correlation of the two values with iron deposition, and evaluate R2* and phase image as an in vivo approach to study of early brain development by susceptibility weighted imaging.

Methods

56 infants with no abnormalities in brain MR images were enrolled in this study and examined with informed consent from parents according to local ethics procedures. Their postmenstrual age (PMA) ranged from 37 to 91 weeks with mean of 54 weeks. All images were obtained using a 1.5T MR system (GE HDX). Sagittal T2-weighted images were first acquired with a fast spin-echo sequence to locate the anterior and posterior commissures. A 3D gradient-echo sequence (ESWAN of enhanced T2* weighted angiography) was employed with image slices parallel to the anterior-posterior commissural line (AC-PC line). Imaging parameters were TR=54 ms, number of echoes=8, TE=5-43 ms, FA=25°, slice/gap=3 mm/0 mm, NEX=0.75, FOV=24×24cm², matrix=256×256, total scan time=225s. The phases of the last five echoes were high-pass filtered to remove background inhomogeneity and then averaged to get a final phase image with an effective TE of 32 ms. The R2* image was fitted from magnitude values of all the eight echoes. For image analysis, regions of interest (ROIs) were outlined manually in caudate nucleus (CN), putamen (PUT), globus pallidus (GP), thalamus (THA), red nucleus (RN) and substantia nigra (SN) based on neuroanatomical atlas. Same ROIs were used to analyze phase and R2* images. R2* and phase values in the above gray matter nuclei were calculated and correlated with the reference iron concentrations. Note the these reference values of iron concentrations in various nuclei were estimated from PMA using an empirical equation that was derived in an earlier postmortem study [4]. The Pearson correlation analysis was performed. Statistical differences with P<0.05 were considered significant.

Results

R2* values of various deep gray nuclei exhibited statistically significant and positive correlations with PMA (Fig. 1a). In particular, strong positive correlations were found in CN and THA with correlation coefficient of 0.751 and 0.753 (p<0.001), respectively. In contrast, no significant linear correlation was observed between phase value and PMA in each structure (P>0.05) (Fig. 1b). Pearson correlation analysis showed a strongly positive correlation between the R2* values and the reference values of the iron concentrations, yielding r=0.751, 0.664 and 0.673 for CN, PUT and GP, respectively, with P<0.001. As for phase value, no correlation with reference values of the iron concentrations were found (P>0.05) (Fig. 1c).

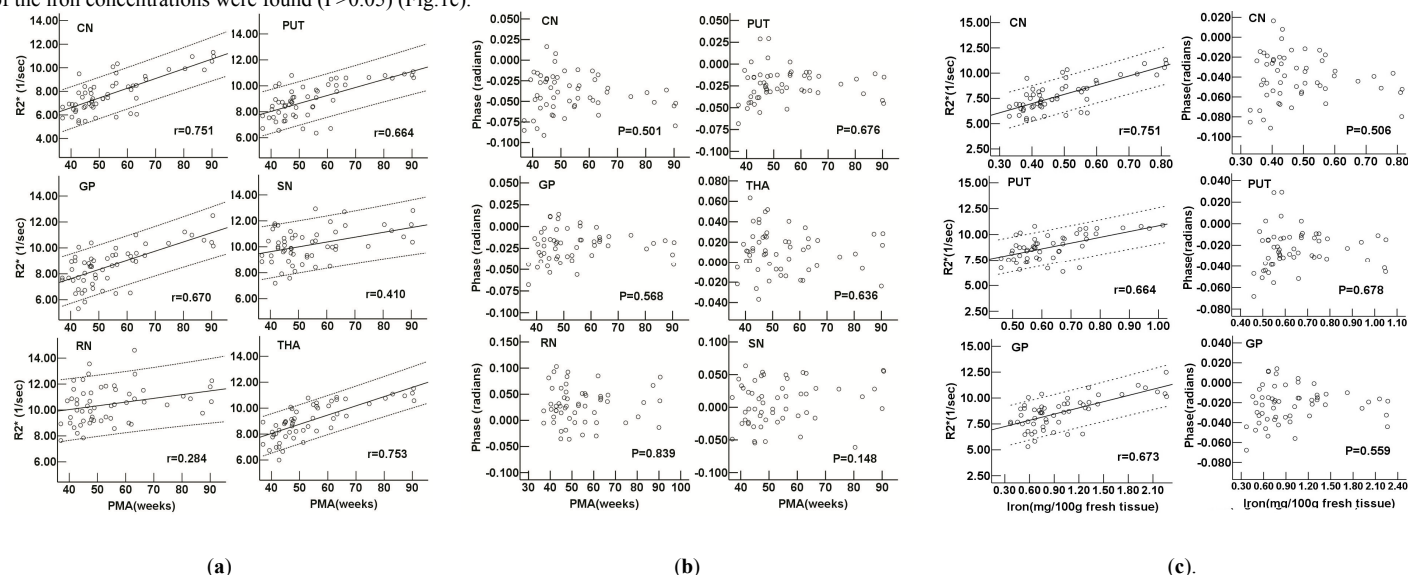


Figure 1 (a) Regional R2* value vs. PMA ; (b) Regional phase value vs. PMA; and (c) R2* and phase values vs. iron concentration. Solid lines are the linear regression. Dashed lines indicate the 95% confidence intervals for the regression. r is the coefficient of correlation. P values of the linear regression in different regions are shown.

Discussion and Conclusion

In brain, non-heme iron that presents sufficient concentration to affect MR contrast resides in ferritin or hemosiderin molecules [5], leading to R2* increase. We demonstrated that R2* values in deep gray nuclei had a significant and positive correlation with PMA, indicating a steady and rapid accumulation of elements of magnetic susceptibility in these structures during the early brain development in infants. We also found a strongly positive correlation between the R2* value and the reference values of the brain iron concentrations. These findings indicated that the changes of R2* values likely reflect the iron deposition increase with age in infant brains. Note that similar phenomenon has been reported in the brains of children and adults [6, 7]. On the other hand, we did not find any correlation between the phase value and the brain iron concentrations, and there was no linear change by age. Note that several studies have reported that the phase value could reflect the increase of brain iron deposition in gray and white matter with age in adults [7, 8]. However, brain iron deposition is low in infants, especially in newborns. In addition, phase values can be easily influenced by the flowing or moving spins in venules in deep gray matter, field inhomogeneities caused by air-tissue interfaces, and the ratio of oxy- and deoxyhemoglobin [8]. All together, the results from the present study demonstrated that R2* is a more sensitive parameter than phase value for in vivo estimation of brain iron deposition during the first year of life.

Acknowledgements: The authors would like to thank Drs. He Wang, Hao Shen, and Guang Cao from Applied Science Lab, GE Healthcare for their technical assistance. This study was supported by a grant from National Natural Science Foundation of China (No. 30970797 to JY).

References: 1.Morris CM. Brain;134 (2011). 2.Haacke EM, et al. Magn Reson Med;52 (2004). 3.Abduljalil AM , et al. J Magn Reson Imaging;18 (2003). 4.Hallgren B, et al. J Neurochem;3 (1958). 5.Schenck JF. J Neurol Sci;207 (2003). 6.Aquino D, et al. Radiology;252 (2009). 7.Haacke EM, et al. J Magn Reson Imaging;32 (2010). 8.Pfefferbaum A, et al. Neuroimage;47 (2009).