

Ultrashort TE-enhanced T₂* mapping of deep articular cartilage detects sub-clinical degeneration

Ashley Williams¹, Yongxian Qian², and Constance R Chu¹

¹Cartilage Restoration Center, University of Pittsburgh, Pittsburgh, PA, United States, ²Magnetic Resonance Research Center, University of Pittsburgh

Introduction Detecting changes to deep articular cartilage integrity is important to the early identification of matrix deterioration resulting from traumatic or chronic increased tissue stresses. Ultrashort TE (UTE) imaging is sensitive to short transverse relaxations (T₂ <10ms) that are found in deep articular cartilage^{1,2} and has the potential to provide prognostic indication of otherwise clinically occult osteoarthritis (OA). UTE-enhanced T₂* (UTE-T₂*) mapping has been shown to reflect collagen structural integrity in cartilage and meniscus^{3,4} and to provide reproducible *in vivo* measures of cartilage and meniscus status clinically⁵. This clinical study examines UTE-T₂* values cross-sectionally and longitudinally to assess the diagnostic potential of clinical UTE-T₂* mapping to detect degenerative changes in articular cartilage following joint injury and to monitor cartilage status over 12 months following ACL reconstruction surgery.

Methods Fifty-three human subjects are included. Forty-two subjects undergoing arthroscopy for meniscectomy and/or ACL reconstruction (mean age = 37 ± 13 yrs; mean BMI = 28 ± 6) and 11 asymptomatic subjects with no known or suspected knee pathology (mean age = 28 ± 4yrs; mean BMI = 25 ± 4) provided informed consent and participated in these IRB-approved studies. Asymptomatic controls did not undergo arthroscopy. 3-D AWSOS (acquisition-weighted stack of spirals)⁶ images were acquired on all subjects using a 3T Siemens MAGNETOM Trio scanner and an 8-channel knee coil (In vivo Inc.). Eleven echo images, TE ranging 0.6-40ms were collected with 140mm FOV and 256 matrix for 547μm resolution in-plane and 2mm section thickness. Other acquisition parameters were: 60 slices, 24 in-plane spirals, 11.52ms spiral readout time, 5μs data sampling interval, and FA/TR 30/80ms. Scantime was 1.92min per TE-image. TE images were interpolated to a 512 matrix prior to T₂-curve fitting. UTE-T₂* maps were generated with a mono-exponential pixel-by-pixel T₂-fit routine using MRIMapper software (© Beth Israel Deaconess and MIT 2006). Regions of interest (ROIs) were manually segmented from a single section from each knee to separately evaluate the superficial and deep portions of the cartilage thickness in the central and posterior medial femoral condyle cartilage (cMFC, pMFC). During surgery, targeted arthroscopic exams were conducted on the area of the central and posterior weight-bearing zones of the medial femoral condyle. Arthroscopic grades were assigned by the surgeon using a modified Outerbridge scale (0-normal 'firm'; 1-softening; 2- partial thickness defect, superficial fissures; 3-fissuring to subchondral bone; 4-exposed subchondral bone). Eight subjects undergoing ACL reconstruction returned for follow-up UTE-T₂* mapping 12 months after surgery. Non-parametric statistics were used to assess UTE-T₂* differences across groups of subjects with different degrees of pathology; post-hoc tests adjusted for multiple comparisons evaluated pairwise differences. Paired t-tests assessed longitudinal changes in UTE-T₂* values of subjects returning for follow-up MRI. Statistical analyses were performed with IBM SPSS and Microsoft Excel.

Results UTE-T₂* values from the deep layer of articular cartilage of the cMFC vary significantly with disease status (Kruskal-Wallis, P=0.002, Figure 1). Pairwise comparisons indicate that deep cMFC UTE-T₂* values in asymptomatic subjects (n=11, mean ± SD 9.9 ± 2.3ms) are significantly shorter than deep UTE-T₂* values of ACL and/or meniscus-injured subjects with cartilage graded 'firm' by the surgeon (scope 0; n= 17, mean ± SD 15.2 ± 7.4ms; Mann-Whitney P=0.01). Deep cMFC cartilage graded 'softened' while retaining an intact articular surface (scope 1; n=12, mean ± SD 17.8 ± 6.6ms) had significantly longer UTE-T₂* values than the deep cartilage whose articular surface demonstrated fibrillations (scope 2; n=8; mean ± SD 9.6 ± 3.7ms; Mann-Whitney P=0.02). UTE-T₂* values of superficial cMFC cartilage demonstrate a non-significant trend for variation with arthroscopic grade (Kruskal Wallis P=0.06). Neither superficial nor deep UTE-T₂* values of pMFC cartilage were found to vary with arthroscopic grade. Among the subset of ACL-injured subjects who returned for follow-up UTE-T₂* mapping 12 months after ligament reconstruction surgery and whose articular surfaces remained intact at 12 months post-surgery (n=5), UTE-T₂* values in deep cMFC and deep pMFC cartilage decreased 25% (paired t-tests P=0.03, P=0.04) to become comparable to that of asymptomatics (10.0 ± 3.0 ms for ACLT subjects at follow-up vs 9.9 ± 2.3ms for asymptomatics). Superficial UTE-T₂* values did not change significantly in either cMFC or pMFC cartilage (paired t-tests P>0.29) over 12 months following surgery.

Figure 1

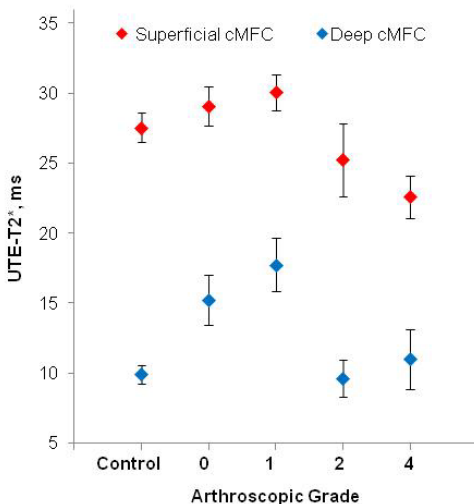
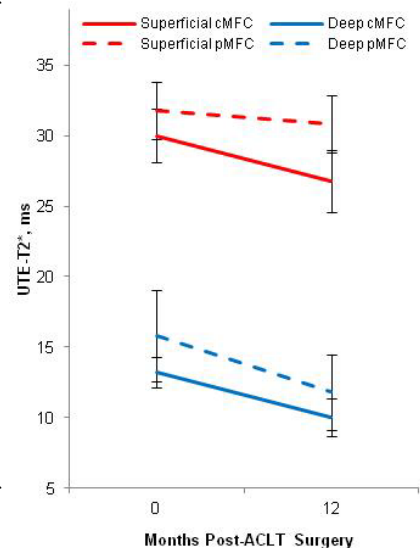


Figure 1 (Left) – UTE-T₂* is sensitive to subclinical cartilage matrix alterations in subjects at risk of developing OA, and therefore may provide prognostic indication of clinically occult OA in deep cartilage tissue. UTE-T₂* in deep cMFC cartilage (blue) of 53 human subjects varies with degree of joint pathology, P=0.002. Asymptomatics (controls) have significantly lower deep cMFC UTE-T₂* values than patient subjects with arthroscopically firm and intact cartilage (grade 0), P=0.01. Superficial cMFC UTE-T₂* values (red) show a trend for varying with degree of disease, P=0.06. Error bars are ± SEM.

Figure 2 (Right) –Longitudinal evaluation of cartilage UTE-T₂* values in subjects with ACL tear shows signs of deep cartilage healing over 12 months following reconstruction. Subjects whose articular surfaces remained intact in the 12 months following surgery demonstrated significant UTE-T₂* decreases in deep cMFC and pMFC cartilage (P=0.03, 0.04, respectively). At 12 months, deep MFC UTE-T₂* values in this cohort were similar to those seen in deep MFC cartilage of asymptomatic control subjects. Error bars are ± SEM.

Figure 2



Conclusion Significant elevations of UTE-T₂* values in deep femoral condylar cartilage of subjects with ACL and/or meniscal injury without clinical evidence of subsurface cartilage abnormality suggest that UTE-T₂* mapping is sensitive to sub-clinical cartilage degeneration in knees known to be at risk for developing OA. Significant decreases in UTE-T₂* values measured longitudinally over 12 months following ligament reconstruction surgery further suggest that UTE-T₂* can be used to quantitatively monitor changes to cartilage status in response to therapeutic interventions. Additional study is needed to determine whether elevated deep cartilage UTE-T₂* values, particularly in the absence of arthroscopically evident abnormality, predict progression of cartilage degeneration and development of OA.

References [1] Du, *Magn Reson Imaging*, 29(4):470-82, 2011. [2] Du, *J Magn Reson Imaging*, 63:447-455, 2010. [3] Williams, *OACart*, 18(4):539-46, 2010. [4] Williams, *ISMRM*, #562, May 7-13, 2011; Montreal, CA. [5] William *OACart*, 19(1):84-8, 2011. [6] Qian, *Magn Reson Med*, 60(1):135-45, 2008. **Acknowledgments** Funding support provided by the NIH (RO1 AR052784 (CR Chu)).