

Characterisation of a novel orthotopic mouse model of multiple myeloma and therapeutic response by quantitative MRI

Timothy J Graham¹, Rosemary A Fryer², Yann Jamin¹, Emma M Smith², Simon Walker-Samuel³, Faith E Davies², and Simon P Robinson¹

¹Cancer Research UK & EPSRC Cancer Imaging Centre, The Institute of Cancer Research, London, Surrey, United Kingdom, ²Haemato-Oncology Research Unit, Division of Molecular Pathology, The Institute of Cancer Research, London, Surrey, United Kingdom, ³Centre for Advanced Biomedical Imaging, University College London, London, United Kingdom

Introduction. Bone marrow (BM) provides the primary niche supporting the growth and proliferation of tumour cells in the plasma cell malignancy multiple myeloma (MM). Around 90% of MM patients experience bone pathology, causing significant morbidity and mortality [1]. Given that the BM environment facilitates therapeutic resistance, it is important to use orthotopic models, with associated tumour/host stromal interactions, to test whether novel therapeutic agents can overcome this protection [2]. There is a paucity of non-invasive MRI strategies used to interrogate disease progression and response in malignant bone disease models. In this study we investigated a) the effectiveness of MRI methods to non-invasively quantify disease and assess the therapeutic response, and b) the sensitivity of diffusion weighted imaging (DWI) as an early biomarker of treatment response compared to standard morphological imaging, in a novel intratibial MM model.

Materials and Methods. *Animals and Tumours:* NOD scid γ mice were injected with 2×10^6 luciferase transfected U266 myeloma cells (U266-luc) through the proximal end of the tibia. Saline injected mice were used as negative controls. *Drug Administration:* The proteasome inhibitor bortezomib (BZB), and the aminopeptidase inhibitor tosedostat (TSD), were administered at week 5 for 4 weeks, at 1 mg/kg i.p. twice per week and, at 75mg/kg i.p. for 6 days out of 7, respectively. A positive control group remained untreated. *Longitudinal measures:* Weekly blood samples were taken, commencing 4 weeks after injection of cells, to determine levels of human Ig λ in blood sera. Bioluminescence imaging (carried out at week 4 and week 9) confirmed tumour development and progression. *MRI Analysis:* At week 9, MRI studies were carried out on a Bruker 7T horizontal bore pre-clinical system. Mice were anaesthetised, restrained and positioned supine within a 3cm birdcage ^1H coil. To determine tumour progression, T_2 -weighted TurboRARE coronal images were acquired across both legs, using a slice thickness of 0.3mm from a 100×100 matrix over a 30×30 mm field of view (FOV), using an echo time (T_E) of 24.6ms and repetition time (T_R) of 6000ms and 16 averages, giving a total acquisition time (AQ) of ~14 minutes. Tumour was identified as a hyperintense signal enclosed within the cortical bone, on which ROIs were drawn on the periphery and tumour burden quantified in OsiriX, and followed through each slice for each tibia and femur within both legs. In a second cohort, diffusion weighted images (DWI) were acquired prior to and 48 hours after treatment with BZB, using a home-built single leg RF coil. EPI-DW images were acquired from ten 1mm thick axial tumour bearing slices, using $T_E=32\text{ms}$, $T_R=3000\text{ms}$, FOV 20×20 mm, matrix 128×128 , 4 averages, b values of 40, 100, 500, 700 and 1200, giving AQ ~4min. Data were fitted on a voxel-by-voxel basis using in-house software, providing maps of tumour spatial heterogeneity of ADC. *Imaging Validation:* Bone and soft tissue samples were stained with anti-CD138-APC antibody, then analyzed using flow cytometry (FCM). Sections of decalcified bones (tibia and femur) were stained with haematoxylin and eosin (H&E), and immunohistochemically processed using anti-CD138 antibodies.

Results. *Model Characterisation:* MRI revealed successful tumour propagation and considerable progression across, and restricted to, the entire skeleton, confirmed by FCM. In order to validate the imaging-derived volume measurement as a marker of disease extent, mid and end point T_2 -weighted images were acquired (n=3) for comparison with the Ig λ levels. Average MRI-derived tumour volumes showed a strong association with Ig λ levels in the serum. In order to investigate the reproducibility of the tumour volume determination, a single mouse underwent three T_2 -weighted imaging scans on three consecutive days. Volumes of 24.7, 23.7 and 26.1 (mm^3) were calculated, giving a CoV of 4.9%. *Therapeutic Response:* Representative images of femur and tibia from positive control, BZB and TSD treated mice are shown in Figure 1A. Both treatments caused a highly significant decrease in intra-bone signal. Moreover, the BZB group was not significantly different to the negative control group. Serial measures of Ig λ in blood sera (Figure 1B), CD138+ human myeloma cell counts by FCM, and histological staining (Figure 1C) confirmed the quantitative MRI response data. Paired diffusion weighted images displayed a decrease in hyperintense disease signal from the bone marrow space 48 hours after BZB treatment (Figure 2A). The mean ADC significantly increased from 802 ± 60 to $1157 \pm 27 \times 10^{-6} \text{ cm}^2 \text{ s}^{-1}$, even though tumour volume, measured by T_2 -weighted MRI, remained unchanged. Ig λ in blood sera corroborated a positive treatment response at 48 hours (Figure 2B).

Conclusions. MRI has confirmed that the novel intratibial model of MM maintains tumour growth throughout the murine BM, emulating clinical presentation. Serum Ig λ levels provided strong validation of MR volume calculations as a marker of disease progression, and consecutive scans showed high repeatability. These data suggest that the intratibial MM model is sensitive to the clinically approved, standard of care, anti-MM agent bortezomib, as well as the novel aminopeptidase inhibitor, tosedostat, and that MRI provides a non-invasive quantifiable measure of therapeutic efficacy, correlating with the gold-standard measures of disease. In addition, an early increase in tumour ADC may give a more specific, and clinically translatable, biomarker of therapeutic response in this model.

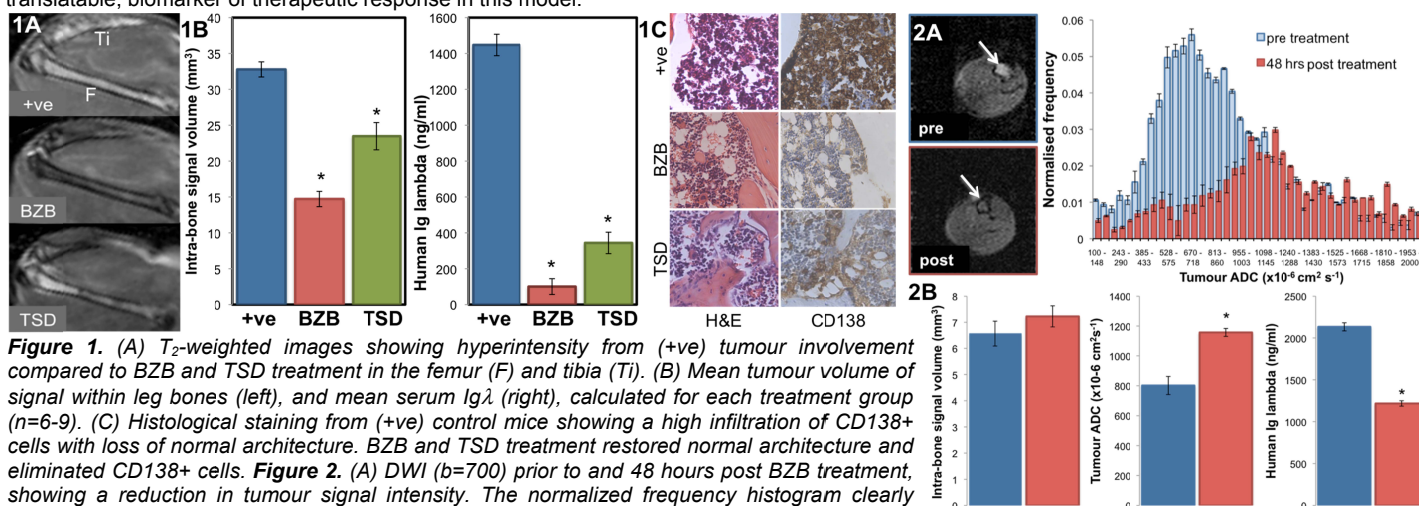


Figure 1. (A) T_2 -weighted images showing hyperintensity from (+ve) tumour involvement compared to BZB and TSD treatment in the femur (F) and tibia (Ti). (B) Mean tumour volume of signal within leg bones (left), and mean serum Ig λ (right), calculated for each treatment group (n=6-9). (C) Histological staining from (+ve) control mice showing a high infiltration of CD138+ cells with loss of normal architecture. BZB and TSD treatment restored normal architecture and eliminated CD138+ cells. **Figure 2.** (A) DWI (b=700) prior to and 48 hours post BZB treatment, showing a reduction in tumour signal intensity. The normalized frequency histogram clearly shows an acute, treatment-induced increase in the distribution of ADC values (n=3). (B) Mean tumour volume remained constant, mean ADC increased significantly, coincident with a significant decrease in serum Ig λ post BZB treatment (all data are mean \pm 1 s.e.m., *p<0.05).

References: 1) Terpos et al, *Ann of Oncol* 20, 1303, 2009. 2) Mundy, *Nature Cancer Rev* 2, 584, 2002.

We acknowledge the support received for the The Institute of Cancer Research CRUK and EPSRC Cancer Imaging Centre in association with the MRC and Department of Health (England), Myeloma UK, The Royal Society and NHS funding to the NIHR Biomedical Research Centre.