

Quantitative and Morphologic Evaluation of Cartilage Repair in an Equine Model

S. Pownder¹, M. F. Koff¹, L. Fortier², E. Castiglione³, R. Saska³, G. Bradica³, K. Novakofski², and H. G. Potter¹

¹Department of Radiology and Imaging - MRI, Hospital for Special Surgery, New York, NY, United States, ²College of Veterinary Medicine, Cornell University, Ithaca, NY, United States, ³Kensey Nash Corporation

Introduction. Magnetic resonance imaging (MRI) is optimal to evaluate articular cartilage due to excellent soft tissue contrast, multiplanar capabilities and lack of ionizing radiation. MRI is commonly performed following chondral injury and subsequent repair. Measurement of chondral defects may be obtained, and true osteochondral lesions may be differentiated from isolated chondral shears. Assessment of ultra-structure requires quantitative MR techniques, which measure tissue relaxation times. MRI assessment of proteoglycan content include sodium (Na^{23}) imaging, delayed gadolinium enhanced MRI of cartilage (dGEMRIC) and T1 ρ mapping; while T2 mapping is used to evaluate collagen orientation. The purpose of this study was to apply morphologic and quantitative MRI techniques to evaluate cartilage repair in an equine model.

Methods. A single osteochondral defect measuring 10 mm in diameter by was created bilaterally in the lateral trochlear ridge of 12 adult horses. One defect was treated with a proprietary scaffold; the other was treated with microfracture. All animals were sacrificed at the 2 year time point; immediate MR imaging was performed on the 24 stifle joints. **Image acquisition:** MR imaging was performed on a clinical 3.0 Tesla imaging system (GE Healthcare, Milwaukee WI), using an 8 channel transmit-receive phased-array knee coil. Morphologic imaging was performed using a cartilage-sensitive fast spin echo (FSE) sequence [1] with the parameters: TR: 5600 to 7500 ms, TE: 20-30 ms, FOV: 13-14 cm, acquisition matrix: 512 x (416-512), slice thickness: 1.5mm, NEX: 3, BW: ± 62.5 kHz. Quantitative T2 mapping of articular cartilage was performed to evaluate cartilage collagen orientation and water content using a multi-slice, multi-echo pulse sequence [2] with the parameters: TR: 1000ms, TEs: 7.4, 14.9, 22.3, 29.7, 37.2, 44.6, 52.0, 59.5 ms, FOV: 13 cm, acquisition matrix: 384 x 256, BW: ± 62.5 kHz. Three dimensional T1 ρ imaging [3] assessed relative proteoglycan content within the reparative tissue using the parameters: TE: 2.3 ms, TR: 6.3 ms, TSLs: 0, 20, 40, 60 ms, FOV: 14 cm, acquisition matrix: 256 x 160, slice thickness: 3.0 mm, BW: ± 41.7 kHz, VPS: 24, spin lock frequency: 500 Hz, NEX: 0.68 excitations. **Image analysis:** Morphologic FSE images were scored for thirteen subjective parameters, including signal intensity, flush/depressed appearance of repair, bony overgrowth, size of fissure(s), tissue fill, bony incorporation, presence of central high signal, presence of tidemark, ICRS grade of adjacent native tissue, synovial reaction, hypertrophy, or displacement of repair. Quantitative T2 and T1 ρ values were calculated on a pixel-by-pixel basis by fitting the echo time or spin lock time to the corresponding signal intensity data (Functool 3.1, GE Healthcare, Milwaukee WI) using a mono-exponential decay equation: $\text{SI}(\text{TE}) \propto \exp(-\text{TE}/\text{T2})$ and $\text{SE}(\text{TSL}) \propto \exp(-\text{TSL}/\text{T1}\rho)$, respectively. Regions of interest (ROIs) were obtained in both superficial and deep regions of the following areas: 1) center of the cartilage repair; 2) lateral and medial interfaces of the repair; and 3) native cartilage. **Statistical analysis:** Frequency tables were generated for morphologic scoring variables. A one-way analysis of variance (ANOVA) was performed separately for the superficial and deep zones to detect differences of T2 and T1 ρ values among the evaluated ROIs. A post-hoc Student-Neuman-Keuls test was performed when statistical significance was found. Statistical significance was set at $p < 0.05$.

Results. **Morphologic:** Most stifles had a clear pattern of signal hyperintensity (7/24, 29%) or hypointensity (9/24, 38%), with remaining stifles having mixed regions of signal hypo/hyperintensity. A majority of repair sites were flush with the surrounding cartilage (14/24, 58%). Bony overgrowth was only seen in 2 stifles (8%). A majority of fissures at the interface with native tissues were < 1 mm (14/24, 58%). Nine stifles had fissures 1-2mm in length (38%) and one stifle had a 2mm fissure. A majority of repair sites had $> 75\%$ tissue fill (18/24, 75%). Four stifles (17%) had 50-75% tissue fill and 2 stifles had 25-50% tissue fill. Complete or near-complete bony incorporation was seen in a majority of stifles (15/24, 63%) while partial bony incorporation was detected in the remaining stifles. A central high signal (global or punctate) was seen in most stifles (19/24, 79%). The cartilage adjacent to the repair site was graded as 0 (13/24, 54%) or 1 (11/24, 46%). Synovial reaction was only present in a small number (5/24, 20%) of stifles. No hypertrophy or displacement of the repair cartilage was demonstrated in any stifle. **Quantitative:** A significant difference of T1 ρ across the ROIs was detected in both the superficial and deep zones, $p < 0.0001$ and $p < 0.0001$, respectively. The center of the repair had the longest T1 ρ values (66.4 \pm 22.4 ms) in the superficial zone. The lateral interface (50.3 \pm 11.2 ms), the medial interface (49.5 \pm 7.1 ms) and native cartilage (42.0 \pm 5.2 ms), had similar superficial T1 ρ values. The center of the repair also had the longest T1 ρ values (57.1 \pm 18.6 ms) in the deep zone. The T1 ρ values of the lateral interface (44.4 \pm 9.4 ms) and the medial interface (42.7 \pm 6.9 ms) were similar and significantly longer than the native cartilage (33.2 \pm 4.0 ms) in the deep zone. A significant difference of T2 across the ROIs was detected in the superficial and deep zones, $p < 0.0001$ and $p < 0.0001$, respectively. The center of the repair had the longest T2 values (43.9 \pm 16.2 ms) in the superficial zone. The lateral interface (35.8 \pm 9.4 ms) and the medial interface (32.4 \pm 15.2 ms) had similar T2 values, but only the medial interface was similar to native cartilage (27.8 \pm 3.7 ms). The center of the repair also had the longest T2 values (37.7 \pm 15.2 ms) in the deep zone. The T2 values of the lateral (24.1 \pm 6.8 ms) and the medial interfaces (23.6 \pm 9.5 ms) were similar and significantly longer than the native cartilage (16.4 \pm 2.7 ms) in the deep zone.

Discussion. The repair sites demonstrated variable morphologic and quantitative results. Immature repair tissue is typically associated with hyperintensity; mature fibrocartilage is typically hypointense relative to native cartilage. Quantitative data displayed significantly longer T2 and T1 ρ values of the central repair, reflecting the increased mobility of water in the immature tissue. The prolonged values with wider standards of deviation located centrally indicate non-uniformity of the repair tissue relative to the native articular cartilage. It is suspected that the slightly reduced T1 ρ and T2 values at the interface indicate peripheral incorporation with the native tissue with diminished proteoglycan and collagen orientation in the center of the repair. Histologic analysis with tissue specific stains is pending to confirm this hypothesis. This study demonstrates the feasibility of performing comprehensive morphologic and quantitative MRI in a preclinical model of cartilage repair at clinically relevant field strengths. When correlated to histology, these data will be important for the expected application to clinical cartilage repair trials. **References.** 1. Potter HG, et al. *J Bone Joint Surg Am* 80(9), 1998. 2. Maier CF, et al. *J Magn Reson Imaging* 17(3), 2003. 3. Li X, et al. *Magn Reson Med* 59(2), 2008. **Acknowledgements.** This work funded by Kensey Nash Corporation and an institutional research agreement with General Electric Healthcare.

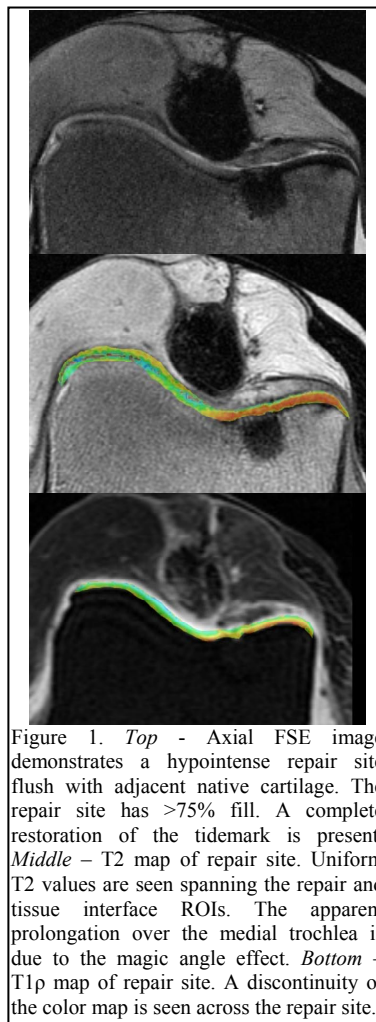


Figure 1. *Top* - Axial FSE image demonstrates a hypointense repair site flush with adjacent native cartilage. The repair site has $> 75\%$ fill. A complete restoration of the tidemark is present. *Middle* - T2 map of repair site. Uniform T2 values are seen spanning the repair and tissue interface ROIs. The apparent prolongation over the medial trochlea is due to the magic angle effect. *Bottom* - T1 ρ map of repair site. A discontinuity of the color map is seen across the repair site.