

Reversal of abnormal ADC lags reperfusion and does not necessarily represent tissue salvage

H. An¹, A. L. Ford², K. D. Vo³, W. J. Powers⁴, J-M. Lee², and W. Lin¹

¹Radiology, University of North Carolina at Chapel Hill, Chapel Hill, NC, United States, ²Neurology, Washington University in St. Louis, St. Louis, MO, United States, ³Radiology, Washington University in St. Louis, St. Louis, MO, United States, ⁴Neurology, University of North Carolina at Chapel Hill, Chapel Hill, NC, United States

Introduction

Magnetic resonance diffusion weighted imaging (DWI) is widely utilized in clinical practice to depict acute ischemic stroke lesions. It has been demonstrated that compromised blood flow leads to a reduction in the apparent diffusion coefficient (ADC) during ischemia^{1,2}. Conversely, DWI lesions have been found to reverse after thrombolysis³⁻⁵. The temporal behavior of ADC lesion reversal after reperfusion during the first hours after stroke onset has not been documented in humans. Moreover, it has not been thoroughly investigated whether the perfusion status at the time of or subsequent to an abnormal ADC measurement affects the final fate of tissue. To this end, a sequential MR imaging study was performed in human stroke in order to examine the temporal evolution of reduced ADC in specific brain regions with different perfusion characteristics. Risk of infarction was measured and compared.

Methods

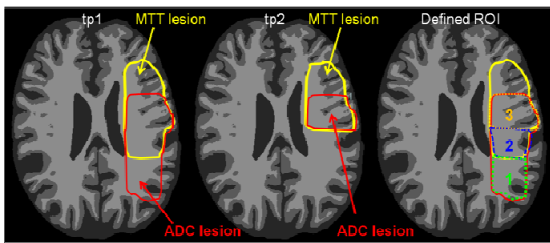


Figure 1. Schematic representation of the definition of three ROIs. Yellow color outlines MTT lesion at tp1 and tp2, and red color outlines ADC lesion at tp1 and tp2. Region 1 represent ROI (1) that exhibits abnormal ADC at tp1 but normal MTT at tp1 and tp2; Region 2 represent ROI (2) that has abnormal ADC and MTT at tp1 and normal MTT at tp2; and region 3 represent ROI (3) that showed abnormal ADC at tp1 and abnormal MTT at tp1 and tp2.

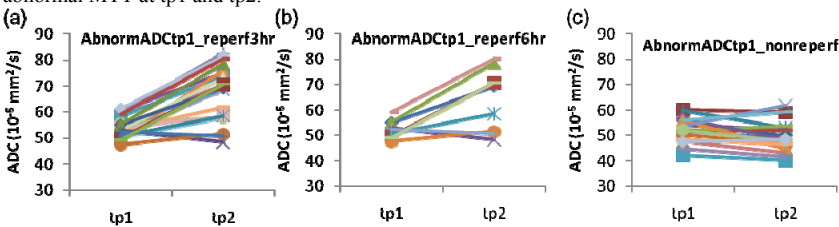


Figure 2. (a) Temporal evolution trends of ADC from ROI_{AbnormADctp1_reperf3hr} (a), ROI_{AbnormADctp1_reperf6hr} (b), and ROI_{AbnormADctp1_nonreperf} (c) for each individual patient between tp1 and tp2 after stroke onset.

restored perfusion and ADC recovery. Depending on the acquisition time, very different ADC values may be obtained in regions with stable reperfusion. ROI(2)_{abnormADctp1_reperf6hr}, representing reperfusion between tp1 (3 hours) and tp2 (6 hours), were detected in nine subjects. Reperfusion occurred from tp1 to tp2, while an increase of ADC were observed in 7 out of 9 subjects (Fig. 2b). ROI(3)_{abnormADctp1_nonreperf}, representing an initially low perfusion/abnormal diffusion *matched* region without reperfusion, were detected in 19 participants. ADC remained low or slightly decreased further from tp1 to tp2 (Fig. 2c).

ADC increase or decrease at tp2 in these three regions was strongly associated with reperfusion status ($P < 0.0001$, ANCOVA analysis). The median risk of infarction and interquartile range (IQR) were found to be 64.2% (IQR [56.2%, 82.7%]) for ROI(1)_{abnormADctp1_reperf3hr}, 84.3% (IQR [30.2%, 88.5%]) for ROI(2)_{abnormADctp1_reperf6hr}, and 94.4% (IQR [83.5%, 97.9%]) for ROI(3)_{abnormADctp1_nonreperf}. One-way ANOVA analysis showed significantly different risks of infarction among three ROIs ($P < 0.01$). Newman-Keuls post tests further revealed that risks of infarction in ROI(3)_{abnormADctp1_nonreperf} are significantly higher than ROI(1)_{abnormADctp1_reperf3hr} and ROI(2)_{abnormADctp1_reperf6hr} ($P < 0.05$). The fact that all three groups had similar initial ADC reductions but different risks of infarction highlights the failure of a single ADC measurement at 3 hours after stroke onset to accurately reflect tissue outcome and the importance of concurrent and subsequent perfusion status in this determination.

Discussion and Conclusions

This study focused on elucidating the temporal relationship between perfusion and ADC utilizing two sequential MR scans during hyper-acute stroke (within 3 hours and at 6 hours). We found a temporal dissociation between ADC change and perfusion alterations, with ADC changes lagging behind reperfusion. In this study, we also assessed how different perfusion characteristics affect the predictive value of low ADC for the risk of infarction. We found that ADC recovery subsequent to reperfusion does not necessarily predict tissue salvage.

References

1. Lin et al. *Stroke*. 2003;34:64-70;
2. Guadagno et al. *Stroke*. 2006;37:1741-1748;
3. Kidwell et al. *Ann Neurol*. 2000;47:462-469;
4. Chalela et al. *Ann Neurol*. 2004;55:105-112;
5. Fiehler et al. *Stroke*. 2002;33:79-86

Thirty-one participants were serially scanned with a 3T whole body Trio system MRI (Siemens) at 3 time points (tp): within 3.5 hours (tp1), at 6 hours (tp2), and at 1 month (tp3) after stroke onset. Imaging protocols, including DWI, FLAIR and dynamic susceptibility contrast (DSC) PWI were performed at both tp1 and tp2. FLAIR images acquired at tp3 were used to manually delineate the final lesion. Image registration was performed to align all images acquired at different time. Hypoperfusion was defined using MTT > 4 seconds longer than the mean contralateral hemispheric. Voxels with ADC values < mean-2*SD of the contralateral hemisphere were defined as abnormal. Based on the MTT at tp1 and tp2 and ADC at tp1, three regions of interest (ROIs) were defined (Figure 1): ROI(1)_{abnormADctp1_reperf3hr} exhibited abnormal ADC at tp1 and normal MTT at both tp1 and tp2, suggesting regions with abnormal ADC caused by earlier ischemia that was reperused prior to tp1 (<3 hours); ROI(2)_{abnormADctp1_reperf6hr} exhibited abnormal ADC and MTT at tp1, and normal MTT at tp2, suggesting ischemia with reperfusion between tp1 (3 hours) and tp2 (6 hours); and ROI(3)_{abnormADctp1_nonreperf} exhibited abnormal ADC at tp1 and abnormal MTT at both tp1 and tp2, representing ADC lesions with persistent hypoperfusion. In all ROIs, isolated regions smaller than 1 ml were removed to minimize artifacts due to misalignment.

ADC values from all three ROIs were obtained to examine the temporal evolution trend from tp1 to tp2. To assess the effect of reperfusion status (reperfusion <3hr, reperfusion 3-6 hr, and without reperfusion) on an initially abnormal ADC region, a generalized linear model (SAS 9.2) was utilized to perform an analysis of covariance (ANCOVA) to evaluate whether reperfusion and/or tp1 ADC values might affect ADC change from tp1 to tp2 ($\Delta ADC = ADC_{tp2} - ADC_{tp1}$) in all three ROIs. One-way analysis of variance (ANOVA) with Newman-Keuls multiple comparison post test was performed to evaluate whether the risk of infarction differed among all three ROIs.

Results

ROI(1)_{abnormADctp1_reperf3hr}, representing hyperacute reperfusion (< 3 hours), were identified in 12 subjects. From tp1 to tp2, MTT were normal, while the abnormal ADC lesion reversed from tp1 to tp2 (Fig. 2a). This finding indicates a temporal dissociation between reperfusion and ADC improvement, with an interval delay between reperfusion and ADC recovery.