

Preoperative Nomograms Incorporating Magnetic Resonance Imaging and Spectroscopy for Prediction of Insignificant Prostate Cancer

A. Shukla-Dave¹, H. Hricak¹, O. Akin¹, C. Yu², K. L. Zakian¹, V. Reuter¹, P. T. Scardino¹, J. Eastham¹, and M. W. Kattan²

¹Memorial Sloan-Kettering Cancer Center, New York, NY, United States, ²Cleveland Clinic, Cleveland, OH, United States

Introduction

Prostate cancer is the most commonly diagnosed cancer in American men (1). With the widespread use of prostate-specific antigen (PSA) testing, there has been a dramatic shift to early stage cancers (2). Insignificant prostate cancers (PCa) pose little risk to life or health, but they are difficult to identify clinically. Keeping this in mind, the aims of the present study were to 1) validate the previously published preoperative MR-based nomograms for predicting the probability of insignificant prostate cancer; and 2) design new nomograms incorporating MR Imaging (MRI), MR Spectroscopic Imaging (MRSI) and clinical data without detailed biopsy data for predicting the probability of insignificant prostate cancer (PCa).

Materials and Methods

Prospective study of 181 patients with low-risk PCa (Gleason score ≤ 6 , PSA < 10 ng/ml) who underwent combined MRI/MRSI prior to radical prostatectomy. Written informed consent was obtained from each patient prior to MR examination. Surgical pathology was used as the standard of reference (3). Data were acquired on a 1.5 Tesla scanner (GE, Milwaukee, WI). The study consisted of MR imaging using a pelvic phased array and expandable endorectal coil followed by standard MRSI protocol with PRESS voxel excitation and water and lipid suppression (3, 4). MRSI data were obtained and processed using GE software PROSE (prostate spectroscopy). The probability of insignificant cancer by MRI and MRSI findings were recorded based on previously published (3) scoring system: 0-3 scale (0, definitely insignificant PCa (no abnormality) - 3, significant PCa (definite abnormality $> 0.5\text{cm}^3$). The new baseMRI model combines PSA, clinical stage, prostate volume on MR imaging and MRI score. The new baseMRI/MRSI model has the same variables except that the MRI score is replaced with the overall MRI/MRSI score (Figure 1). The biopsy Gleason score is omitted from the new MR nomograms because patients with only Gleason score 3+3 were included in the study, so the grade would not contribute to the point scale in the nomograms. We used receiver operating characteristic (ROC) curves to assess the incremental value of the 2 new MR models mentioned above to the existing Base, Medium, MRI and MRI/MRSI models (3,5). The latter two now termed as mediumMRI and mediumMRI/MRSI models.

Results

At pathology, twenty seven percent of the patients had insignificant PCa defined as organ confined cancer $\leq 0.5\text{cm}^3$ in volume without poorly differentiated elements. The surgical Gleason score remained the same as the biopsy Gleason score of 6 for 43.6% of patients but was higher for 56.4% of patients. All MR models demonstrated good calibration. When the previously published Base and Medium models were applied to the patient population in this prospective study, the resulting AUCs were 0.558 and 0.707, respectively; the Medium model performed significantly better than the Base model ($P = 0.001$). These results were consistent with the earlier findings. All four MR models were more accurate than the Base model for discriminating insignificant from significant PCa ($p \leq 0.001$ for all). However, none of them was significantly more accurate than the Medium model ($P \geq 0.065$ for all) (Figures 2 and 3). MR data was helpful in predicting significant PCa in the low-risk patient population studied. 63/90 (70%) patients with an MRI score of 3 (definitely significant PCa) had tumor volume $> 0.5\text{cm}^3$. As expected, the findings of a non-nodular region with reduced T2-weighted signal $> 0.5\text{cm}^3$ (indeterminate MRI category) was non-specific. 6/9 (67%) patients with an MRI score of 0 or 1 had tumor volume $< 0.5\text{cm}^3$ and 5/9 (56%) had insignificant PCa. The misclassification of definitely or probably insignificant PCa was due to underestimation of the Gleason grade at biopsy. With the addition of MRSI to MRI, the imaging score was changed for 13 patients from indeterminate to significant cancer; the change was correct in 11/13 patients; the two patients misclassified had total tumor volume $< 0.5\text{cm}^3$ but

Gleason score 7. Overall the addition of MRSI improved predictive accuracy (Figure 3).

Discussion and Conclusion

In the present study, the biopsy Gleason score was upgraded in more than half of the patients (56.4%) at surgical pathology. Physicians often repeat biopsy or opt for saturation biopsy to obtain a more comprehensive evaluation, but they should exercise caution in making such decisions, as Gallina, et al. have observed an association between prostate biopsy and an increased rate of mortality (6). The certainty of this association, however, remains to be proven. We have successfully validated the previously published MR nomogram models for predicting the probability of insignificant PCa in patients with clinically low-risk disease. The new BaseMRI and BaseMRI/MRSI models performed similarly to the Medium model incorporating detailed biopsy data and in future may obviate the need for repeat biopsy to obtain for additional such data. Additionally, MRI and MRI/MRSI performed better in identifying significant rather than insignificant disease. Hence, the nomogram models incorporating MR findings may show that aggressive therapy is warranted in certain men whose disease would otherwise appear to be low risk.

References 1. Cancer facts and figures 2010. pp. 1-68. Atlanta, GA: American Cancer Society, 2010; 2. A.V.D'Amico, et al., J Clin Oncol., 23(22), 4975, 2005; 3. A. Shukla-Dave et al, BJU Int 99:786, 2007; 4. Y. Mazaheri et al, Radiology 246:480-8, 2008; 5. M.W. Kattan, et. al., J Urol, 170, 1792 , 2003. 6. A.Gallina et al. Int J Cancer 123:647, 2008

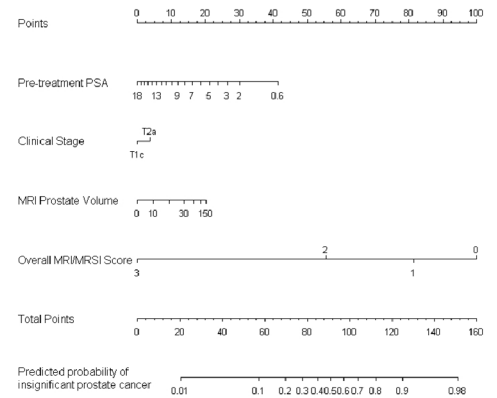


Figure 1. BaseMRI/MRSI nomogram model. In the model for locating the patient's pretreatment PSA on the PSA axis. Draw a line straight upwards to the Points axis to determine how many points towards having an insignificant cancer the patient receives for his PSA. Repeat this process for each variable. Sum the points achieved for each predictor and locate this sum on the Total Points axis. Draw a line straight down to find the patient's probability of having insignificant PCa.

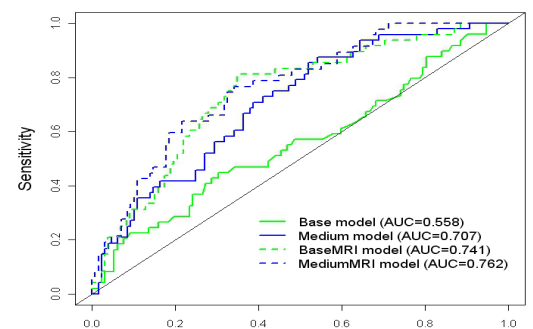


Figure 2. Comparison of receiver operating characteristic (ROC) curves for the Base, Medium, BaseMRI and MediumMRI models.

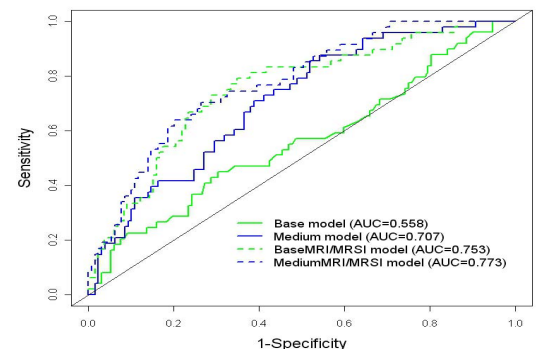


Figure 3. Comparison of ROC curves for the Base, Medium, BaseMRI/MRSI and MediumMRI/MRSI models.