

## Can DCE-MRI predict pathological complete response after neoadjuvant chemoradiation therapy in rectal cancer patients? Initial observations in 38 patients.

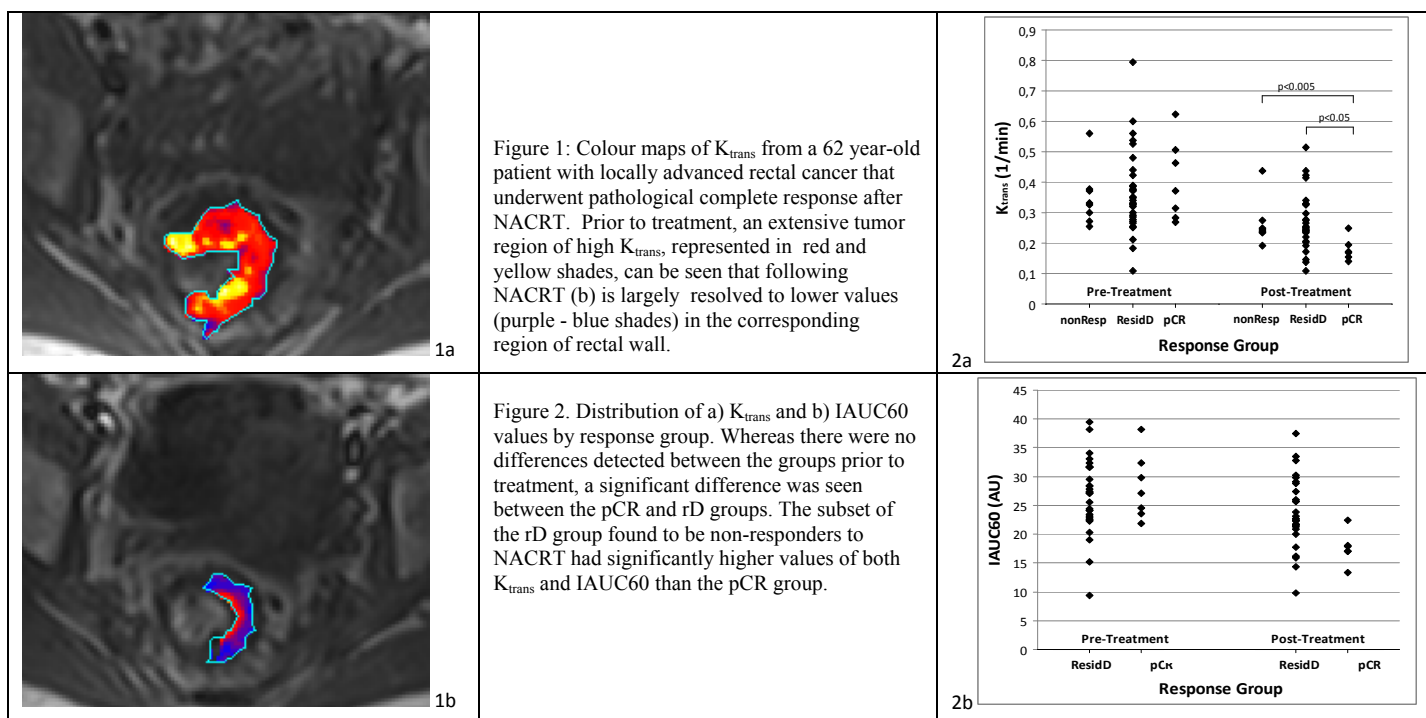
G. Petralia<sup>1</sup>, P. Summers<sup>1</sup>, S. Viotti<sup>2</sup>, L. Bonello<sup>2</sup>, M. Pasin<sup>1</sup>, M. G. Zampino<sup>3</sup>, M. C. Leonardi<sup>4</sup>, L. Travaini<sup>5</sup>, V. Panebianco<sup>6</sup>, and M. Bellomi<sup>1,2</sup>

<sup>1</sup>Radiology, European Institute of Oncology, Milan, Milan, Italy, <sup>2</sup>School of Radiology, University of Milan, Milan, Italy, <sup>3</sup>Medical Care Unit, Medicine, European Institute of Oncology, Milan, Milan, Italy, <sup>4</sup>Radiotherapy, European Institute of Oncology, Milan, Milan, Italy, <sup>5</sup>Nuclear Medicine, European Institute of Oncology, Milan, Milan, Italy, <sup>6</sup>Radiological Sciences, Policlinico Umberto I, University "Sapienza", Rome, Italy

**BACKGROUND:** Rectal cancer patients with pathological complete response (pCR) after neoadjuvant chemoradiation therapy (NACRT) have better long-term outcome than do those without pCR [1]. For these patients there is increasing evidence that minimalist approaches (transanal excision or observation alone) might be reasonable alternatives to the standard of care (radical surgery), with equivalent outcomes [2]. Conventional T2-weighted MRI (T2WMRI) at baseline is not predictive of subsequent response to therapy, and post-treatment, has poor potential for predicting pCR. Dynamic contrast enhanced (DCE) – MRI provides information which goes beyond morphology and has shown some potential to predict response to therapy [3]. The purpose of this study was to evaluate the potential of DCE-MRI for predicting pCR after NACRT in rectal cancer patients.

**METHODS AND MATERIALS:** The study was approved by our institutional ethics committee; written informed consent was obtained from all participants before entry into study. 38 patients (23M, <15F; mean age 63 ±12 years) with locally advanced rectal non-mucinous adenocarcinoma (T stage ≥ T3, or N1-2 as staged by MRI) underwent conventional MRI for staging and DCE-MRI for functional assessment before and after (n=34) NACRT, prior to surgery. All exams were performed on a 1.5T Siemens Avanto scanner (Siemens Medical Systems). The parameters for the base sequence for the DCE protocol were 12 slice 3D gradient echo (VIBE) sequence, TE/TR: 1.2 / 4 ms, FOV/SLT of 360mm/5mm. Flip angles of 2 and 24° were used for T1 mapping prior to contrast injection. The dynamic acquisition used a flip angle of 24° repeated at 5s intervals for 8 minutes after intravenous injection of gadopentetate dimeglumine (0.2 mL/Kg, 3.5 mL/sec), followed by saline (20 mL, 3.5 mL/sec). Regions of interest (ROIs) were drawn by a radiologist on the dynamic time series images with reference to T2WMRI acquired in the same orientation without access to the pharmacokinetic maps. The tumour was delineated on the 8 central slices of the acquired stack to avoid slab profile effects. Pharmacokinetic modelling followed Tofts model with a cosine input function calculated voxel-wise using the MRI Workbench software (MRIW, Institute of Cancer Research, Sutton England). For each ROI, the mean, median, standard deviation, and individual voxel values of: transfer constant,  $K_{trans}$ ; leakage space,  $V_e$ ; rate constant,  $K_{ep}$ ; and integral of the area under the curve, IAUC60 were then extracted. According to the pathologic stage on the surgical specimen, patients were categorized into those who achieved a pCR (ypT0ypN0) and those who had residual disease (rD) after surgery (including local downstaging, no local downstaging or increase in local stage). Distinctions between patients with pCR and those with residual disease were assessed using Students t-tests. Overall differences pre and post-neoadjuvant therapy were quantified using paired t-tests.

**RESULTS:** Examples of  $K_{trans}$ ,  $K_{ep}$ ,  $V_e$  and IAUC60 maps for the pre- and post-treatment tumour ROIs in one patient are seen in Figure 1. Four of 38 patients recruited have not yet completed NACRT; of the 34 who have, seven patients showed pCR (20.5%). The 27 remaining patients showed residual disease at surgery, with eight patients not responding (i.e. surgical stage equal to or higher than baseline staging with MRI). Baseline  $K_{trans}$ ,  $K_{ep}$ ,  $V_e$  and IAUC60 were not significantly different between the pCR and rD patient groups. Post-therapy  $K_{trans}$  (Figure 2a) and IAUC60 (Figure 2b) were significantly lower in the pCR group than in the rD group, as was the percentage change in  $K_{trans}$  relative to baseline. The local downstaging group showed a large spread of values for all parameters that tended to encompass both the non-responder and pCR group values. Considering the subgroup of non-responders however, there was limited overlap with the  $K_{trans}$  values seen in pCR at the end of NACRT (Figure 2).



**CONCLUSIONS:** Post-therapy  $K_{trans}$  and IAUC60 were lower in the pCR group of patients with locally advanced rectal adenocarcinoma having undergone NACRT than in the rD group. While this suggests sensitivity to changes in the status of the pathology, the considerable overlap of pharmacokinetic parameter values between the pCR and rD groups precludes identification of patients with pCR on the basis of DCE-MRI alone. That post-NACRT  $K_{trans}$  and IAUC60 values largely separate the pCR patients from those found to be non-responders (e.g. with thresholds of 0.2 and 20 respectively) may suggest a possible use of DCE-MRI in mid-therapy assessment of NACRT.

### REFERENCES:

- [1] Maas M, Nelemans PJ, Valentini V, et al. Long-term outcome in patients with a pathological complete response after chemoradiation for rectal cancer: a pooled analysis of individual patient data. *Lancet Oncol.* 2010 Sep;11(9):835-44. Epub 2010 Aug 6.
- [2] Smith FM, Waldron D, Winter DC. Rectum-conserving surgery in the era of chemoradiotherapy. *Br J Surg.* 2010 Sep 15. [Epub ahead of print]
- [3] George ML, Dzik-Jurasz AS, Padhani AR, Brown G, Tait DM, Eccles SA, Swift RI. Non-invasive methods of assessing angiogenesis and their value in predicting response to treatment in colorectal cancer. *Br J Surg.* 2001 Dec;88(12):1628-36.