

Non-contrast Outer Radial Inner Square k-space Scheme (NORISKS)- a breath-held balanced SSFP-Dixon technique for non-contrast enhanced renal MRA

M. Saranathan¹, P. W. Worters¹, and S. Vasanawala¹
¹Radiology, Stanford University, Stanford, CA, United States

Purpose: Nephrogenic systemic fibrosis (NSF) concerns associated with Gadolinium based contrast agents have spurred a resurgence in non-contrast enhanced MR Angiography (MRA) methods. Balanced steady state free precession (b-SSFP) imaging [1-3], due to its high SNR/CNR and short scan times, has been successful in coronary and renal angiography. Most current methods use respiratory gating which performs poorly during irregular breathing/sleep apnea. We propose a 3D b-SSFP-Dixon technique with a novel k-space segmentation scheme for **breath-held** (BH) non-contrast renal MRA without compromising coverage or spatial resolution. The sequence was tested on healthy subjects as well as patients.

Methods: A novel hybrid between a radial fan beam and a group-encoded k-space segmentation scheme [3] (Fig 1a) was developed as shown in Fig 1b. The central 10×10 region was ordered sequentially in k_y and centrally in k_z , as in Fig. 1a. To minimize eddy currents and flow dephasing, adjacent k-space points were paired as described in [4]. The remainder of k-space was segmented into radial fan beams with the corners skipped. This new k-space segmentation permitted us to significantly improve the image quality using the scheme shown in Fig. 1a by restricting the views-per-segment (VPS) to 100 for the center of k-space while maintaining short breath-holding times using larger VPS for the radial fan beam segments. Smearing artifacts and poor contrast resulting from a pure radial fan-beam trajectory was also eliminated. The central segment can optionally be ECG-gated with minimal increase in scan time. We refer to this scheme as NORISKS –Non-contrast Outer Radial Inner Square k-space Scheme. Bloch simulations of b-SSFP showed that it was possible to use a VPS of 800 with minimal reduction in blood-tissue contrast (Fig. 2). A 3D dual-echo bipolar readout pulse sequence with a robust two-point Dixon reconstruction algorithm [5] was used for fat-water separation. A slab-selective hyperbolic secant π pulse extended in the inferior direction relative to the acquisition slab simultaneously effected venous and background suppression. The inversion time was chosen to trade-off background/venous blood suppression and in-flowing arterial blood signal and was set to 1400 ms at 3T.

Experiments: Imaging parameters: 55° flip, ±167 kHz bandwidth, TR/TE₁/TE₂ 4.1/1.3/2.4 ms, 224×256 matrix, 35-37 cm FOV, 1.4 mm thick, 32-40 slices, 800 k-space points per radial segment, TI=1400ms. A self-calibrating hybrid space parallel imaging scheme with an acceleration factor of 2.5 was used in the phase encoding direction. This resulted in an overall breath-holding time of 24-26s. Fourteen subjects (9 patients, 5 healthy subjects) were imaged on a 3T GE MR750 system (GE Healthcare, Waukesha, WI) using an 8-channel torso array coil under an IRB-approved protocol. In addition, contrast-enhanced (CE) MRA and/or vendor supplied respiratory gated b-SSFP IR sequence (InHance) with chemical fat suppression were acquired.

Results: Figure 3 compares a group-encoded segmentation scheme (a) with the proposed hybrid scheme (b). Note the excellent arterial-background contrast and reduced flow artifacts (aorta ghosting) in the new scheme due to the central square segmentation with a short VPS. Figure 4 compares MIPs from a 24s breath-hold NORISKS acquisition (a) on a patient with right renal aneurysm with a conventional CE MRA MIP (b). Note the significantly better depiction of the aneurysm in the BH scan. Figure 5 compares MIPs from a 3 minute respiratory-gated InHance scan (a) and a 24s breath-hold NORISKS scan (b) demonstrating the improved contrast and comparable spatial resolution/coverage of the proposed NORISKS scheme in a short breath-hold.

Discussion: The proposed NORISKS technique yields robust fat suppression, high SNR/contrast and excellent visualization of the renal vasculature, especially at 3T where conventional fat suppression is suboptimal. By pairing k-space points in the central 10×10 square, flow artifacts and eddy currents were minimized and the short VPS significantly improved contrast over previous BH schemes. Using a VPS=800 for the radial fan beams maintained IR contrast while limiting the BH time to under 25s. The use of Dixon fat separation eliminated conventional fat suppression pulses, which are also suboptimal with large VPS (unlike IR) due to the short T₁ of fat.

References: [1] Katoh et al. *Kidney Int* 66:1272–1278 (2004) [2] Takei et al. *Proc ISMRM*, p3420 (2008) [3] Saranathan et al. *Proc. ISMRM*, p3774 (2010) [4] Bieri et al. *MRM*. 54:901-907 (2005) [5] Ma et al. *MRM*. 52:415-419 (2004) **Acknowledgments:** GE Healthcare & NIH P41- RR009784

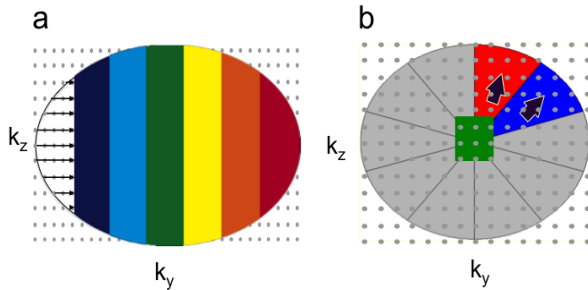


Figure 1 (left): (a) Group-encoded scheme. (b) The proposed hybrid scheme where the central square is encoded as in one segment of (a) and the outer regions are radial fan beams.

Figure 2 (right): Bloch equation simulation showing background/venous M_z/M_y vs. VPS following an inversion. Note that after VPS= 300, M_y remains constant.

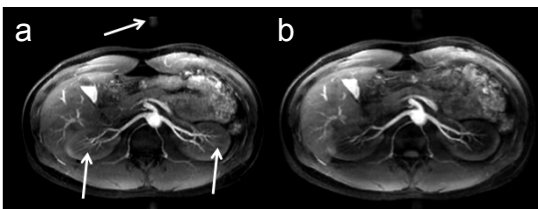
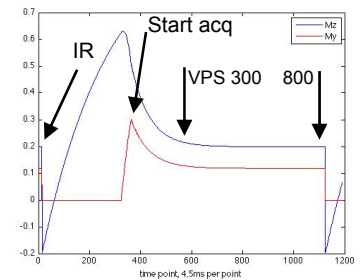


Figure 3: Group-encode scheme showing aortic ghosting and poor vessel-background contrast (a) with our proposed hybrid NORISKS method showing minimal ghosting and improved contrast due to the square central region.

Figure 4 (top): MIPs from a 25s BH NORISKS scan (a) showing the right renal aneurysm (arrow) not clearly discernible in the CE MRA scan (b).

Figure 5 (bottom): 3 min respiratory gated InHance scan (a) compared to a 24s BH NORISKS scan (b) on a patient with missing right kidney and trauma to the left kidney showing comparable spatial resolution and image quality and improved fat suppression with NORISKS.

