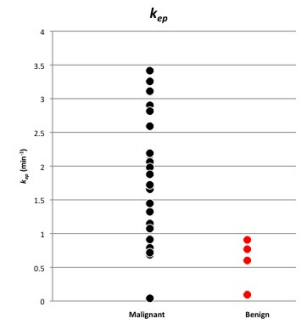


Clinical application of pharmacokinetic analysis as a biomarker in solitary pulmonary nodules: Dynamic contrast enhanced MR imaging

H. Mamata^{1,2}, J. Tokuda^{1,2}, R. R. Gill^{1,2}, R. F. Padera^{2,3}, R. E. Lenkinski^{2,4}, D. J. Sugarbaker^{2,5}, and H. Hatabu^{1,2}

¹Radiology, Brigham and Women's Hospital, Boston, MA, United States, ²Harvard Medical School, Boston, MA, United States, ³Pathology, Brigham and Women's Hospital, Boston, MA, United States, ⁴Radiology, Beth Israel Deaconess Medical Center, Boston, MA, United States, ⁵Thoracic surgery, Brigham and Women's Hospital, Boston, MA, United States

Background and purpose: Lung cancer is the most common cause of cancer death in both men (30%) and women (26%) in the United States and world. Five-year survival rate of all patients with lung cancer ranges from 13% to 18% [1]; however, early detection and resection at Stage I tumor of less than 20 mm in size, the 5-year survival rate is as high as 70-75% [2]. Dynamic contrast CT, positron emission tomography (PET), and dynamic contrast enhanced (DCE) MRI are examples of the non-invasive techniques. While each technique gives a certain level of reliable results to diagnose a malignant solitary pulmonary nodule (SPN), DCE-MRI offers a radiation-free non-invasive option to the patients. Recent advances in MRI technology made lung imaging much more acceptable and desirable for detailed analysis. Several studies have been published on DCE-MRI in lung cancer discussing diagnostic role of perfusion indices [3]; however, very little has been investigated on pharmacokinetic parameters, such as trans-endothelial transfer constant (K^{trans}), extravascular extracellular volume fraction (v_e) and k_{ep} (K^{trans}/v_e) [4]. In this study, we discuss clinical application of pharmacokinetic analysis as a biomarker in diagnosis of malignant SPNs. **Materials and Methods:** Thirty-four patients (9 males, 25 females, 26-87 years old, average 65 years old) with a SPN between 15 to 30mm entered this study. The study was conducted under the guideline of the Internal Review Board and a written informed consent was obtained from all the participants. The initial diagnosis of SPN was made by CT and chest x-ray, and all patients underwent MRI study including T2-weighted axial half-Fourier acquisition single-shot turbo spin-echo (HASTE) images, pre and post contrast T1-weighted axial, sagittal, and coronal volumetric interpolated breath-hold examination (VIBE) images, and 2D turbo FLASH perfusion imaging. The perfusion study was performed with shallow free breathing. All MRI studies were performed on a 3T-superconducting magnet (Siemens Trio, TIM system, Erlangen, Germany) using a body array coil. After the imaging study, histological diagnoses were made in 30 SPNs (4 SPNs were considered clinically benign and followed by CT). MRI parameters were as follows: T2-weighted HASTE (TR/TE=1200/100msec, FOV=400mm, 320x320, 1 excitation, BW=780kHz, FA=150, ETL=256, 5.5mm slice thickness/1.6mm inter slice gap, scan time=6min); T1-weighted VIBE (TR/TE=3.4/1.3msec, FOV=400mm, 260x320, 1 excitation, BW=505kHz, FA=10, 4mm slice thickness/0mm inter slice gap, scan time=1.7min); turbo FLASH (TR/TE=500/1.6msec, FOV=400mm, 192x180, 1 excitation, BW=360kHz, FA=10, 5mm slice thickness, oblique sagittal orientation, Temporal resolution=2sec, 124 frames, scan time=4min, Gd-DTPA iv. 0.1 mmol/kg). B-spline non-rigid image registration and Chi-square optimization were performed on DCE-MRI to better calculate parameters [5]. Mean transit time (MTT), time-to-peak (TTP), initial slope (IS), and maximum enhancement (E_{max}) were calculated from time-intensity curves. Time-intensity curves were classified into 4 types (A-D) by three experienced radiologists, who evaluated these curves to diagnose malignant SPNs. K^{trans} , v_e , and k_{ep} were calculated based on the two-compartment model [6]. After blinded data analysis, correlation with tissue histology, from the surgical resection was performed. **Results:** Of 30 patients, 27 underwent surgical resection, and 3 underwent CT-guided needle biopsy. The histology included 17 adenocarcinomas, 5 squamous cell carcinomas (SCC), 3 carcinoid tumors, 1 benign solitary fibrous tumor, 1 sclerosing pneumocytoma, 1 hamartoma, 1 reactive nodule, and 1 mycobacterial granuloma. Two out of 30 SPNs demonstrated Type A curve pattern (both malignant), 19 SPNs (2 benign and 17 malignant) showed Type B curve, 6 SPNs (1 benign and 5 malignant) showed Type C curve, and 3 SPNs (2 benign and 1 malignant) showed Type D curve. In predictive diagnosis of a malignant SPN by time intensity-curve pattern, where Type A considered most malignant and Type D considered most benign nature, made by 3 experienced radiologists, sensitivity ranged from 84-96%, specificity 50-80%, accuracy 83-90%, positive predictive value 92-96%, negative predictive values 50-75%. We analyzed each index and parameter value by histology type, malignant vs. benign. Average MTT was slightly higher in malignant SPNs than benign SPNs ($p=0.037$). Average TTP was slightly shorter in malignant SPNs than benign SPNs ($p=0.011$). Average IS was steeper ($p=0.032$) and E_{max} was larger (not statistically significant, $p=0.062$) in malignant SPNs than benign SPNs. Average K^{trans} was higher in malignant SPNs than benign SPNs ($p=0.037$). Average v_e did not show statistically significant difference between malignant and benign SPNs ($p=0.676$). Finally, average k_{ep} for malignant SPNs was $1.88 \pm 0.86 \text{ min}^{-1}$, for benign SPNs was $0.68 \pm 0.32 \text{ min}^{-1}$, which difference in values was the most significant ($p=0.005$) among all the indices and the parameters. Twenty-one of 25 (84%) malignant SPNs demonstrated k_{ep} greater than 0.90 min^{-1} , and 4 demonstrated k_{ep} less than 0.90 min^{-1} . All benign SPNs had k_{ep} equal or less than 0.90 min^{-1} . At cutoff $k_{ep}=0.90 \text{ min}^{-1}$, sensitivity for diagnosing malignant SPNs; 84%, specificity; 100%, positive predictive value; 100%, negative predictive value; 56%, and accuracy; 87%. Figure above shows distribution dot-plot of k_{ep} value for malignant vs. benign SPNs. **Discussion:** Among perfusion indices (MTT, TTP, IS, and E_{max}) and pharmacokinetic parameters (K^{trans} , v_e , and k_{ep}), k_{ep} is a key to characterize histology of a solitary pulmonary nodule. Malignant tumors demonstrated statistically significant higher values in K^{trans} , MTT and IS, significant lower value in TTP compared with benign tumors. However, individual value of these parameters and indices showed many overlapping values in malignant and benign tumors and their histology could not be separated by those values. On the other hand, k_{ep} distinguished malignant from benign tumors most accurately. The large majority (84%) of malignant tumors showed a k_{ep} value greater than 0.90 min^{-1} with few exceptions, while all benign tumors showed equal or less than 0.90 min^{-1} . Four SPNs that showed k_{ep} of less than 0.90 min^{-1} included a poorly differentiated SCC, two acinar-pattern adenocarcinomas, and a mixed-type adenocarcinoma with 50% acinar component and as little as 10% of solid component. Possibility of more acinar component than solid component in the tumor to result in lower perfusion, thus relatively lower K^{trans} and k_{ep} less than 0.90 min^{-1} may be one explanation; however, many other adenocarcinomas with similar histology also had k_{ep} value of greater than 0.90 min^{-1} . The same was true with SCC. Therefore, we may only be able to assume that these 4 malignant tumors with k_{ep} less than 0.90 min^{-1} happened to have very low vascularity and permeability regardless of their cellular histology. The average size of these tumors was 18.5mm (ranged from 17-21mm). On the other hand, the average size of 21 malignant SPNs with $k_{ep}>0.90 \text{ min}^{-1}$ was 20.4mm (range from 19-28mm), which was larger than the ones with $k_{ep}<0.90 \text{ min}^{-1}$. This size difference may suggest that smaller tumors with fewer tumor vessels may show smaller K^{trans} and $k_{ep}<0.90 \text{ min}^{-1}$. As tumor grows, tumor vessels may develop more and then, K^{trans} and k_{ep} become larger. After all, those 4 malignant SPNs with $k_{ep}<0.90 \text{ min}^{-1}$ could change their pharmacokinetics if they were observed and grew larger in size. One of these 4 malignant tumors demonstrated thin ring enhancement with non-enhancing middle portion on post-contrast T1-weighted images as well as on DCE-MRI, with Type D curve pattern. In a poorly vascularized tumor, it would develop necrosis inside with liable newly growing tumor outside because of its moderate neovascularity to nurture inside portion as it grows. On the other hand, when the tumor is necrotic, pharmacokinetic parameters may not be able to correctly represent histological characteristics. Nonetheless, k_{ep} value may be greatly helpful as a biomarker to diagnose malignant SPNs. Other perfusion indices and pharmacokinetic parameters demonstrated large overlaps in values between malignant and benign SPNs, and their values did not separate histology. Although average K^{trans} value of malignant SPNs was statistically significantly higher ($p=0.02$) than that of benign SPNs, distribution of the values largely overlapped and did not clearly separate the two. **Conclusion:** Pharmacokinetic parameter k_{ep} may be a helpful biomarker to diagnose malignant SPNs. It is a promising factor to non-invasively add important histologic information of an SPN by DCE-MRI, and potentially reduces unnecessary invasive surgical procedures for diagnostic purposes.



References: [1] SEER Cancer Statistics Review 1975-2006 National Cancer Institute. [2] Flehinger BJ, et al. Chest 1992; 101:1013-1018. [3] Schaefer JF, et al. Lung Cancer 2006; 53:39-49. [4] Naish JH, et al. MRM 2009; 61:1507-1514. [5] Tokuda J, et al. JMRI 2010 in press.

*This research is supported by NIH 5R21 CA11627-02.