

Improved susceptibility weighted phase imaging for the assessment of brain iron deposition using a multi-echo sequence

G. Gilbert^{1,2}, G. Savard¹, C. Bard¹, and G. Beaudoin¹

¹Department of Radiology, Centre Hospitalier de l'Université de Montréal, Montreal, QC, Canada, ²MR Clinical Science, Philips Healthcare, Cleveland, OH, United States

Introduction

Susceptibility weighted phase imaging is often used to map brain iron deposition, which is associated with many neurodegenerative diseases [1-2]. Recently, the use of a multi-echo sequence has been proposed as a mean to increase the contrast-to-noise ratio in susceptibility weighted venography [3-4]. However, to our knowledge, the methodology and potential outcomes of this approach have not been studied in the context of iron deposition assessment using phase imaging. Accordingly, the aim of this study is to perform a quantitative comparison between susceptibility weighted phase images obtained from a standard single-echo sequence and equivalent images computed from a multi-echo acquisition.

Materials and Methods

Three healthy volunteers were imaged using a standard 3D gradient-echo sequence (TR = 28 ms, TE = 20 ms, without SENSE, bandwidth = 99.9 Hz/pixel, acq. time = 5:47) and a 3D multi-echo gradient-echo sequence (TR = 46 ms, 5 echoes, TE = 6.7 / 15.2 / 23.7 / 32.2 / 40.7 ms, SENSE = 2, bandwidth = 144.1 Hz/pixel, acq. time = 4:45). All other imaging parameters were identical for both acquisitions ($\alpha = 20^\circ$, FoV = 220 mm x 220 mm x 64 mm, spatial resolution = 0.75 mm x 0.75 mm x 1.5 mm, flow compensation). Both sequences were performed twice, in order to evaluate the local noise contribution by a subtraction of the two acquisitions. All experiments were performed on a clinical 3T system, using an 8-channel head coil for signal reception.

For each acquisition and each echo time, susceptibility weighted phase images were reconstructed using homodyne highpass filtering [5]. For the multi-echo acquisitions, all echoes were combined into a field variation map (ΔB), using a weighted least-squares linear regression to the equation

$$\Delta \phi = -\gamma \Delta B T E \quad (1)$$

where $\Delta \phi$ is the phase variation and γ is the gyromagnetic ratio. Taking into account that the noise in a phase image is inversely proportional to the magnitude of the signal [5], magnitude images for each echo time were used as weights in the regression. In addition, on a voxel by voxel basis, longer echo times that showed residual phase wrap artefacts were excluded from the computation, via a simple masking approach. Single-echo images were also directly converted to ΔB units using equation 1.

Five regions-of-interest (ROIs) that are often involved in iron deposition mechanisms (red nucleus, substantia nigra, globus pallidus, putamen, caudate nucleus) and a reference white matter region were manually segmented. Following registration of all acquisitions, the noise contribution was evaluated locally for each ROI, using a subtraction of the repeated acquisitions.

Results and Discussion

Figure 1 allows for an easy comparison of ΔB maps computed from a single-echo acquisition (a) and a multi-echo acquisition (b). It can visually be assessed that the multi-echo map displays a significantly reduced noise level, while the contrast, in comparison to the single-echo map, is preserved. This last observation is confirmed by the results presented in Figure 2, that show a high correlation between ΔB values computed using the single-echo sequence and equivalent values from the multi-echo sequence. A linear regression slope close to unity is also observed.

The noise reduction allowed by the use of the multi-echo sequence can also be assessed from the results presented in Table 1. It can be observed that the noise standard deviation is decreased for the multi-echo approach for all ROIs. The noise reduction is especially important for ROIs that are located sufficiently away from regions suffering from susceptibility artefacts (mainly from sinuses), such as the putamen and white matter. This effect arises from the fact that all echo times can be used for the computation while, for some subjects, longer echo times have to be masked for ROIs located in the vicinity of susceptibility artefacts (red nucleus, substantia nigra).

Conclusion

The results presented in this abstract illustrate that the use of a multi-echo sequence is an effective way to decrease the noise contribution in susceptibility weighted phase images, while preserving both contrast and acquisition time. In addition, this approach simultaneously allows for the acquisition of phase images and the computation of T2* maps, which is another method commonly used for iron deposition mapping.

References

- [1] Haacke EM et al. *J. Magn. Res. Imag.* 2009; 29 : 537-544. [4] Brainovich V et al. *Magn. Res. Imag.* 2009; 27: 23-37.
 [2] Zhu W-Z et al. *Radiology* 2009; 253 : 497-504. [5] Haacke EM et al. *Magn. Res. Med.* 2004; 52 : 612-618.
 [3] Denk C, Rauscher A. *J. Magn. Res. Imag.* 2010; 31: 185-191.

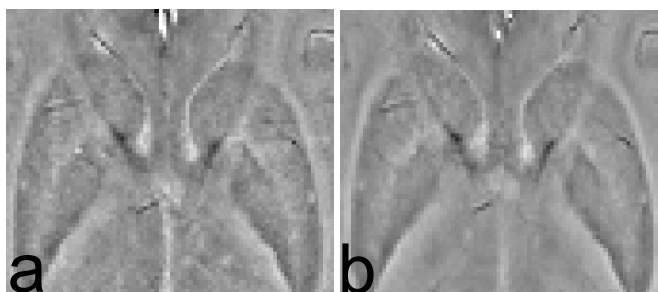


Figure 1 : Representative ΔB maps for a region covering the caudate nucleus, globus pallidus and putamen from (a) a single-echo acquisition and (b) a multi-echo acquisition.

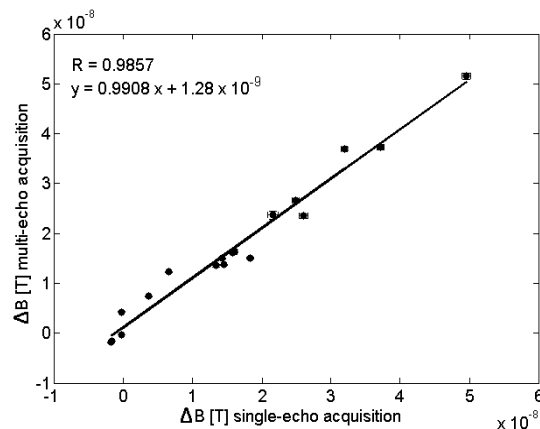


Figure 2 : ΔB values from the multi-echo acquisition as a function of the corresponding values from the single-echo acquisition, for all ROIs and all subjects.

Region-of-interest	Noise standard deviation Mean (Range) [x 10 ⁻⁸ T]		Relative difference Mean (Range) [%]
	Single-echo sequence	Multi-echo sequence	
Red nucleus	2.53 (2.19 3.09)	2.09 (1.53 2.98)	-19.2 (-3.6 -30.1)
Substantia nigra	2.60 (2.20 2.90)	2.33 (1.73 2.73)	-11.3 (-5.9 -21.4)
Globus pallidus	2.65 (2.42 2.97)	1.98 (1.56 2.20)	-25.4 (-14.4 -35.5)
Putamen	2.45 (2.34 2.54)	1.60 (1.45 1.82)	-34.7 (-28.3 -38.0)
Caudate nucleus	2.06 (1.86 2.16)	1.45 (1.40 1.52)	-29.3 (-18.3 -35.2)
White matter	1.11 (1.03 1.21)	0.64 (0.57 0.73)	-42.6 (-39.7 -44.7)

Table 1 : Standard deviation of the noise for all ROIs. A negative relative difference indicates a lower noise level in the multi-echo acquisition, in comparison to the single-echo acquisition.