

MRI Artifacts due to Ingestion of Iron Supplements

J. Stoneburgh¹, A. Fatemi-Ardekani², B. Smith³, and M. D. Noseworthy^{4,5}

¹Electrical and Computer Engineering, McMaster University, Hamilton, Ontario, Canada, ²Medical Physics, McMaster University, Hamilton, Ontario, Canada, ³Department of Diagnostic Imaging, Children's Hospital of Eastern Ontario, Ottawa, Ontario, Canada, ⁴Biomedical Engineering; Electrical and Computer Engineering, McMaster University, Hamilton, Ontario, Canada, ⁵Brain Body Institute, St. Joseph's Healthcare, Hamilton, Ontario, Canada

Introduction

Iron is a crucial mineral in the human body and is used in a variety of metabolic pathways [1]. Different medical conditions require patients to monitor their iron levels [1]. Pregnant women in particular are monitored for iron deficiencies and are often required to take iron supplements [2]. Iron is ferromagnetic and causes rapid MR signal dephasing. If ingested too soon prior to MRI scanning, significant artifacts could result. We describe here how ingestion of a standard iron supplement, too soon before an MRI scan, could result in artifacts. Using steady state imaging (FIESTA) and a magnetic susceptibility balance (MSB) we demonstrate how an undigested iron supplement could significantly alter the local field.

Methods

A woman in her third trimester was scanned for a routine fetal MRI to assess fetal hydrocephalous. Steady state FIESTA images showed classic phase artifacts associated with iron (Fig.1) yet she claimed to have never had surgery or swallowed any known metallic objects. She did admit to taking her daily iron supplement. She was told to return a week later and avoid taking the supplement. The resultant new images were void of metallic artifacts (Fig. 1). To investigate this phenomenon ferrous gluconate (Ferrate) iron supplements (300mg Lot JL8523) embedded in agar (20% w/w) gel phantoms were scanned using a 3T GE Signa HD MRI system and 8 channel phased array head RF coil. Images were acquired using a steady state imaging sequence (FIESTA) as done clinically. Volume magnetic susceptibility (χ , in cgs units, where $H_2O \approx -7.2 \times 10^{-7}$) of the supplement was determined analytically using a magnetic susceptibility balance (MSB; Johnson Matthey, West Chester, PA).

Results and Discussion

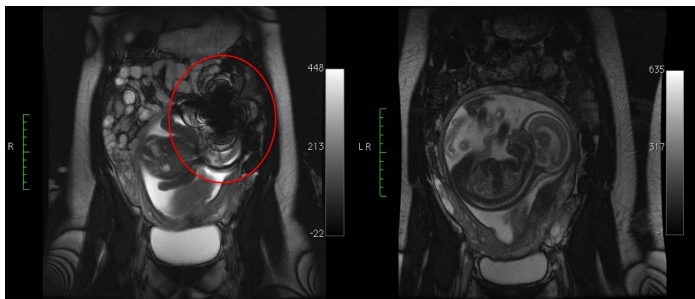
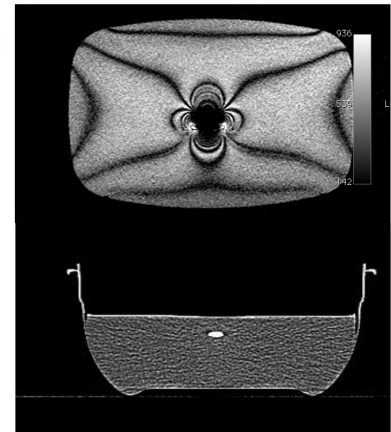


Figure 1. Routine clinical fetal MRI scan to evaluate fetal hydrocephalus. On the left is a steady state sequence (FIESTA) showing a region of metal artifact dephasing (red ellipse). On the right is the same patient one week later.

Figure 2. 3T MRI FIESTA (top) and CT (bottom) scans through gel phantom containing iron supplement. The top image was done with 512x512, TE/TR/flip= 1.5ms/9.5ms/70°, 4mm thick, 20cm FOV, coronal. Clear phase aliasing is seen due to the presence of the paramagnetic iron in the supplement.

Bottom scan. Siemens PET/CT was used to acquire CT images without using the PET portion. Acquisition parameters were: X-ray tube current: 350mA, kVp =120 kV, convolution kernel B60f (bone window), resolution: 2.0 mm³, and reconstruction diameter: 200 mm



MRI of a ferrous gluconate iron supplement depicts a distinctive artifact that obscures magnitude images and generates characteristic phase patterns (Fig.2). No artifacts were produced on a comparable CT of the same ferrous gluconate tablet. Artifacts are due to the susceptibility of iron affecting the local field. Using the MSB analytical determination of ferrous gluconate tablet magnetic susceptibility was found to be 1.22×10^{-5} , which is not ferromagnetic (likely due to the presence of fillers, calcium, and other diamagnetic substances). However, the tablet is still paramagnetic relative to pure water. The undigested iron supplement is likely the cause of the artifact seen in FIESTA images. We did not do any assessment of potential temperature induced changes near the supplement, which may or may not be important. However, with the adverse effect on image quality we suggest patients should be told to avoid iron supplement consumption prior to their MRI examination.

References

[1] Brunner et al. (2010) Ther Umsch. 67:219-223. [2] Banhidly et al. (2010) Nutrition ePub ahead of print.