

The Effect of the Ketogenic Diet on Neuroinflammation in an EAE Mouse Model of Multiple Sclerosis

G. H. Turner¹, D-Y. Kim¹, J. Hao¹, R. Liu¹, J. M. Rho¹, and F-D. Shi¹

¹Barrow Neurological Institute, Phoenix, AZ, United States

Introduction

Dietary treatments have become increasingly used as an alternative therapy to address a variety of neurological disorders. The ketogenic diet (KD) has been shown to promise in both translational studies and in the clinic [1-3]. Attenuation of amyloid beta 40 and 42 deposition was found in Alzheimer's mice fed the KD [1]. The KD was found to reduce pain and inflammation in rats given a hind paw thermal nociception stimulus [2]. In the clinic, a KD diet was shown to be efficacious in the treatment of patients with intractable epilepsy [3]. For this study the effect of the KD on an experimental autoimmune encephalomyelitis (EAE) mouse model of multiple sclerosis was investigated. A combination of in vivo MRI and bioluminescence imaging was used to examine lesion development and measure reactive oxygen species (ROS) in EAE mice given the ketogenic diet.

Methods

C57BL/6 mice (n=5/group) were injected subcutaneously in the hind flank with 200 µg of MOG₃₅₋₅₅ peptide in complete Freund's adjuvant (CFA) (Difco, Detroit, MI, USA) containing 500 µg of non-viable, desiccated Mycobacterium tuberculosis. On the day of and 2 days after immunization, the mice were inoculated with 20 ng of pertussis toxin (List Biologic, Campbell, CA, USA) intraperitoneally. The KD (Bio-Serv F3666 diet; 6:1 ratio of fats:carbohydrate+protein) was initiated 7 days prior to EAE induction and continued until time of sacrifice.

In vivo MRI was performed on a 7 Tesla small-animal scanner (Bruker BioSpin, Billerica, MA). Coronal fat-suppressed T2-weighted images were acquired over the entire brain of each animal (RARE; TE1=14.5 ms, TE2=65.5 ms, TR=4500 ms, 0.5 mm slice thickness, Matrix 256x256, FOV=2.8cm, eight averages, 40 coronal slices, scan time 28 minutes, and 20 axial slices, scan time 28 minutes). For imaging of ROS generation in brain, bioluminescence images in live mice were captured with a 1 min acquisition time using a cooled IVIS imaging system (Xenogen IVIS-200, Alameda, CA) 18 hours after injection of 27 mg/kg DHE (Molecular Probes, Eugene, OR). All experiments were performed 6-10 days post EAE induction.

Results

T2 weighted images show focal lesions located around the ventricles of EAE mice from both groups (Figure 1A). The lesions in mice given KD appeared less prominent with a reduced lesion volume ($7.32 \pm 2.23 \text{ mm}^3$ EAE vs. $2.8 \pm 1.1 \text{ mm}^3$ EAE+KD, $p < 0.05$). Optical imaging revealed a larger ROS signal in normal diet EAE mice than those fed KD (Figure 1B). Quantification of ROS signal showed significantly reduced ROS in KD EAE mice vs. EAE mice on normal diet ($1.83 \pm 0.42 \text{ p/s/cm}^2$ EAE vs. $0.76 \pm 0.25 \text{ p/s/cm}^2$ EAE+KD, $P < 0.01$).

Conclusion

These studies revealed that the use of a ketogenic diet yields a reduction of the inflammatory response in an EAE model of multiple sclerosis. Further investigation is required to determine the clinical manifestation of these effects and what are the underlying specific mechanisms that result in the KD-mediated neuroprotection in this model.

References

1. Van der Auwera et al., *Nutr Metab*, 2005
2. Ruskin D, et al., *PloS One*, 2009
3. Neal EG, et al., *Lancet Neurol*, 2008

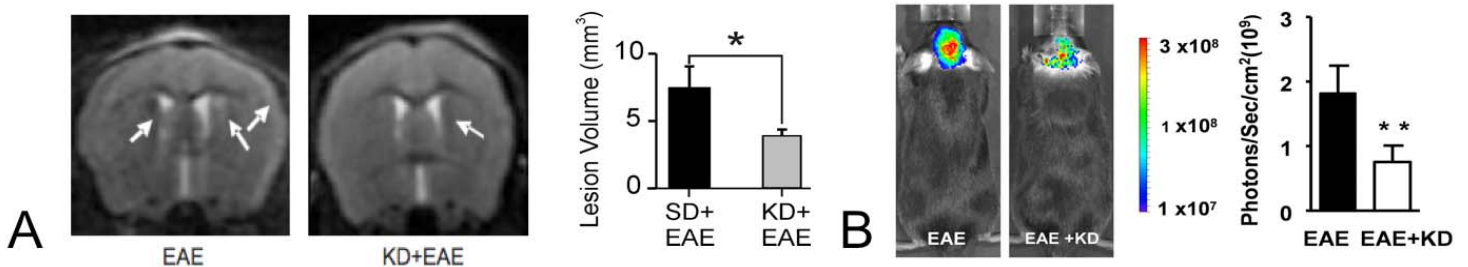


Figure 1. A) Example of image of periventricular lesions in EAE mice given normal and ketogenic diet. A significant reduction in lesion volume due to KD was found. B) ROS signal in EAE mice given normal and ketogenic diet. A significant difference in ROS was found ($p < 0.01$).