

# Quantitative R2' mapping to investigate the relationship of brain iron deposition and cognitive impairment in Alzheimer disease

W. Zhu<sup>1</sup>, and L. Zhao<sup>2</sup>

<sup>1</sup>Department of Radiology, Tongji Hospital, Tongji Medical College, Wuhan, Hubei Province, China, People's Republic of,

<sup>2</sup>Department of Radiology, Tongji Hospital, Tongji Medical College

**Introduction:** Quantitative MRI measurement of regional brain iron deposition may help with diagnosis and assessment of disease progression in Alzheimer disease (AD). The most frequently used technique is relaxation rate mapping, it is suggested that R2' is a stronger and more accurate means to map brain iron content than R2\* and R2 (R2'=R2\*-R2) [1-4]. The aim of this study was to investigate the correlation of brain iron accumulation with the severity of cognitive impairment in AD patients by using R2' mapping.

**Materials and Methods:** Fifteen AD patients, 15 age- and sex-matched healthy controls, and 30 normal adults underwent multi-echo T2 and T2\* mapping for R2' measurement on 1.5T MR scanner. The regional R2' values in 30 normal adults were used to calibrate the relationship between regional R2' values and corresponding brain iron concentration histologically [5]. The AD group was divided into the mild (MMSE > 10, n=8) and severe AD group (MMSE ≤ 10, n=7). R2' and iron concentrations of multiple ROIs in AD patients and controls were determined and compared with each other. The relative ratio of MMSE (rMMSE) was used as an index to evaluate the severity of cognitive impairment. The correlation of brain iron accumulation with the severity of cognitive impairment in AD patients was analyzed statistically.

**Results:** The regional R2' has been demonstrated to be positively correlated with published brain iron concentration histologically [5] in normal adults (Fig1). R2' values in bilateral hippocampus (HP), parietal cortex (PC), putamen (PU), caudate nucleus (CN) and dentate nucleus (DN) of AD patients were significantly higher than controls ( $p < 0.05$ ), but no significant difference in bilateral substantia nigra (SN), red nucleus (RN), thalamus (TH) and frontal white matter (FWM) between two groups ( $p > 0.05$ ). Furthermore, R2' of bilateral HP and PC in severe AD group was significantly higher than the control and mild AD groups, and also significantly higher in mild group than controls ( $p < 0.05$ , Fig2). R2' and iron concentration measured in bilateral PC and HP in AD group were negatively correlated with rMMSE ( $p < 0.05$ , Fig3-4) and so they were positively correlated with the severity of patients' cognitive impairment.

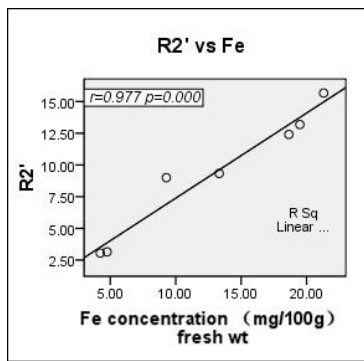


Fig1

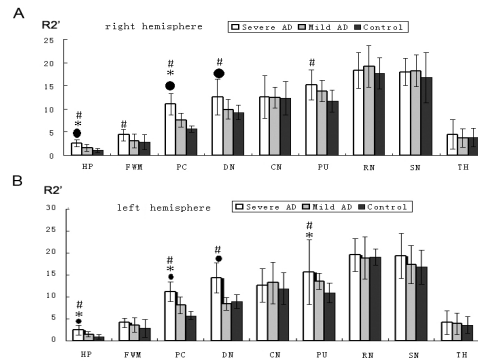


Fig2

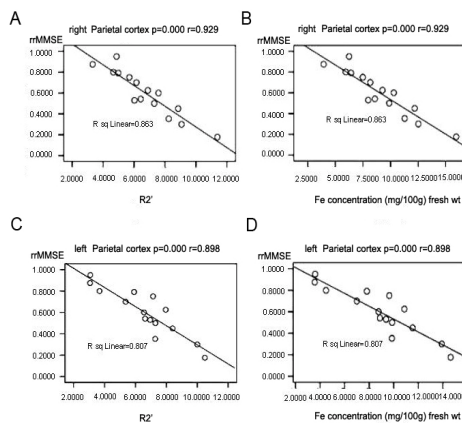


Fig3

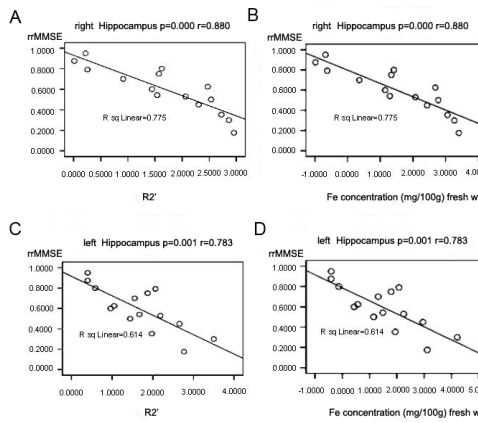


Fig4

**Conclusion:** R2' mapping is sensitive to detect increased iron deposition in AD patients. R2' and iron concentration measured in the bilateral PC and HP was positively correlated with the severity of dementia in AD patients, indicating that R2' can be used as an imaging marker to evaluate AD progression.

**References:** 1. Langkammer, et al. Radiology.2010; 257:455. 2. Ordidge et al. Magn Reson Med 1994; 32:335. 3. Gelman et al. Radiology 1999;210:759. 4. Wallis et al. JMRI 2008;28:1061. 5. Hallgren. J Neurochem: 1958.3:41.