

A diffusion kurtosis imaging (DKI) based correlate for plaque load in the APPPS1 mouse model for Alzheimer's disease (AD)

G. Vanhoutte¹, S. Pereson², B. Asselbergh², C. Van Broeckhoven², and A-M. Van der Linden¹

¹Biomedical Sciences, Bio-Imaging Lab, University of Antwerp, Antwerp, Antwerp, Belgium, ²Molecular Genetics, VIB and Institute Born-Bunge, University of Antwerp, Antwerp, Antwerp, Belgium

Introduction and aim: *In vivo* detection of the amyloid deposits in the brain would be beneficial in terms of AD diagnosis and therapy follow-up. Since previous studies could show different *ex vivo* patterns for mean kurtosis in an APPPS1 mouse model, we hypothesize that the microstructural changes in the brain, due to extracellular amyloid deposits, can be measured *in vivo* as well by diffusion kurtosis imaging (DKI)(1). Therefore we investigated the sensitivity of DKI to detect amyloid burden, in transgenic mouse models for AD.

We chose to use APPPS1 mice because of their effective brain amyloidosis without the occurrence of neurodegeneration, tau-pathology or behavioural changes. The DKI experiments were set up as a feasibility study using aged APPPS1 mice between 15-16months manifesting massive amyloid burden throughout the whole brain (2). We investigated the neocortical and hippocampal regions linked with the cognitive impairment in AD and other associated regions such as striatum, thalamus and bulbus olfactorius (BO).

Methods: DKI was conducted on a 9.4T MR system (Bruker Biospec, Ettlingen Germany) on a group of APP_(swe)-PS1_(L166P) and a control group WT mice between 15 and 16months (n_{group}=5). Mice were anaesthetized using isoflurane (1,5-2%) and monitored to maintain constant physiological parameters. The DKI protocol included the use of 7 b₀-values and 30 gradient directions with 7 b-values (400, 800, 1200, 1600, 2000, 2400 and 2800s/mm²). Images were collected with a multi-slice SE 2-shot EPI sequence (TR/TE=7500/24ms, δ=5ms, Δ=12ms, acquisition matrix=96*64, zero filled to 128*64, spatial resolution:150*200*500μm³, NEX=4). Diffusion kurtosis tensor and diffusion tensor derived parametric maps were computed (Matlab). These include the mean kurtosis (MK), radial kurtosis (RK), axial kurtosis (AK), fractional kurtosis anisotropy (KA), fractional anisotropy (FA), mean diffusivity (MD), axial and radial diffusion (AD, RD) parametric maps. Regions of interest were delineated based on grey values of FA, MD and magnitude maps in AMIRA (Mercury Computer systems, San Diego, USA). Differences of diffusion parameters between WT and APPPS1 mice were computed by means of the Mann-Whitney non-parametric statistical test in SPSS 16.0 (SPSS Inc. Chicago, USA). To exclude contribution of neurodegeneration at 15-16m, we also checked brain volumes of the old group.

Results: Figure 1 shows some representative parameter maps (at the level of the dorsal hippocampus) obtained through DKI and the table summarizes the observed increases in green and decreases in red (p<0.05): MK, AK, and RK were significantly increased in the cortex and striatum of APPPS1 mice as compared to the WT mice. For the hippocampus and the thalamus only RK values were significantly increased in APPPS1 mice compared to WT mice. DTI derived parameters showed significant decreases for AD in the striatum and AD and MD in the bulbus olfactorius. Figure 2 shows the volume per brain slice in graph style from Bregma 3mm to Bregma -5mm, covering the part of the brain with severe amyloidosis. No volume differences were encountered.

FIGURE 1

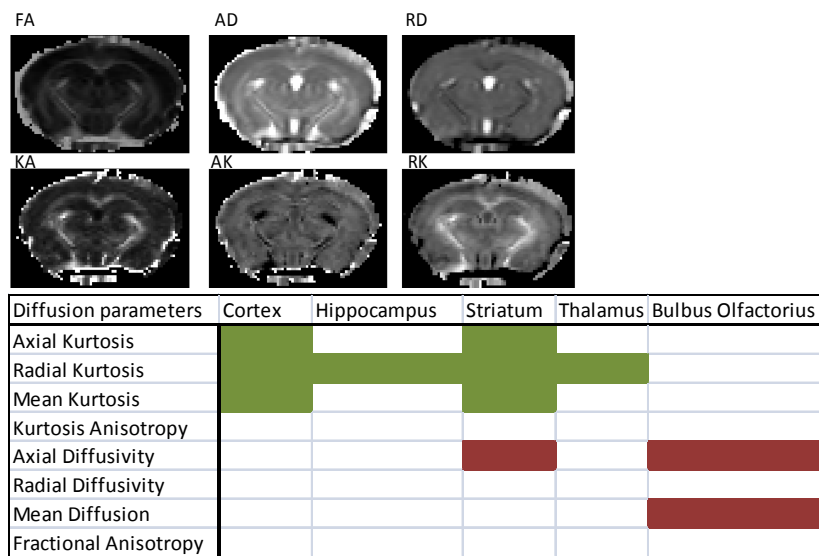
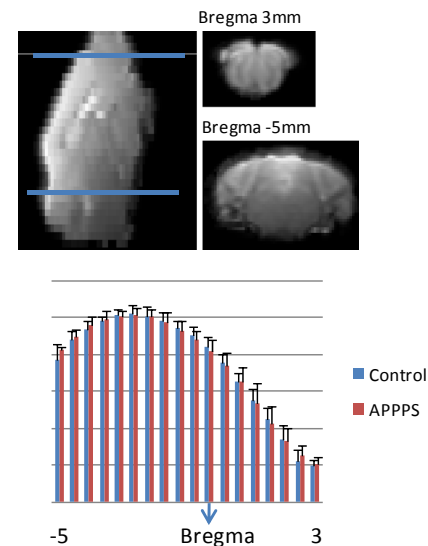


FIGURE 2



Conclusions and prospects: Our results reinforce the hypothesis that DKI is a more sensitive technique than its predecessor diffusion tensor imaging (3;4). Increased kurtosis values in APPPS1 mice occurs in regions stuffed with amyloid. The higher complexity of the microstructure is a result of the presence of amyloid leading to a higher number of diffusion barriers. Only for the striatum, also decreased diffusivity is present. The BO is known to be affected in AD (5), does not manifest the amyloid pathology severely (2) but yet, diffusion is decreased. Because the BO is a laminated structure, the source of this change is not inconceivable, yet to be elucidated.

Previous *ex vivo* DKI scans of the same APPPS1 mouse model solely reported similar MK changes (1). Here we show that the application of DKI *in vivo* drives the observations towards a better characterization of brain tissue pathology. However, validation of the link between the presence of amyloid and changes in kurtosis is still needed and will be achieved through immunohistochemical staining of all mice (n=10) on an individual base. This processing is currently ongoing. Other potential contributing factors to DKI changes such as neurodegeneration could already be excluded by our imaging data set.

References: 1) Falangola MF et al., (2007). Proc. Intl. Soc. Mag. Reson. Med.; 2) Radde R et al., (2006). EMBO Rep., 7(9):940-6. 3) Hui ES et al., (2008). Neuroimage, 1;42(1):122-34.; 4) Jensen JH et al., (2005). Magn. Reson. Med., 53(6):1432-40. 5) Fusari A et al., (2009). Rev.Neurol. 49(7):363-9