

## Myocardial ASL perfusion reserve test detects angiographic CAD in initial cohort of 29 patients

Z. Zun<sup>1</sup>, T. Jao<sup>1</sup>, P. Varadarajan<sup>2</sup>, R. G. Pai<sup>2</sup>, E. C. Wong<sup>3</sup>, and K. S. Nayak<sup>1</sup>

<sup>1</sup>Department of Electrical Engineering, University of Southern California, Los Angeles, CA, United States, <sup>2</sup>Division of Cardiology, Loma Linda University Medical Center, Loma Linda, CA, United States, <sup>3</sup>Departments of Radiology and Psychiatry, University of California, San Diego, La Jolla, CA, United States

### INTRODUCTION

Arterial spin labeling (ASL) is a promising technique for the assessment of myocardial blood flow (MBF) without contrast agents. It can be safely applied to patients with end-stage renal disease who cannot tolerate traditional first-pass imaging. Myocardial ASL perfusion imaging performed at rest and during stress provides perfusion reserve ( $MBF_{\text{stress}}/MBF_{\text{rest}}$ ), a useful indicator for the severity of coronary artery disease (CAD) [1]. We performed rest-stress myocardial ASL in patients with suspected CAD, estimated regional perfusion reserve, and compared results with X-ray angiography.

### METHODS

Twenty-nine CAD-suspected patients (aged  $64 \pm 11$ ) were recruited from those scheduled for routine rest-stress cardiac MR. Myocardial ASL was performed at a single mid short-axis slice at rest and during adenosine infusion (dosage: 0.14 mg/kg/min) on a GE Signa HDx 3T scanner. The ASL sequence was composed of flow-sensitive alternating inversion recovery (FAIR) tagging and balanced steady-state free precession (SSFP) imaging as described in Ref. [2]. Regional perfusion reserve values were obtained in six myocardial segments (anterior, anteroseptal, inferoseptal, inferior, inferolateral, and anterolateral walls) [3]. Perfusion reserve maps with finer angular resolution were generated in a standard polar format by resampling the ASL data followed by spatio-temporal filtering to improve signal-to-noise ratio [4]. All patients underwent rest-stress first-pass perfusion imaging after myocardial ASL, and patients who showed perfusion defects on first-pass MRI underwent X-ray angiography.

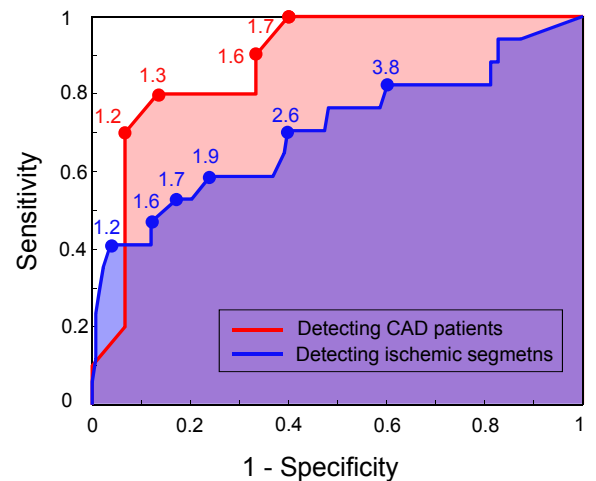
### RESULTS

Fifteen of the twenty-nine patients were found to be normal based on having no visible perfusion defect on first-pass MRI. Ten patients had perfusion defect on first-pass MRI and  $\geq 80\%$  stenosis on coronary angiography. Four remaining patients showed perfusion defects but no significant stenosis, and were excluded from this analysis to avoid confounding impact of microvascular/unresolved disease. Based on X-ray angiography, the most ischemic myocardial segments in each patient were identified by two experienced cardiologists. With these segments as a reference, receiver operating characteristic (ROC) curves for regional perfusion reserve from myocardial ASL were generated for detection of patients with angiographic CAD, and for detection of the most ischemic segments (see Figure 1). The area under ROC curve (AUC) was 0.88 for detection of angiographic CAD and 0.71 for detection of the most ischemic segments. The cardiologists then identified myocardial segments that were likely ischemic based only on ASL perfusion reserve maps (see Figure 2), blinded to patient information and other test results. Their threshold of perfusion reserve corresponded to 1.6 approximately, leading to sensitivity/specificity of 90%/67% for detecting patients with angiographic CAD, and 47%/88% for detecting the most ischemic segments.

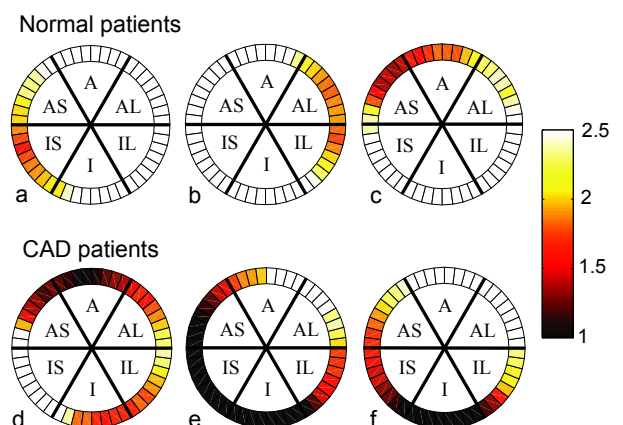
### DISCUSSION

We demonstrate that myocardial ASL has a potential for diagnosing angiographically significant CAD. ROC analysis indicates that myocardial ASL shows better performance for detecting CAD patients than localizing ischemic segments within each patient. This suggests that myocardial ASL may be used as a screening tool to differentiate patients who need further CAD tests such as X-ray angiography.

**REFERENCES** [1] Wacker CM *et al*, JMRI 18: 555, 2003. [2] Zun Z *et al*, MRM 62: 975, 2009. [3] Cerqueira MD *et al*, Circulation 105: 539, 2002. [4] Jao T *et al*, ISMRM 2011 (submitted).



**Figure 1.** ROC curves for ASL-based myocardial perfusion reserve. Perfusion reserve threshold values are specified for the bullet points. The area under ROC curves were 0.88 (red) for detection of patients with CAD and 0.71 (blue) for detection of the most ischemic segments.



**Figure 2.** Representative perfusion reserve maps (A: anterior, AS: anteroseptal, IS: inferoseptal, I: inferior, IL: inferolateral, AL: anterolateral). **a - c:** normal by first-pass MRI. **d - f:** defects on first-pass MRI and angiographic CAD. Patients **d**, **e**, and **f** have 100% occlusions of LAD, RCA, and RCA, respectively.