

# Quiescent-Interval Single-Shot Unenhanced Magnetic Resonance Angiography featuring Continuous Table Movement

M. O. Zenge<sup>1</sup>, C. Glielmi<sup>2</sup>, P. Weale<sup>2</sup>, I. Koktzoglou<sup>3</sup>, R. R. Edelman<sup>3</sup>, M. Rick<sup>1</sup>, P. Schmitt<sup>1</sup>, and X. Bi<sup>2</sup>

<sup>1</sup>MR Applications Development, Siemens AG, Erlangen, Germany, <sup>2</sup>Cardiovascular MR R&D, Siemens Healthcare, Chicago, IL, United States, <sup>3</sup>Department of Radiology, NorthShore University HealthSystem, Evanston, IL, United States

## INTRODUCTION

Most recently, quiescent-interval single-shot (QISS) peripheral MRA [1] has been introduced as a fast and robust alternative to unenhanced MRA methods such as two-dimensional time of flight [2] and fresh blood imaging [3]. Being a single-shot technique, QISS is relatively robust in the presence of respiratory and bowel motion. The method, furthermore, is widely independent of the arterial peak flow velocity. Thus, individual adaptation of the data acquisition protocol is not required for the majority of subjects. However, like any other multi-step MR imaging method, QISS suffers from signal discontinuities between adjacent sub-sets of images in coronal reformats of the longitudinally extended FOV. Last, but not least, the shimming procedure for up to thirteen stationary acquisitions adds significantly to the total in-room time of each patient. Continuously moving table MRI potentially overcomes both limitations [4]. This family of methods provides a seamlessly extended FOV and adjustments and shimming can be performed on the fly. In addition, scan planning is simplified with the moving table approach. In the current work, continuously moving table capabilities were introduced to a recent implementation of QISS peripheral MRA. The method was evaluated in comparison to the stationary approach in five healthy volunteers with respect to the overall image quality and the total acquisition time.

## METHODS

A recent implementation of QISS features an ECG triggered two-dimensional balanced steady-state free precession pulse (b-SSFP) sequence using a 90° slice selective saturation pulse and a subsequent 90° tracking saturation pulse for venous suppression. After a time interval of 350 ms, a fat saturation module is played out, followed by an  $\alpha/2$  pulse preparation and subsequent slice selective b-SSFP data acquisition. This method was extended to enable continuous table movement. The table velocity was defined as the slice thickness over the individual average length of the RR interval plus a temporal margin which results in slightly overlapping slices.

A conventional multi-step QISS protocol for peripheral MRA was compared to a continuously moving table protocol in 5 healthy volunteers. All experiments were performed on a clinical 1.5T MRI scanner (MAGNETOM Espree, Siemens AG, Healthcare Sector, Erlangen, Germany). Besides the inclusion of the moving table strategy parameters, the imaging protocols were identical in both cases: FOV 400 x 260 mm, pixel size 1.0 x 1.0 mm, slice thickness 3.0 mm, no slice overlap, total longitudinal coverage 1400 mm, TR/TE 3.0 / 1.5 ms, shot duration 721 ms, Bandwidth 736 Hz/Px, partial Fourier 5/8, parallel imaging GRAPPA effective acceleration 1.8. In case of the multi-step approach, a total of 416 slices was grouped in 13 sub-sets which were placed around the isocenter of the magnet. Adjustments and shimming were performed for each station individually. In case of continuously moving table acquisitions, each single slice was placed right in the isocenter of the magnet. During data acquisition the patient table moved continuously through the magnet with a table velocity of  $5.0 \pm 0.2$  mm/s dependent of the individual heart rate. Adjustments and shimming parameters were acquired with a FastView (Siemens AG, Healthcare Sector, Erlangen, Germany) localizer once at the beginning of the examination and were updated automatically during the moving table QISS examination. The overall image quality of both methods was evaluated in side-by-side comparison. In addition, the time for the whole examination was compared for both methods.

## RESULTS

QISS peripheral MRA was successful in all cases with the multi-step approach as well as with the new continuously moving table data acquisition. Although the performance of the fat saturation during continuous table movement was slightly inferior compared to the multi-step approach, the aorta, aorto-iliac, femoral and popliteal arteries were well depicted in both methods, similarly both exhibited some variability in the accuracy of depiction of the origin of the anterior tibial artery in subjects where the course of the vessel was very horizontal but neither method was demonstrably worse in this respect (Fig. 1). In coronal reformats (Fig. 2) slight artifacts at the boundary of sub-sets of images in the multi-step data were avoided in the continuously acquired data.

With the conventional multi step approach, adjustments and shimming added 50 seconds to the 32 RR intervals required for each of the 13 steps resulting in total scan time of 17 minutes and 46 seconds, assuming an average RR interval of 1 second. With the same assumptions for the moving table method, all adjustments are achieved within the FastView scan which adds 70 seconds to the exam time but with savings of 9 minutes and 40 seconds during the collection of the QISS data.

## DISCUSSION AND CONCLUSIONS

Continuously moving table QISS is an efficient alternative to the conventional multi-step approach. While maintaining comparable image quality, this approach also avoids signal discontinuities at junctions between sub-sets of data. In addition, the complexity of the whole examination is significantly reduced which is not only reflected in the accelerated adjustment and shimming procedure. In the current implementation, however, these advantages were traded off with a slightly reduced performance of the fat saturation. In cases of heart rate variability, the fixed table velocity may result in some variability in slice spacing / overlap. Although defining a constant table velocity relative to the average heart rate and taking a slight slice overlap into account seems to be sufficient for small variations of the heart rate, an update of the table velocity in real-time seems to be a feasible improvement in the future. In conclusion, the stability and image quality achieved justifies further evaluation in patients.

## REFERENCES:

1. Edelman RR et al. ; Magn Res Med 2010 ; 63:951-958
2. Owen RS et al. ; N Engl J Med 1992 ; 326:1577-1581
3. Miyazaki M et al. ; Radiology 2003 ; 227:890-896
4. Börnert P, Aldefeld B ; J Magn Reson Imaging 2008 ; 28(1) :1-12

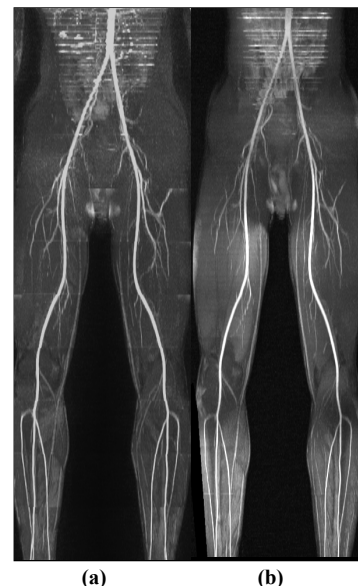


Fig. 1: Coronal MIPs of a multi-step QISS dataset (a) and data acquired during continuous table movement (b). In both cases, the major arteries can be tracked down to fine structures.

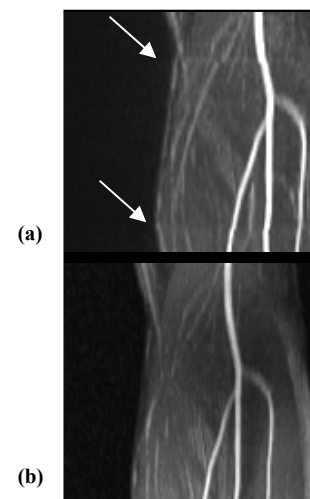


Fig. 2: Zoomed representation of the coronal MIPs of a multi-step QISS dataset (a) and data acquired during continuous table movement (b). Notice: Boundary artifacts at successive stations are avoided with continuously moving table data acquisition.