

## Early response assessment treatment in metastatic prostate cancer to the bone using diffusion mri.

J.-C. Brisset<sup>1</sup>, S. Galbán<sup>2</sup>, A. Rehemtulla<sup>2</sup>, K. J. Pienta<sup>3</sup>, C. J. Galbán<sup>1</sup>, and B. D. Ross<sup>1</sup>

<sup>1</sup>Radiology, University of Michigan, Ann Arbor, Michigan, United States, <sup>2</sup>Department of Radiation Oncology, University of Michigan, Ann Arbor, Michigan, United States, <sup>3</sup>Department of Internal Medicine and Urology, University of Michigan, Ann Arbor, Michigan, United States

**Purpose:** Bone metastases occur in more than 90% of patients with advanced prostate cancer<sup>1</sup>. This study aims to develop an imaging biomarker which will provide for a new vision of how bone cancer therapies are administrated and a foundation to develop the technology for monitoring a patients' individual therapeutic progress dynamically over time<sup>2, 3</sup>. Diffusion-weighted MRI (DW-MRI) is highly sensitive to microscopic changes in tumor tissue. Our goal is to use DW-MRI to detect and quantify changes in tumor tissue throughout therapy where the magnitude of the change could be related to the effectiveness of the treatment.

**Materials and Methods:** Human prostate cancer (PC3) cells were implanted by direct intra-tibial injection into male SCID mice, which was served as a model for prostate bone metastases<sup>2</sup>. MRI experiments were performed on a 9.4T horizontal bore magnet using a quadrature 20 mm volume coil with the leg securely fastened within the coil to reduce motion. Upon identifying by MRI a tumor volume  $\sim 10\text{mm}^3$ , animals were randomly distributed into 4 treatment groups: docetaxel 20 mg/kg i.p. dose once a week for 3 doses (qd7x3; N=5), fractionated radiation IR at 2 Gy/day 5x per week for 2 weeks (N=7), combined treatment (N=5) and controls (N=6). Animals were imaged by DW-MRI using the following sequence: spin-echo, TR/TE 4000/37, Fov 20x20mm<sup>2</sup>, b-values 120-1200 s/mm<sup>2</sup>, slices thickness 0.5mm and 40 slices. Tumor volume and cellularity were monitored using the low-b T2-weighted image and the apparent diffusion coefficient (ADC), respectively. ADC values for each voxel were calculated analytically using the two diffusion-weighted images. Tumor volume and ADC measurements were acquired pre-treatment and on days 1, and 7 post-treatment initiation and every subsequent week. Percent change in tumor volume and ADC were plotted as a function of time. Animals were removed from the study when the tumor reached a percent increase of 400% (5x the initial tumor volume). Group comparisons in MRI metrics were obtained using an unpaired *Student t*-test.

**Results:** In Fig 1, the mice treated by Dox or IR had significant smaller change in tumor volume compared to control mice. Combined treatment resulted in improved efficacy over lone therapies. This resulted in a significant decrease in tumor size. As seen in Fig 2, the Dox group showed an increase in ADC following the first administration and a slow decline in ADC values following day 4 post-treatment initiation regardless of additional treatments. ADC value for IR treated animals did not elevate above control until day 7. Combined treatment generated increased ADC values that were maintained throughout the treatment cycle.

### **Conclusion:**

IR and Dox alone and in combination were effective as assessed by anatomical and DW-MRI. Those results demonstrate the potential of quantitative ADC map for assessing tumor response even at the early time post therapy.

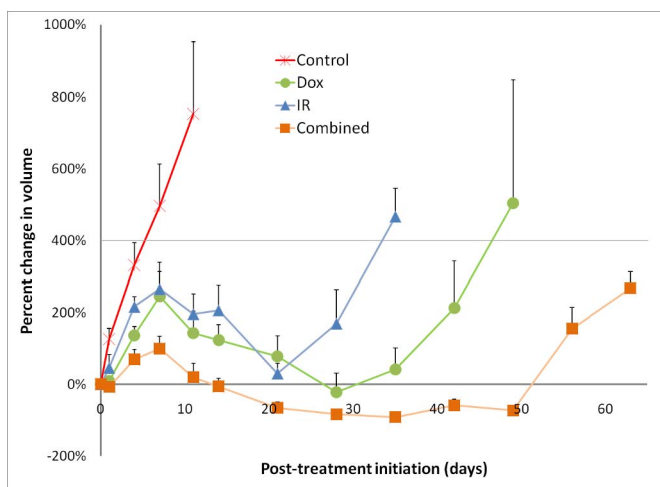


Fig 1: Evolution of the percentage change evolution in tumor volume. Mean +SE;  $p < 0.05$  reached at D1 for Dox and combined group and D7 for IR group.

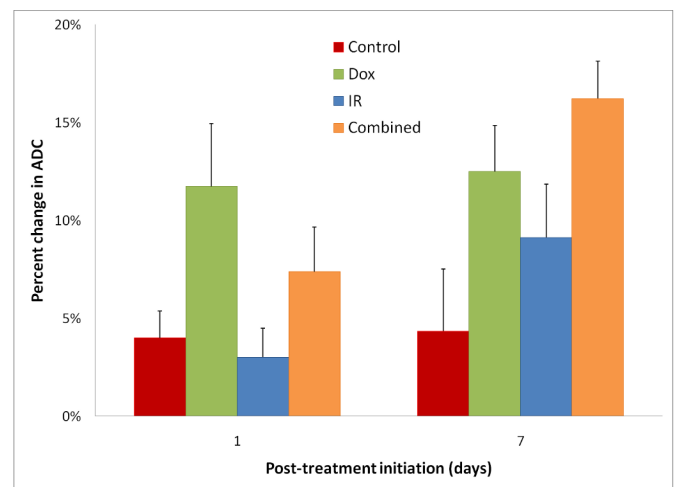


Fig 2: Evolution of the percentage change evolution in ADC. Mean +SE  $p < 0.05$  reached after D7 for Dox and for combined therapy compared to control.

### **References:**

1. Carlini BI et al. *Cancer*. 2000;88(12):2989-2994. 2. Lee KC et al. *Cancer Res*. 2007;67(8):3524-3528. 3. Lee KC *Neoplasia*. 2007;9(12):1003-1011.