

Optimization of Combined Bevacizumab Plus Temozolomide Therapy in Brain Tumor Xenograft Models Using MRI Measures of Relative Cerebral Blood Volume

K. R. Pechman^{1,2}, D. L. Donohoe^{2,3}, D. P. Bedekar^{2,3}, and K. M. Schmainda^{2,4}

¹Neurosurgery, Medical College of Wisconsin, Milwaukee, WI, United States, ²Translational Brain Tumor Research Program, Medical College of Wisconsin, Milwaukee, WI, United States, ³Radiology, Medical College of Wisconsin, Milwaukee, WI, United States, ⁴Radiology and Biophysics, Medical College of Wisconsin, Milwaukee, WI, United States

Introduction: The anti-angiogenic drug bevacizumab has recently been approved by the US Food and Drug Administration for the treatment of recurrent glioblastoma multiforme, the most common and most aggressive primary brain tumor. Frequently, bevacizumab is combined with a chemotherapeutics, an approach motivated by studies that showed improved clinical outcomes compared to historical controls¹. However, no systematic studies have been performed to determine if and how these drugs should be combined for optimal therapeutic response. Furthermore, it is becoming increasingly clear that standard MRI measures of response, which entail measuring contrast-enhanced tumor volume, have proven unreliable for the evaluation of anti-angiogenic drugs since these drugs also decrease contrast extravasation. Consequently, the goal of this study was to demonstrate the utility of using rCBV (relative cerebral blood volume), derived from DSC imaging, to evaluate and optimize the combination of bevacizumab and temozolomide in the treatment of a U87 xenograft brain tumor model.

Methods: *Animal Model:* U87 human grade III astrocytoma cells were cultured, harvested, and 200,000 cells were injected into athymic rats (n=37) using intracranial, stereotaxic approach. B20 (Genentech, South San Francisco, CA) was given at day 10 and 14 (5 mg/kg) post-tumor cell inoculation and combined with daily temozolomide (75 mg/m²) (Temodar, Schering, Kenilworth, NJ) administration beginning at days 8, 12 and 14 or alone at day 10. Imaging was performed on days 10, 12, 14, and 16. *MRI:* Images were obtained on a Bruker 9.4 T scanner fitted with a linear transmit coil, and surface receive coil. A loading dose of contrast agent (0.1 mmol/kg Omniscan, Nycomed Amersham) was administered to minimize leakage effects that confound rCBV measurements derived from DSC-MRI. DSC images were acquired using an EPI sequence (TE/TR=18ms/1s, FOV=3.5cm, matrix=96). Post contrast T1 weighted images were acquired using a spin-echo T1-weighted RARE sequence (TE/TR = 12.6ms/1500ms, FOV =3.5cm, matrix =256).

Figure 1: Tumor Volume

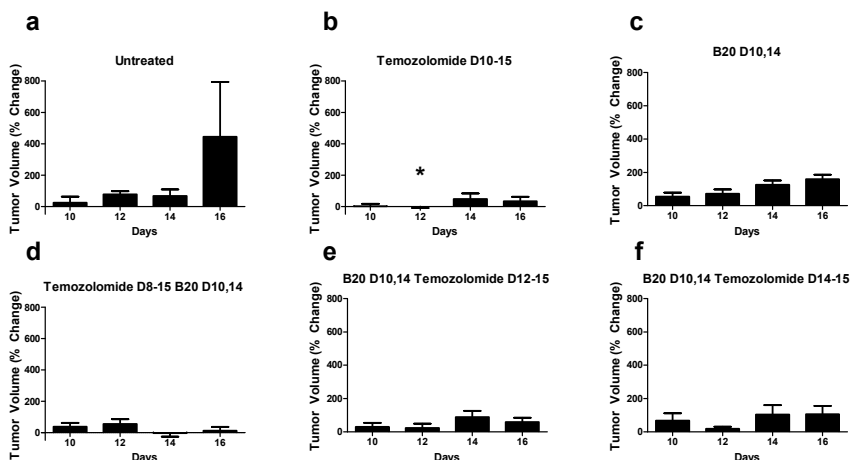
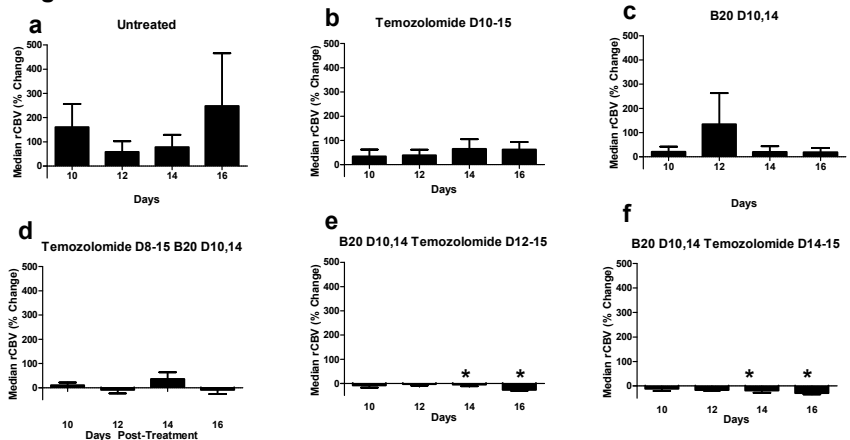


Figure 2: rCBV



general these results demonstrate that the temporal combinations of drugs do influence treatment efficacy and that rCBV alone or in combination with measures of tumor volume may prove useful in optimizing these combinations. **Acknowledgements:** NIH/NCI RO1 CA082500, Advancing Healthier Wisconsin / MCW Translational Brain Tumor Program **References** (1) Zuniga RM et al. J Neuro-Onc 2009; 97:950-951. (2) Schmainda KM et al. Am J Neurorad 2004; 25:1524-1532.

Analysis: The DSC data was processed to create rCBV maps, corrected for any leakage effects². Enhancing tumor volumes (reported in mm³) were determined from the post-contrast T1w images, in all slices showing enhancing tumor. A two-tailed Mann-Whitney test was used to determine if significant differences existed between the untreated group and each of the treated groups at each post-treatment day. An $\alpha=0.05$ level of significance was used.

Results: Figure 1 shows enhancing tumor volume as a function of four treatment days for each treatment paradigm. Temozolomide treatment starting at Day 10 (Fig 1b) inhibited tumor growth on day 12 compared to untreated controls (Fig 1a). Figure 2 shows the median rCBV as a function of four treatment days for the different treatment paradigms. Treatment with either temozolomide (Fig 2b) or B20 alone (Fig 2c) shows an inhibition of angiogenesis compared to the control (untreated) case (Fig 2a). However, in cases for which temozolomide is started 2 or 4 days after treatment with B20 (Fig 2e,f) there is a significant inhibition of tumor angiogenesis compared to the untreated.

Discussion: The degree of tumor vascularity in the U87MG xenograft model depends on the timing of the temozolomide and B20 therapies. Specifically, temozolomide started 2 or 4 days after B20 resulted in the maximal decrease in tumor rCBV. Interestingly, inhibition of tumor volume demonstrated different trends from tumor vascularity. Which trend is more predictive of the optimal response needs further exploration and validation. For the imaging studies included here tissue makers of tumor cell density, proliferation (Ki67) and vascular density (vWF) are being analyzed to provide additional insight as to why rCBV and tumor volume differ in this regard. In