

Timing of Anti-Angiogenic Therapy in Brain Tumors Using MRI Measures of Relative Cerebral Blood Volume and Apparent Diffusion Coefficient

K. R. Pechman^{1,2}, D. L. Donohoe^{2,3}, D. Bedekar^{2,3}, and K. M. Schmainda^{2,4}

¹Neurosurgery, Medical College of Wisconsin, Milwaukee, WI, United States, ²Translational Brain Tumor Research Program, Medical College of Wisconsin, Milwaukee, WI, United States, ³Radiology, Medical College of Wisconsin, Milwaukee, WI, United States, ⁴Radiology and Biophysics, Medical College of Wisconsin, Milwaukee, WI, United States

Introduction: The anti-angiogenic drug bevacizumab has recently been approved by the US Food and Drug Administration for the treatment of recurrent glioblastoma multiforme, the most common and most aggressive primary brain tumor. However, few studies have been performed to evaluate if treatment efficacy is altered when given in later stages of tumor growth. Furthermore, it is becoming increasingly clear that standard MRI measures of response, which entail measuring contrast-enhanced tumor volume, are insufficient for the evaluation of anti-angiogenic drugs since these drugs also decrease contrast extravasation. Consequently, the goal of this study was to determine if tumor response is influenced by the timing of bevacizumab therapy with measurements of apparent diffusion coefficient (ADC) and relative cerebral blood volume (rCBV) using dynamic susceptibility contrast (DSC) imaging.

Methods: *Animal Model:* U87 human grade III astrocytoma cells were cultured, harvested, and 200,000 cells were injected into athymic rats (n=18) using intracranial, stereotaxic approach. Bevacizumab (Avastin, Genentech, South San Francisco, CA), was given at day 10 (5 mg/kg) or at day 16. Imaging was performed on days 10, 12, 14, and 16 in rats treated at day 10. Imaging was performed on days 16, 18, and 24 in rats treated at day 16. ***MRI:*** Images were obtained on a Bruker 9.4 T scanner fitted with a linear transmit coil, and surface receive coil. For diffusion, images were acquired using an EPI sequence (TE/TR=12.6/6000ms, FOV=3.5cm, matrix=512, b=0 and 1000). Prior to acquiring DSC images a preload of contrast agent was administered to diminish any confounding leakage effects. Next, DSC images were acquired, during the administration of 0.1 mmole/kg of Gd contrast agent, using an EPI sequence (TE/TR=18ms/1s, FOV=3.5cm, matrix=96). Post contrast T1 weighted images were acquired using a spin-echo T1-weighted RARE sequence (TE/TR = 12.6ms/1500ms, FOV = 3.5cm, matrix = 256).

Analysis: The DSC data was processed to create rCBV maps, corrected for any leakage effects¹. Enhancing tumor volumes (reported in mm³) were determined from the post-contrast T1w images, in all slices showing enhancing tumor. The ADC maps were calculated from diffusion weighted signals at the two b-values. A two-tailed Mann-Whitney test was used to determine if significant differences existed between the untreated group and each of the treated groups at each post-treatment day. An $\alpha=0.05$ level of significance was used.

Results: Figure 1 shows the enhancing tumor volume for three different treatment days. Tumor volume increases at a faster rate in the animals treated at the later time point, day 16. Figure 2 shows the median rCBV for three treatment days. In animals treated at day 16, the rCBV is decreased compared to baseline values at each time point. However, the rCBV in rats treated at day 10 increases at each time point. The ADC increases in the rats treated at the earlier time point (Figure 3).

Discussion: Inhibition of tumor volume was greater when animals were treated at the earlier time point. However, treating the tumor at a later time point with Avastin resulted in the maximal decrease in tumor rCBV, which may be consistent with greater VEGF expression at these later stages. The decreased ADC in rats treated at the later time point may be

Figure 1: T1+C

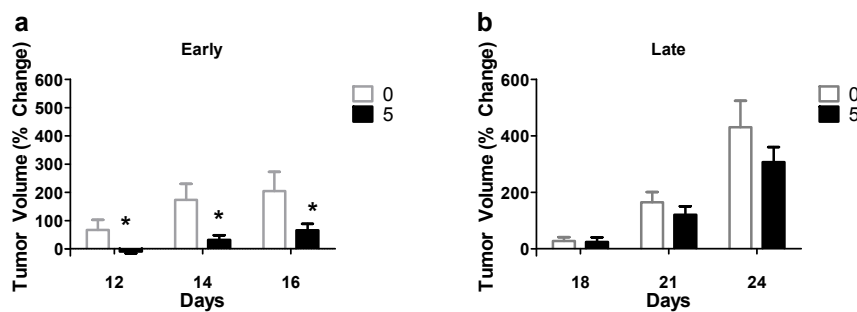


Figure 2: rCBV

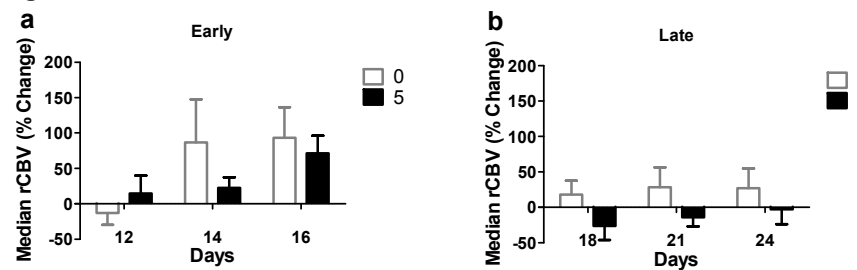
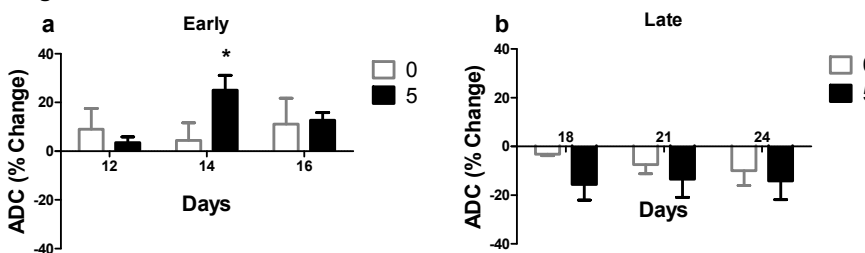


Figure 3: ADC



suggestive an increase in cell density consistent with the increasing tumor volume. Clearly, each marker is sensitive to a different or complementary aspect of tumor response. As such the tissue analysis underway should help to clarify which parameter or combination most accurately indicates tumor response. **Acknowledgements:** NIH/NCI RO1 CA082500, Advancing Healthier Wisconsin / MCW Translational Brain Tumor Program **References** (1) Schmainda KM et al. Am J Neuroradiol 2004; 25:1524-1532.