

Time-resolved Qualitative and Quantitative Analysis of Normal and Altered 3D Portal Venous Hemodynamics in Liver Cirrhosis Patients

Z. Stankovic¹, Z. Csatori¹, P. Deibert², W. Euringer¹, S. Eggerking², P. Blanke¹, Z. Abdullah Zadeh¹, M. Langer¹, and M. Markl¹

¹Radiology, University Hospital Freiburg, Freiburg, Ba.-Wü., Germany, ²Gastroenterology, University Hospital Freiburg, Freiburg, Ba.-Wü., Germany

Introduction: Patients with progressive liver cirrhosis can develop a hyperdynamic syndrome with increasing cardiac output and heart rate while blood pressure and systemic vascular resistance are reduced. Due to growing sinusoidal resistance, the portal flow volume and flow velocity in liver cirrhosis patients are decreased while hepatic resistance and portal vein pressure are increased effecting portosystemic collateral vessels [1,2]. Invasive and non invasive methods are used for monitoring complications related to portal hypertension and the response to pharmacological treatment [3,4]. Contrast-enhanced and non-contrast-enhanced MRI methods have been used for evaluation of liver cirrhosis and portal hypertension in the portal venous system [5,6]. A recent volunteer study evaluated the flow characteristics in the MRI using 2D gradient echo phase contrast sequences [7]. In continuation of an earlier feasibility study [8] we present application of flow-sensitive 4D MRI for the visualization and quantification of portal vein hemodynamics in a cohort of 20 liver cirrhosis patients for improved diagnostic workup. Results were compared to findings in age matched (n=20) and young (n=21) control groups and with the reference standard Doppler ultrasound (US).

Methods: In a study group of 20 liver cirrhosis patients (age=57.7±11.6), 21 young volunteers (age=27.5±3.3) and 20 age matched volunteers (age=58.6±5.9) we evaluated 3D flow characteristics in the portal vein, using time-resolved 3D MR velocity mapping at 3T MRI (TRIO, Siemens, Germany). Data were acquired with prospective ECG gating and during free breathing using navigator at the spleen-lung interface. With a velocity encoding of 50cm/s an axial oblique 3D volume was acquired with a spatial resolution of 1.6 x 2.1 x 2.4mm³. Flip angel was 7°, TE=3.0ms, TR= 5.6ms and temp. res. = 44.8ms. Portal venous flow was evaluated using 3D flow visualisation (EnSight, CEI, Apex, USA) [9] including 3D streamlines and time-resolved particle traces originating from 5 emitter planes precisely positioned at anatomical landmarks in the portal venous system (fig.1). Semi-quantitative grading was performed according to visualisation of the vessels, leakage into adjacent vessel system, maximum flow distribution in the portal vein and type of inflow into the splenic-mesenteric confluence (table1). Quantitative analysis was applied by vessel lumen segmentation and flow quantification using a home built tool (Matlab, TRhge Mathworks, USA) including retrospective extraction of regional peak and mean velocities, flow volume and vessel area. Results were compared to the clinical reference standard US.

Results: 3D streamlines and particle traces visualization in the portal venous hemodynamics could successfully be performed for all patients and volunteers with a slight restriction for one case in the splenic vein and in the left intrahepatic portal vein branch (table 1). Visual evaluation revealed an inflow in the splenic-mesenteric-confluence most often in the dorso-caudal and cranioventral part flow originating in the superior mesenteric and splenic veins, respectively (table 1). A significant correlation for 4D MRI compared to US was found for maximum and mean velocities and flow volume for the intrahepatic vessels. However, velocities and flow were significantly underestimated by MRI except for vessel area which was lower in US. Results of velocity, flow, and area quantification for all groups are summarized in figure 1. Compared to age matched controls, patients demonstrated a significant reduction of mean velocities in superior mesenteric vein and a significant increase of flow volume in splenic vein. Peak velocities and flow were also increased in the left portal vein (fig. 1).

Discussion: We were able to qualitative and quantitative evaluate comprehensive 3D flow of portal venous blood flow of liver cirrhosis patients and normal control groups. The results provide a complete picture of venous hemodynamics in the liver. As expected from the literature, peak and mean velocities were underestimated by 4D MRI compared to US while vessel areas revealed higher values [10]. Quantitative flow analysis could be performed retrospectively at any location of interest and revealed significant alterations in velocities and flow in patients compare to age matched and younger control groups. No significant reduction of peak velocity was found in the patient group while flow volume was only significant increased for the splenic vein. Flow sensitive 4D MRI may be a part of a multimodal setting for liver cirrhosis patients representing standardized method for evaluating pathological changes in flow characteristics or therapy monitoring.

References: 1. Groszmann RJ. Hepatology. 1994;20:1359–1363. 2. Bosch J. J Hepatol 2000; 32:141–156. 3. Drazen Z et al.. Dig Dis Sci. 2009. 4. Albillos A. Am J Gastroenterol. 2007; 102:1116-26. 5. Barthelmes D et al.. Eur J Gastroenterol Hepatol. 2009; 21:693-700. 6. Ito K et al.. J Magn Reson Imaging. 2009; 29:1224-9. 7. Yzet et al. J Magn Reson Imaging. 2010 Mar;31(3):579-88. 8. Stankovic et al. J Magn Reson Imaging. 2010 Aug;32(2):466-75. 9. Markl M, et al.. J Magn Reson Imaging 2007;25:824-831. 10. O'Donohue J et al.. Eur J Gastroenterol Hepatol. 2004; 16:147-55.

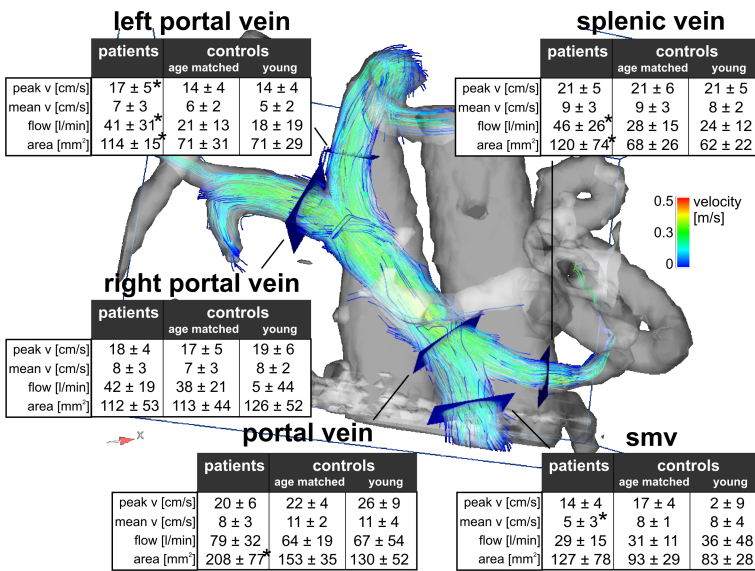


Figure 1: Streamline visualization of portal venous flow of a patient with a re-opened umbilical vein and flow over the left PV branch. Emitter planes were positioned in the superior mes. and splenic vein, splenic-mesenteric confl. and right and left intrahep. portal vein branch. The tables summarize the results of velocity and flow quantification for all 61 subjects included in the study. Significant differences (p < 0.05) between patients and age matched controls are indicated by *.

Flow visualization	visibility		Velocity distribution	
	reader A	reader B	reader A	reader B
superior mesenteric vein	100,00%	100,00%	Homogeneous distribution of peak velocities in streamlines	73,80% 78,70%
splenic vein	98,40%	100,00%	Homogeneous distribution of peak velocities in particle traces	70,50% 73,80%
splenic-mesenteric confl.	100,00%	100,00%	Flow Distribution in splenic-mesenteric confluence (smv / splenic vein)	
portal vein right branch	100,00%	100,00%		
portal vein left branch	86,90%	88,50%	dorsocaudal/ cranioventral	53,33% 48,33%
stream lines leakage	yes in	yes in	caudal/ cranial	28,33% 33,33%
	83,60%	85,20%	dorsal/ ventral	11,67% 11,67%
particle traces leakage	yes in	yes in	ventrocaudal/ dorsocranial	6,67% 6,67%
	50,80%	47,50%	ventrocranial/ dorsocaudal	0,00% 0,00%
			ventral/ dorsal	0,00% 0,00%

Table 1: Summary of the results of the qualitative image grading

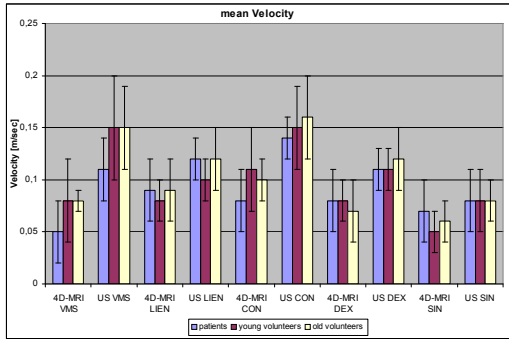


Table 2: mean velocities and flow volume from 5 emitter planes of the portal venous syst. between patients, young volunteers and old volunteers. In patients significant lower values for superior mesenteric vein for mean values and splenic vein in flow volume compared to young and old volunteers.