

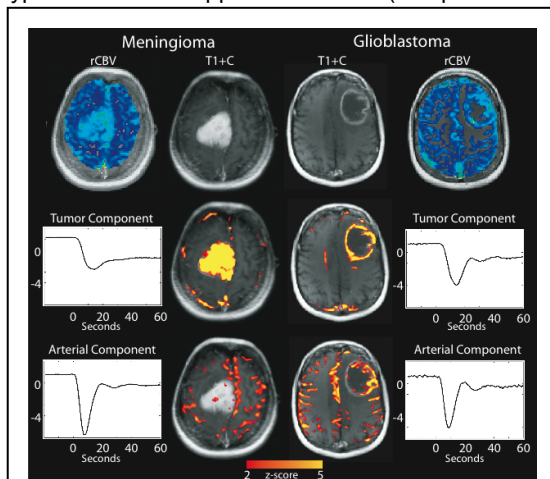
# Independent Component Analysis of Dynamic Susceptibility Contrast MRI in Brain Tumor: a New Biomarker for Measuring Tumor Perfusion Patterns

P. S. LaViolette<sup>1</sup>, A. D. Cohen<sup>1</sup>, S. D. Rand<sup>2</sup>, W. Mueller<sup>3</sup>, and K. M. Schmainda<sup>1,2</sup>

<sup>1</sup>Biophysics, Medical College of Wisconsin, Milwaukee, WI, United States, <sup>2</sup>Radiology, Medical College of Wisconsin, Milwaukee, WI, United States, <sup>3</sup>Neurosurgery, Medical College of Wisconsin, Milwaukee, WI, United States

**INTRODUCTION** It is well known that tumor growth beyond a size of about 2 mm requires the development of its own blood vessels, a process termed angiogenesis. While physiologic angiogenesis, such as that occurs with wound healing, results in the formation of well-ordered mature vessels, pathologic angiogenesis such as that observed with tumors, results in the formation of chaotic and immature vessels. These immature vessels can be comprised of arterial venous shunts, vessel buds and can be dilated. It is therefore not surprising that the resulting tumor perfusion patterns are likewise altered. We therefore hypothesized that application of ICA (independent component analysis) to DSC-MRI signals would provide a new approach for distinguishing tumor from normal tissue, thus demonstrating the potential to serve as a novel biomarker to predict response to anti-angiogenic drugs thought to normalize tumor vasculature.

**METHODS** Twenty five patients with brain tumors were evaluated for this study. Seventeen of them had pathologically confirmed malignant invasive glioblastoma, (GBM) while 8 had benign noninvasive meningioma. Patients underwent routine clinical imaging in conjunction with a session of dynamic susceptibility contrast (DSC) imaging for the purpose of measuring brain tumor perfusion. Leakage-corrected rCBV maps were determined as previously described<sup>1</sup> (Figure 1). Raw DSC data was separately processed using ICA. ICA finds systematically non-overlapping, temporally coherent brain regions without constraining the shape of the temporal response<sup>2</sup>. This technique works exceptionally well in cases without a temporal model<sup>3</sup> such as for DSC data. ICA pre-processing consisted of motion correction, and removal of the first 4 time points for which the signal had not yet reached a steady state. Non-leakage corrected DSC data was then processed using MELODIC (FMRIB tool library) to perform the ICA analysis. Six components were sufficient for characterizing the signal of the arterial input, venous outflow, tumor signal (including leakage effects), and additional variance due to movement and other artifacts. Results were then manually separated into tumor, and



**Figure 5.** Dynamic susceptibility contrast MRI acquired on meningioma and glioblastoma, processed with independent component analysis (ICA) to parse apart arterial and tumor components.

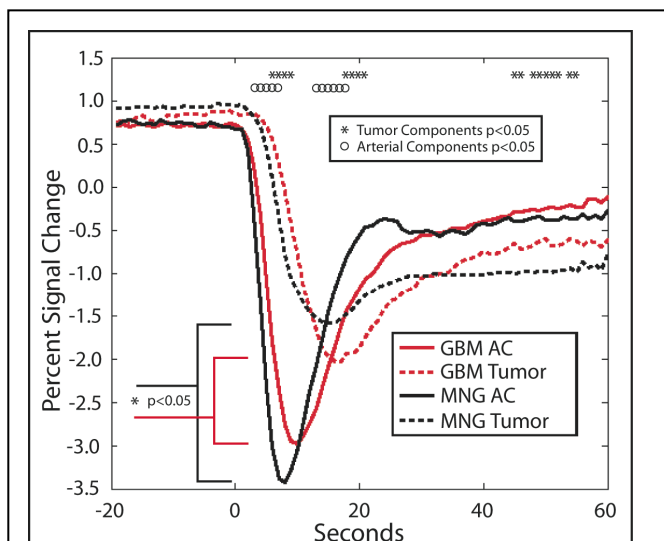
arterial components based on the spatial overlap with either the contrast enhancing lesion or vasculature (Figure 1 middle versus bottom). Vasculature components of each patient were then temporally aligned according to the initial signal dip, for group comparison of perfusion components. Components were then compared across tumor phenotype.

**RESULTS** Figure 1 shows ICA applied to two representative patients, one with a meningioma and one with a glioblastoma. The tumor and arterial component are easily identified. Figure 2 shows the results from the group study comparing tumor type, where significant differences in perfusion kinetics are clearly visible. Contrast circulates into meningiomas significantly faster than GBMs, reaching maximal concentration faster, and stabilizing after the bolus more readily yet at a higher concentration than GBMs. Interestingly, the arterial components also show differences between the tumors. Finally, the minimum-peak to peak difference between the two components is significantly different between tumor types (All significance,  $p < 0.05$ ).

**DISCUSSION** We show that perfusion kinetics of brain tumors can be measured and separated from normal tissue and arterial components with the use of ICA. In addition we have demonstrated that the perfusion kinetics of invasive and noninvasive tumors differ significantly as expected given that GBM exhibit necrosis and inadequate vascular networks while meningiomas show an equilibrium between their microcirculation and the cellular component<sup>4</sup>. Though more research is needed to further validate this technique, it shows promise as a potential biomarker for measuring response to vasculature targeting antiangiogenic drugs.

**Acknowledgements:** NIH/NCI RO1 CA082500, Advancing a Healthier Wisconsin

**REFERENCES** 1. Boxerman, et al. *AJNR* 2006 2. Calhoun, et al. *Neuroimage*. 2009; 3. Calhoun, et al. *MRM* 2002; 4. Principi, et al. *Neuroradiology*. 2003;



**Figure 9.** Results of group study comparing the DSC-ICA tumor and arterial components of 8 meningiomas (MNG) and 14 glioblastomas (GBM). The tumor components are significantly different in three time periods of contrast perfusion indicated by (\*). The arterial components also differ significantly (o), suggestive of global vasculature differences in flow kinetics.