

Whole body PET-MRI scanner: first experience in oncology

O. Ratib¹, M. Viallon², H. Zaidi¹, M. Becker³, J-P. Vallée⁴, M. Wissmeyer¹, J-P. Willi¹, P. Loubeyre⁵, N. Ojha⁶, P. Maniawski⁶, and C. Becker³

¹Nuclear Medicine, Hôpital Universitaire de Genève, GENEVE, Switzerland, ²Radiology, Hôpital Universitaire de Genève, GENEVE, Switzerland, ³Radiology, Hôpital Universitaire de Genève, GENEVE, Switzerland, ⁴Radiology, Hôpital Universitaire de Genève, ⁵Breast Oncology, Hôpital Universitaire de Genève, GENEVE, Switzerland, ⁶Philips Healthcare, Cleveland, United States

Introduction

In the past decade, hybrid PET-CT has gained wide acceptance as an improved imaging modality over PET or CT alone in tumor staging and assessment of therapy response in numerous oncology applications [1, 2]. The idea of combining PET and MRI arose even before PET/CT was introduced and since MR studies provide unmatched diagnostic information regarding soft tissue analysis, tumor detection, tissue characterization and functional imaging. It is not uncommon today for oncology patient to have both a PETCT and an MRI scan providing complementary diagnostic data. With the implementation of a prototype whole-body hybrid PET-MRI scanner, it is therefore quite rational to anticipate that a hybrid PET-MR scanner could be more valuable in those cases than a PET-CT scan followed by a complementary MRI scan [3]. We present preliminary results obtained in 64 patients on our prototype whole-body hybrid PET-MRI scanner.

Material and Methods

The prototype whole body PET-MRI system developed by Philips was tested and evaluated clinically. The system consists of a GEMINI TF PET scanner and an Achieva 3T X-series MRI scanner separated by approximately 3 meters at both ends of a common sliding bed allowing 180° rotation of the patient from one scanner to another with accurate registration between the two modalities allowing direct software fusion identical to the one used in PET-CT.

Imaging Protocols: All patients were studied following a standard diagnostic PET/CT examination performed on a Siemens Biograph 64 scanner. The initial PET-CT scan was acquired 60 minutes following the intravenous injection of 361 ± 32 MBq of ¹⁸F-FDG. Patients were then transferred to the PET-MR scanner for the second PET study without additional tracer injection. The average delay between the first PET study (acquired on a PET-CT scanner) and the second PET study (acquired on the PET-MR scanner) was 85 ± 22 minutes ranging from 49 minutes to 120 minutes depending on the logistics of transferring the patient from the PET-CT suite to the PET-MR scanner. The PET/MRI study consisted of a whole body MR sequence acquired first for PET attenuation correction (termed ACMR) acquired in approximately 3 minutes, then the patient was moved to the PET scanner for scanning (see fig 1). Due to the high sensitivity of the PET scanner and the recommendation of the manufacturer, images were acquired for 2 minutes per bed position, resulting in 18 to 20 minutes total acquisition time. The patient was then moved back to the MR scanner for additional diagnostic MR imaging protocols corresponding to localized clinical indications. For PET image interpretation, the ACMR image can also be used for localizing anatomic structures similar to the practice of using low-dose CT image from PET/CT systems.

Image reconstruction and attenuation correction: An MR-based attenuation correction methodology was developed and validated in preliminary study against CT-based attenuation correction (see fig 2). A whole body ACMR study is converted to an attenuation map using the 3-segment algorithm described previously [19]. This map was used to replace the usual CT-derived attenuation map for PET reconstruction. Pre-generated attenuation maps of RF coils were applied when present inside the PET FOV.

Patient population: 64 patients were studied following a standard diagnostic PET/CT, 37 male and 27 female with a mean body weight of 73 ± 17 kg ranging from 36 kg to 120 kg. The patients were randomly selected among referrals for routine PET-CT studies and included wide range of different oncology diagnosis including lung cancer (4), lymphoma (6), head and neck cancer (8), prostate cancer (13), sarcoma (5), breast cancer (11), melanoma (2), gastrointestinal tumors (5), follow up of treatment and screening (7). This study was approved by our local ethic committee and patients were volunteers to the additional PETMR scan following their PET-CT scan after a detailed briefing by attending physician and signing informed consent form.

Image analysis: All studies were reviewed by tandems of radiologists and nuclear physicians and findings of PET-MR studies were compared to those of the PET-CT study performed the same day. Proper identification of abnormal lesions on PET scans as well as proper anatomical identification and localization of these lesions were compared between the two studies. Image quality was compared and graded for both studies based on a simple three-level score of good, average and poor quality. Presence of artifacts such as metal artifacts, respiratory or motion artifacts, attenuation errors were also listed.

Results: Results showed similar diagnostic accuracy in detection and localization of focal lesions and tumors. Whole-body MR scans developed for rapid acquisition of attenuation correction map, while providing adequate attenuation maps did not provide sufficient anatomical resolution for lesion localization comparable to CT images from PET-CT. Additional focal MR sequences were needed for better anatomical localization and tissue characterization of focal PET lesions. No significant difference in image quality and identification of abnormal lesions were found between the two PET scans of each case. Images of the second scan performed on the PET-MR were comparable to those acquired on the PET-CT scanner and often showed higher contrast with less background noise due to a well known FDG redistribution over such a long period between the two scans. The difference in scanner technology can partially explain the good quality of the second set of images recorded an hour later on a faster scanner using time-of-flight technology and therefore offering a better resolution and higher efficiency. The delay between the two scans being usually over an hour significant change in biodistribution of FDG tracer was observed in all cases. In general, pathological tracer uptake in malignant lesions seemed to increase between the first and the second scan.

Discussion: While the added value of hybrid PET-CT over the two modalities acquired separately has been well established clinically [4-6], the expected added value of hybrid PET-MR remains to be demonstrated [7-9]. A limiting factor that must be addressed before hybrid PET-MR can be used in clinical routine is the total duration of MR imaging protocols. Adding PET scanning time to full diagnostic clinical MRI protocols can be significantly longer than standard PET-CT study. Our preliminary experience shows that whole body PET imaging with TOF technology can be achieved under 15 minutes, added to a whole body attenuation and localization MRI scan acquired under 5 minutes resulting in a combined PET-MR scan in less than twenty minutes. Most clinical protocols would require between 2 and 5 additional MRI series with dedicated protocols on specific organs or body sections.

These additional sequences can also be completed under 30 minutes, allowing to complete a diagnostic PET-MR scan within an hour. While this study is longer than standard diagnostic PET-CT study, it is still shorter than the total time that a PET-CT and an MRI study would take today when performed on two separate scanners at different times. This clearly benefits the patients that need both PET-CT and MR studies in their clinical workup.

References: (1) Collins, C.D., Cancer Imaging, 2007 (2) Lonsdale, M.N. and T. Beyer. Eur J Radiol, 2010. (3) Liang, X. et al. Eur J Radiol. (4) Yang, W. Lung Cancer, 2008. (5) Czernin, J. et al, J Nucl Med, 2007. (6) Platzeck, I. Acta Radiol. (7) Venkitaraman, R et al. J Med Imaging Radiat Oncol, 2009. (8) Schmidt, G.P. Eur J Radiol, 2009. (9) Chen, W. et al. Magn Reson Imaging, 2010.

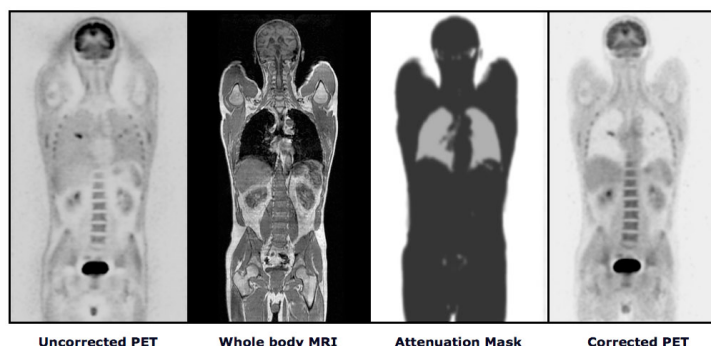


Fig1: Attenuation correction of PET images using an attenuation map generated from automatic segmentation of whole-body 3D T1 weighted MRI images. PET images evidence a right lung pulmonary lesion.