

# Decreased Brain Stiffness in Alzheimer's Disease Determined by Magnetic Resonance Elastography

M. C. Murphy<sup>1</sup>, J. Huston, III<sup>1</sup>, C. R. Jack, Jr.<sup>1</sup>, K. J. Glaser<sup>1</sup>, A. Manduca<sup>1</sup>, J. P. Felmlee<sup>1</sup>, and R. L. Ehman<sup>1</sup>

<sup>1</sup>Department of Radiology, Mayo Clinic, Rochester, MN, United States

## Introduction

Magnetic resonance elastography (MRE) is a technique to noninvasively measure tissue stiffness [1]. MRE is a three-step process beginning with the introduction of shear waves via an external vibration source. The shear waves are then imaged with a phase-contrast MRI pulse sequence with motion-encoding gradients synchronized to the external motion. Finally, the shear wave images are mathematically inverted to calculate tissue stiffness. Among many applications, MRE has been pursued for brain imaging for its potential to aid in the diagnosis of brain diseases [2-6], with recent studies showing decreased brain stiffness in multiple sclerosis [7] and normal pressure hydrocephalus [8]. The purpose of this work was to test the reproducibility of 3D MRE of the brain and to use MRE to study the effects of Alzheimer's disease (AD) on brain stiffness.

## Methods

These studies were approved by our institutional review board and subjects were imaged after obtaining written informed consent.

**Reproducibility Study:** Ten male volunteers all without known neurological disease were recruited to study reproducibility of the 3D brain MRE exam (median age: 29, range: 25-52). Each volunteer underwent 4 MRE exams separated into 2 days (mean separation: 8.7 days, range 4-20). On each day, two independent MRE measurements were performed by taking the subject off the table and disassembling and reassembling the MRE setup between the two MRE exams. MRE images were collected with a modified spin-echo EPI pulse sequence with the following parameters: 55-Hz vibration, TR/TE=1636/64 ms, FOV=25.6 cm, 60x60 imaging matrix reconstructed to 64x64, R=3 ASSET acceleration, 2.5-mm slices with 1.5-mm spacing, one 18.2-ms motion-encoding gradient on each side of the refocusing pulse, x, y and z motion encoding and 4 phase offsets over one period of motion. The resulting images had 4-mm isotropic resolution.

**AD Study:** The effects of AD on brain stiffness were studied in 28 subjects: 7 with probable AD (median age: 85, range: 76-94), 14 age- and gender-matched PIB-cognitively normal controls (CN-) (median age: 81.5, range: 75-89), and 7 age- and gender-matched PIB+ cognitively normal controls (CN+) (median age: 83, range: 73-93). PIB is an amyloid PET tracer, indicating the presence or absence of  $\beta$ -amyloid in the brain (a hallmark of AD). The ages of the three groups were not significantly different ( $p=0.17$ , Kruskal-Wallis). Each group had a 5-to-2 ratio of male to female subjects. Acquisition parameters were the same as above except: 60-Hz vibration and TR/TE=1500/61.3 ms. An additional scan with the same parameters but only 2 offsets over half a period of motion with no externally applied motion was collected for signal-to-noise ratio (SNR) calculations (referred to as "no motion" data below).

**Image Processing:** Processing was performed on 18 slices covering the cerebrum. The curl of the wave images was taken to remove longitudinal and surface wave effects [9]. Derivatives were calculated with central differences taken over a 3x3x3 window. The first temporal harmonic of the vector curl was inverted with a direct inversion algorithm in a 3x3x3 window [10]. The median stiffness from each subject was reported from a global region of interest (ROI). For the reproducibility study, the ROI excluded 3 voxels from the edge, the longitudinal fissure, ventricles and low magnitude signal regions. For the AD study, the SNR was calculated as the voxel-to-voxel ratio of the amplitude of the first temporal harmonic of the vector curl of the shear wave images to the standard deviation of the no motion data calculated in a sliding 3x3x3 window. The ROI included any voxel with SNR>5, excluded 3 voxels from the edge of the brain and the longitudinal fissure and any voxel with greater than 30% cerebrospinal fluid content [11].

## Results

The median stiffness of the 10 volunteers in the reproducibility study was 3.07 kPa (range: 2.81-3.21 kPa). The median and maximum coefficients of variation were 1.71% and 3.07%, respectively, indicating high reproducibility of the 3D brain MRE exam. Example images from an AD subject and an age-matched CN- subject are shown in Figure 1. The median stiffness of the CN- group was 2.37 kPa (range: 2.17-2.62 kPa), the median stiffness of the CN+ group was 2.32 kPa (range: 2.18-2.67 kPa), and the median stiffness of the AD group was 2.20 kPa (range: 1.96-2.29 kPa) (Fig. 2). A significant difference in brain stiffness between groups was found in vivo using 3D brain MRE ( $p=0.0055$ , Kruskal-Wallis). Both the CN- group ( $p=0.0015$ , Wilcoxon rank sum test) and the CN+ group ( $p=0.026$ ) differed from the AD group. The CN groups did not differ from each other ( $p=0.85$ ).

## Discussion

The 3D brain MRE exam presented in this work was highly reproducible, and detected a significant difference in vivo in the brain stiffness of subjects with AD compared to age- and gender-matched controls. Since no change in brain stiffness was detected between the CN- and CN+ groups, the change in brain stiffness cannot be attributed to the deposition of  $\beta$ -amyloid alone. The change in brain stiffness likely reflects the loss of normal cytoarchitecture in the brain related to synaptic loss or neurodegeneration due to AD. Brain stiffness demonstrates potential as a novel biomarker to improve the ability to detect or grade Alzheimer's disease.

## References

[1] Muthupillai et al. Science 1995. 269 (5232): 1854. [2] Kruse et al. Neuroimage 2008. 39 (1): 231. [3] Sack et al. NMR Biomed 2008. 21: 265. [4] McCracken et al. Magn Reson Med 2005. 53 (3): 628. [5] Green et al. NMR Biomed 2008. 21: 755. [6] Xu et al. Acta Radiol 2007. 48 (1): 112. [7] Wuerfel et al. Neuroimage 2010. 49 (3): 2520. [8] Streitberger et al. NMR Biomed 2010. In press. [9] Glaser & Ehman. Proc. ISMRM 2009. [10] Oliphant et al. Magn Reson Med 2001. 45: 299. [11] Jack et al. Brain 2008. 131: 665.

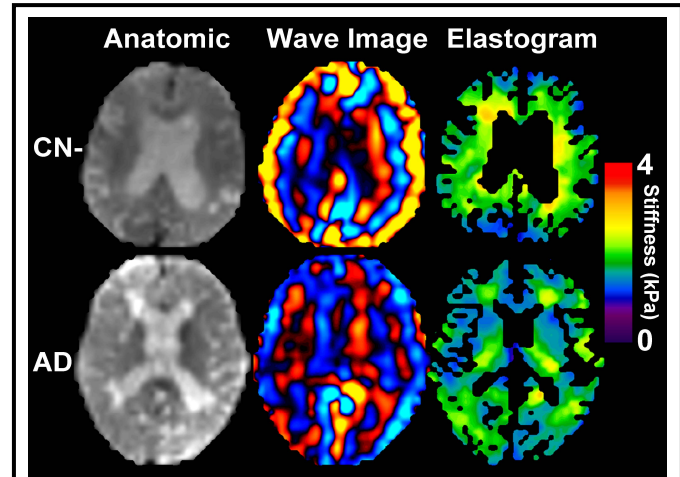


Figure 1. Example brain MRE images. Images in the top row show the results from an 84-year-old male CN- subject and the bottom row shows results from an 85-year-old female subject with AD. Magnitude images for each subject are shown in the first column. The second column shows the first time offset of the z component of the curl of the MRE wave images. The resulting elastograms are shown in the last column.

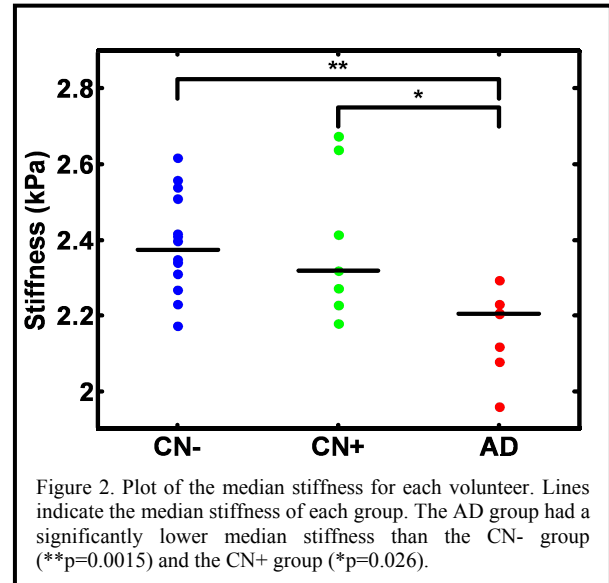


Figure 2. Plot of the median stiffness for each volunteer. Lines indicate the median stiffness of each group. The AD group had a significantly lower median stiffness than the CN- group (\*\* $p=0.0015$ ) and the CN+ group (\* $p=0.026$ ).