

Ten-year brain atrophy rate and its relevance to disability in multiple sclerosis

A. Giorgio¹, M. L. Stromillo¹, M. L. Bartolozzi², F. Rossi¹, M. Battaglini¹, A. Blandino¹, L. Guidi², P. Maritato², A. Federico¹, and N. De Stefano¹

¹Department of Neurological and Behavioral Sciences, University of Siena, Siena, Italy, ²Neurology Unit, Hospital of Empoli, Italy

Introduction

Brain atrophy is considered an important marker of progression in multiple sclerosis (MS). Focal tissue damage (i.e., lesions in the white matter [WM]) do not lead to progression in a simple way and cannot fully explain the substrate underlying clinical disability. Brain atrophy in MS is the expression of a generalized process involving different cerebral tissue compartments. Most studies have assessed brain atrophy over short-to-moderate periods and the long-term relationship between brain atrophy rate and clinical disability progression is unknown.

Materials and Methods

We acquired conventional brain MRI in 47 patients with clinically definite MS (age=37.3±10; 40 relapsing-remitting [RR], 5 secondary progressive [SP] and 2 primary progressive [PP]; disease duration=4.7±6.1 years) and in 7 normal controls (NC) (5 females and 2 males; age=39.7±5.6 years). The study is ongoing. Clinical assessment and MRI examination with the same scanner and protocol were repeated after 10±0.2 years. MR data were obtained using a 1.5T Philips Gyroscan (Philips Medical Systems, Best, The Netherlands). A dual-echo, turbo spin-echo sequence (TR/TE1/TE2=2075/30/90 ms, 256x256 matrix, 1 signal average, 250mm field of view [FOV], 50 contiguous 3mm slices) yielding proton density (PD)-weighted (PD-W) and T2-weighted (T2-W) images was acquired in the transverse plane parallel to the line connecting the anterior and posterior commissures. Subsequently, T1-weighted (T1-W) images (TR/TE=35/10 ms, 256x256 matrix, 1 signal average, 250mm FOV) yielding 50 slices, 3mm thick, oriented to exactly match the PD/T2-W sequence, were acquired. Monthly quality assurance sessions and no major hardware upgrades were carried out on the scanner during the time of the study. T2-lesion volume (LV) was obtained through a semiautomated segmentation technique based on user-supervised local thresholding (Jim 4.0, Xinapse System, Leicester, UK). Lesion borders were determined primarily on PD-W images but information from T2-W and T1-W images was also considered. Brain parenchyma volumes (normalized measures of brain volume [NBV], grey matter [GM] volume [NGMV], WM volume [NWMV] and ventricular cerebrospinal fluid [vCSF]) were measured on T1-W images by using the cross-sectional version of the SIENA software, SIENAX (part of FSL 4.1- <http://www.fmrib.ox.ac.uk/fsl/>). To avoid tissue misclassification due to WM lesions, the latter were masked out and refilled with intensities matching the surrounding normal-appearing WM before each tissue-class segmentation. Global brain volume changes over 10 years were quantified using the SIENA method, also part of FSL, which allows estimate the percentage brain volume change (PBVC) between the two time-points. The Mann-Whitney test was used for comparing MS patients and NC and for comparing MS subgroups. Correlations of brain volume measures with demographic and clinical features were analyzed using the Spearman coefficient. Data were considered significant at the 0.05 level.

Results

In the MS patients, EDSS was 2.5±1.7 at baseline and 3.4±2.2 at follow-up (p<0.001). Mean number of relapses over 10 years was 3.8±3.6 and the mean relapse rate was 0.4±0.4. After 10 years, the disease course turned into SP in 3 RR subjects. In addition, there were differences between baseline and follow-up in T2-LV (from 5.4±5 cc to 8±7 cc, p<0.001).

Comparisons between MS patients and NC. PBVC was higher in MS patients than in NC (MS=-5%±2.2%, NC=-3%±1.2%, p=0.03; Figure 1). This difference was still present when considering only patients with a RR course at both time-points (n=37, PBVC=-5%±2.3%). Changes in NGMV and NWMV between MS patients and NC did not reach significance (p>0.10) whereas change in vCSF was different between the two groups (p=0.02) (Figure 2).

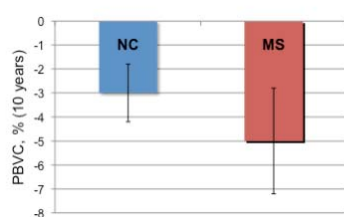


Fig. 1

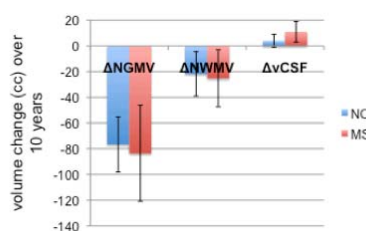


Fig. 2

Within the MS group, PBVC of patients with a relapse rate of at least 0.5 (n=14) was higher than in patients with a relapse rate lower than 0.5 (n=33) (-6.1%±2.5% versus -4.3%±1.9%, p=0.02) (Figure 3). Moreover, patients with an EDSS change of at least 0.5 (n=31) had a higher PBVC, although not significant, than patients with no EDSS change (n=16) (-5%±2.4% versus -4.6%±1.9%, p=0.7). Changes in NGMV, NWMV and vCSF between MS subgroups (relapse rate higher and lower than 0.5 [Figure 4], EDSS change higher and lower than 0.5) and NC were not significantly different (p>0.10 for all comparisons), except for change in vCSF (p=0.02).

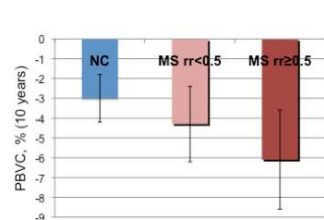


Fig. 3

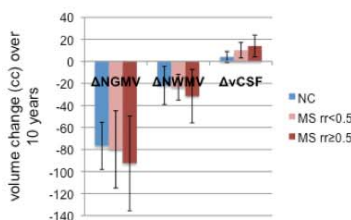


Fig. 4

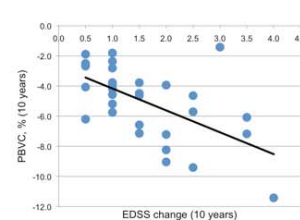


Fig. 5

Relationship between MR measures and clinical disability. PBVC correlated with EDSS change (r=-0.30, p=0.04). The correlation was similar when considering only patients with an RR course at both time-points. When the analysis was restricted to patients with an EDSS change of at least 0.5, PBVC was more correlated with EDSS change (r=-0.57, p=0.001) (Figure 5). Furthermore, in the same MS subgroup EDSS change was correlated with changes in NGMV (r=-0.41, p=0.02), but not in NWMV (r=-0.20, p=0.32).

Conclusions

This ongoing study is the first report of a long-term (10 years) follow-up on brain atrophy change in patients with MS. Brain volume loss is, on average, in the order of -5% in MS patients, and -3% in normal controls, and seems to be a global process, involving all the tissue compartments. Brain atrophy rate is higher in patients with a higher frequency of clinical relapses, suggesting that acute inflammatory activity in the brain is an important determinant of brain atrophy in the long term. Brain atrophy rate, both global and in the grey matter was associated to clinical worsening, particularly in subjects with progressing disability. This suggests that long-term brain atrophy change may provide a valuable outcome of longstanding disability and progression in patients with MS.