

Spectroscopic imaging of human medial temporal lobe epilepsy at 7T

J. W. Pan¹, D. D. Spencer¹, R. Duckrow², N. Avdievich¹, and H. P. Hetherington¹

¹Neurosurgery, Yale University School of Medicine, New Haven, CT, United States, ²Neurology, Yale University School of Medicine, New Haven, CT, United States

Introduction: The presence of unilateral hippocampal atrophy in the evaluation of medial temporal lobe epilepsy (MTLE) is often a defining factor that if concordant with the EEG and PET and not contraindicated from neuropsychological data, will typically result in candidacy for surgical resection. However, as suggested from Kobayashi et al 2003 (1), it is possible to have hippocampal atrophy (HA) without intractable seizures particularly in familial MTLE. We used ultra-high field MR spectroscopic imaging at 7T to assess MTLE with patients who are all HA positive. We studied n=12 patients who were medically intractable and n=2 patients who were very well controlled (seizure free for >2years on medication).

Methods: Imaging: We used a head only Varian 7T MR system equipped with 1st-3rd order shims with an 8 element transceiver array for all studies. The transceiver array was used with RF shimming to optimize multiple spatially distinct RF distributions to achieve 1kHz B1 transmission over large volumes sufficient for spectroscopic spin echo imaging and outer volume suppression. All acquisitions used a ROI targeting the medial temporal lobes and were angulated along the planum temporale. Nested field mapping was used for non-iterative Bo shimming (2). To assess the role of higher order shimming, the achieved field homogeneity was calculated over the entire ROI ($\sigma_{Boglobal}$) comparing the anticipated optimal 1st and 2nd order shimming with 1st through 3rd shims (Fig. 1). A moderate TE40msec spin echo sequence was used to acquire the singlet resonances with spectroscopic imaging (nominal voxel size 0.64cc). A single voxel reconstruction technique was used to consistently place the hippocampal spectra in three loci as shown in Fig 2.

Clinical: All patients (n=14) were recruited from the medical center Epilepsy Program. All patients demonstrated hippocampal atrophy (HA) on conventional MR imaging (n=9 right HA; n=5 left HA). All except 1 of the 14 patients also had Phase 1 monitoring data that demonstrated clinical and lateralized electrographic changes that were consistent with the side of hippocampal atrophy. One surgical patient who had been seizure free >2 years sought surgical resection for the purposes of medication discontinuation. The pathology on this well controlled patient showed severe hippocampal sclerosis. One non-surgical patient was medically well controlled on monotherapy, and had semiology consistent with medial temporal lobe epilepsy. Neither of these two patients had a family history of epilepsy. Age matched controls were recruited from the university community.

Results: The use of 1st- 3rd order shims in the medial temporal lobes in comparison to 1st-2nd order shims reduced the $\sigma_{Boglobal}$ in the group from 16.6±4.4 to 10.5±2.5 Hz (Fig. 1). Spectral data from a patient are shown in Fig. 2. As a group, the n=12 patients who were medically intractable demonstrated a significantly higher (abnormal) Cr/NAA value in the ipsilateral medial temporal lobe anteriorly in comparison to control (1.06±0.21 patients vs. 0.83±0.04 controls; p<0.005, Table). The n=2 patients who were well controlled had values of 0.84 and 0.65, mean 0.74.

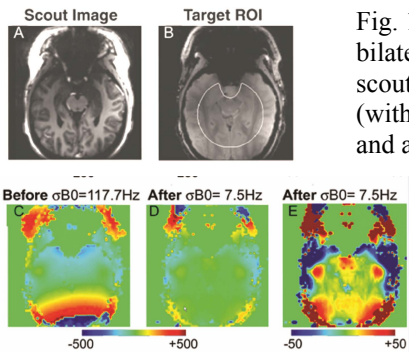


Fig. 1. Bo shimming of the bilateral medial temporal lobes, scouts, ROI and Bo field maps (with $\sigma_{Boglobal}$ values) before and after 1st-3rd shimming. The scale of Fig. 1E is 10x that of Fig. 1D.

Fig. 2. Spectra from a L MTLE patient. Loci are indicated with circles.

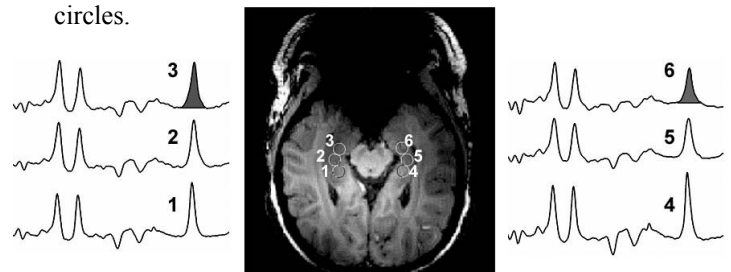


Table. Cr/NA values in intractable MTLE patients vs. controls; p<0.01*, p<0.005** significantly different from control

	Ipsi 1	Ipsi 2*	Ipsi 3**	Contra 4	Contra 5	Contra 6
Patient	0.76±0.08	0.86±0.09	1.06±0.21	0.74±0.06	0.75±0.09	0.82±0.12
Control	0.72±0.07	0.76±0.07	0.83±0.04			

Conclusions: Spectroscopic imaging at 7T of medically intractable MTLE is consistent with extensive previous data showing a mean ~28% rise in Cr/NAA in comparison to control. The two patients with MRI documented hippocampal atrophy but who were seizure free on medical therapy had Cr/NAA values similar to control. As an evaluation of neuronal mitochondrial function, these data are consistent with the view that Cr/NAA reflects ongoing dysfunction and may be more informative for an assessment of tissue health than tissue loss directly.

Ref: (1) Kobayashi et al 2003 Arch Neurol. 60:1546 (2) Hetherington 2009 MRM 2006 56:26.