

# In vivo dynamic contrast enhanced MRI and histopathological assessment of tumor angiogenesis in luminal-like and basal-like breast cancer xenografts

E. M. Huuse<sup>1</sup>, S. A. Moestue<sup>1</sup>, T. F. Bathen<sup>1</sup>, A. Bofin<sup>2</sup>, G. M. Mælandsmo<sup>3</sup>, L. A. Akslen<sup>4</sup>, O. Engebraaten<sup>3,5</sup>, and I. S. Gribbestad<sup>1</sup>

<sup>1</sup>Department of Circulation and Medical Imaging, Norwegian University of Science and Technology (NTNU), Trondheim, Norway, <sup>2</sup>Department of Laboratory Medicine, Children's and Women's Health, NTNU, Trondheim, Norway, <sup>3</sup>Department of Oncology and Department of Tumor Biology, Oslo University Hospital, Oslo, Norway, <sup>4</sup>The Gade Institute, Section for Pathology, University of Bergen, Bergen, Norway, <sup>5</sup>Institute for Clinical Medicine, University of Oslo, Oslo, Norway

## Introduction

Molecular sub-classification of breast cancer based on gene expression pattern represents clinically distinct patient groups<sup>(1)</sup>. Two new breast cancer xenograft models, reflecting the luminal-like (MAS98.06, ER<sup>+</sup>, low growth rate) and basal-like (MAS98.12, ER<sup>-</sup>, high growth rate) subgroups, have recently been established by direct transplantation of primary tumor tissue<sup>(2)</sup>. The purpose of this study was to investigate differences in tumor vasculature and angiogenesis, and the effect of tumor volume using dynamic contrast enhanced (DCE) MRI and histopathological measures in these two model systems.

## Experimental

Tumors (n=27) from each model were orthotopically grafted in female BalbC nu/nu mice<sup>(3)</sup> to satisfying predefined volume criteria for medium-sized (volume  $\approx 450 \text{ mm}^3$ ) and large tumors (volume  $> 1400 \text{ mm}^3$ ), respectively (luminal-like: medium-sized tumors, n=6, 9 weeks of growth; large; n=7, 15-22 weeks of growth; basal-like: medium-sized; n=7, 8 weeks of growth; large; n=7, 11 weeks of growth, volume distributions are shown in Figure A) were examined using a BRUKER Biospec 7T animal scanner. Precontrast T1-values were measured using a series of T1-weighted spin-echo images, followed by a DCE-MRI sequence with 200 images, 4.8 sec temporal resolution and a voxel size of  $0.32 \times 0.32 \times 0.6 \text{ mm}^3$ . During the 10<sup>th</sup> repetition, a dose of 0.3 mmol/kg gadodiamide (Omniscan TM, GE Healthcare, Oslo, Norway) was injected intravenously (4 sec). T1-weighted high resolution images were obtained after DCE-MRI (Figure A). Tofts model<sup>(4)</sup> was used to estimate  $K^{\text{trans}}$ ,  $v_e$  and  $v_p$  for each voxel, and median values for each tumor were calculated. After MRI examination, a dose of 60 mg/kg body weight of pimonidazole (Hypoxprobe<sup>TM</sup>-1, Massachusetts, USA) was injected intraperitoneally 30-45 minutes before tumors were harvested. Tumors were stained for both pimonidazole and dual stained for CD34 (Abcam, Cambridge, UK) and Ki67 (Dako, Glostrup, Denmark). Hypoxic fraction, microvessel density (MVD) and vascular proliferation index (number of dual stained vessels per area/MVD) were measured. Independent samples t-test was used for comparison of MRI extracted parameters and histopathological measures between the groups with different tumour volume and between the two models, and Spearman's correlation between the MRI and histopathological parameters was calculated. The level of statistical significance was defined as  $p < 0.05$ .

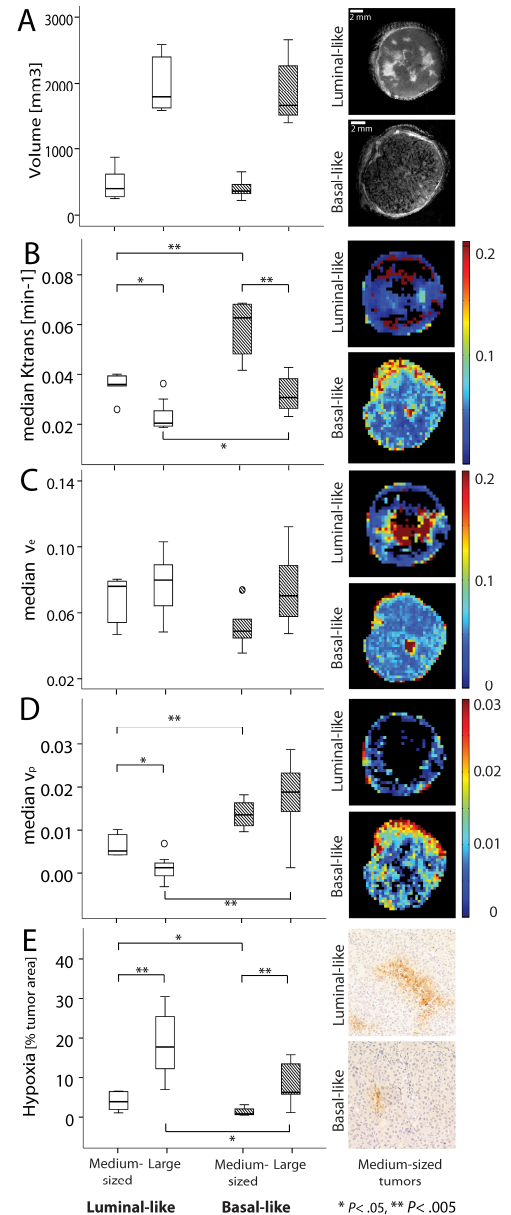
## Results

The DCE-MRI results showed a significantly higher  $K^{\text{trans}}$  in basal-like tumors compared to the luminal-like tumors. This was valid for both large and medium sized tumors (Figure B).  $v_p$  were significantly higher in basal-like tumors than in luminal-like tumors. For basal-like tumors there was no difference in  $v_p$  between medium-sized and large tumors, but a significantly lower  $v_p$  in large compared to medium-sized luminal-like tumors (Figure D). VPI was significantly lower and hypoxia significant higher in luminal-like tumors compared to basal-like tumors. The  $v_e$  and MVD were similar for all the tumors. The results showed a positive correlation between  $v_p$  and MVD ( $\rho = 0.51$ ,  $P < .05$ ) and a negative correlation between  $v_p$  and hypoxia ( $\rho = -0.54$ ,  $P < .05$ ), and between  $K^{\text{trans}}$  and hypoxia ( $\rho = -0.77$ ,  $P < .05$ )

## Discussion

Basal-like tumors are more aggressive than luminal-like tumors, which is in accordance with the higher  $K^{\text{trans}}$  found for both medium-sized and large xenografts. The significant higher VPI in the basal-like tumors suggest a higher angiogenic activity in these tumors. The low  $v_p$  combined with a high fraction of hypoxia in the large luminal-like tumors suggest a low angiogenic activity in these tumors that might contribute to the low growth rate of the luminal-like tumors. The significant correlation between *in vivo* measured  $v_p$  and the *ex vivo* measurements of vasculature MVD combined with the correlation between the *in vivo* measured parameters  $K^{\text{trans}}$  and  $v_p$ , and the *ex vivo* measured hypoxia fractions, suggest that DCE-MRI provide *in vivo* assessment of tumor microenvironment in xenografts with different gene expression pattern.

**References:** 1) Perou CM *et al.* Nature 2000. 2) Bergamaschi A. *et al.* Mol. Oncol. 2009. 3) Moestue *et al.* BMC Cancer 2010. 4) Tofts PS *et al.* JMRI, 1999.



**Figure:** A) The distribution of tumor volume in each animal group and high resolution post contrast images from a medium-sized tumor from each model, B-D) boxplots showing the distribution of  $K^{\text{trans}}$ ,  $v_e$  and  $v_p$  in each tumor group and parametric maps from two medium-sized tumors, and E) fraction of hypoxia in each groups and images of the histopathological staining. All images are of medium-sized tumors.