

Cartilage Quality Assessment using gagCEST and Sodium MRI at 7 Tesla

B. Schmitt¹, S. Zbyn^{2,3}, D. Stelzeneder², V. Jellus⁴, D. Paul¹, L. Lauer⁴, P. Bachert¹, and S. Trattnig²

¹Medical Physics in Radiology, German Cancer Research Center, Heidelberg, Germany, ²Radiology, Medical University of Vienna, Vienna, Austria, ³Orthopedics, Medical University of Vienna, ⁴Siemens Healthcare, Erlangen, Germany

Introduction:

Articular cartilage injuries are common types of injuries encountered in orthopaedic practice. Several therapeutic strategies have been developed to repair damaged articular cartilage and produce a durable repair. One of the components of healthy cartilage, glycosaminoglycans (GAG), is responsible for the biomechanical properties of articular cartilage [1], and focal loss of GAG represents the earliest stages of cartilage degeneration [2]. GAG specific MR techniques are delayed gadolinium-enhanced MRI of cartilage (dGEMRIC [3]) and sodium imaging [4]. Recently, a new GAG-specific sequence based on chemical exchange was reported [5]. The aim of this study was to investigate a newly developed method, which enables 3-dimensional gagCEST imaging in clinically relevant scan times at 7 Tesla. Results of gagCEST imaging in patients after cartilage repair surgery were compared to results obtained with another glycosaminoglycan-specific technique, namely sodium imaging, as a reference method.

Materials & Methods:

The study comprised 12 patients who underwent cartilage repair surgery. All examinations were performed in accordance and with approval of the local ethics committee. Experiments were performed on a 7 T MRI system (Siemens Healthcare, Erlangen, Germany). For ¹H imaging, a new 28-channel Tx/Rx knee coil (QED, Mayfield Village, OH, USA), and for ²³Na imaging a circularly polarized knee coil (Stark Contrast, Erlangen, Germany) were employed. For gagCEST imaging, a series of Gaussian-shaped RF pulses followed by gradients in x-, y- and z-direction was applied to saturate proton resonances at variable offset frequencies to each spectral side of bulk water. After RF pre-saturation, image readout was performed with a 3-dimensional RF-spoiled gradient echo (GRE) sequence ($T_E = 3.2$ ms, $T_R = 7.3$ ms). The FoV was $146 \times 180 \times 84$ mm³ with a matrix size of $208 \times 256 \times 28$. Total acquisition time for one CEST measurement was 14:34 min. Sodium imaging was performed with a modified 3-dimensional GRE sequence ($T_E = 3.77$ ms, $T_R = 10$ ms) [6]. The acquisition matrix was $64 \times 128 \times 36$ with a FoV of $199 \times 199 \times 108$ mm³, and the measurement time was 30:45 min.

To compensate for movement of the knee during the course of a measurement, gagCEST datasets were registered using a non-rigid approach. Z-spectra from images were fitted with a cubic spline method and corrected for B_0 inhomogeneities on a pixel-by-pixel basis. The asymmetry of the magnetization transfer rate (MTR) as determined by

$MTR_{asym}(\delta) = MTR(+\delta) - MTR(-\delta)$ was summed for offsets from 0 – 1.3

ppm in each pixel and used as gagCEST signal intensity. Sodium SNR values of ROIs were used for data analysis of sodium images to ensure comparability between subjects. Sodium and gagCEST images were examined with regions-of-interest (ROI) analysis. Sodium SNR values and gagCEST signal intensities were measured from a region covering the cartilage repair tissue and an equally sized region in normal native cartilage. To assure comparability between ROI placement in the two imaging modalities similar sized ROIs were drawn in the cartilage repair tissue and the native cartilage, in the same positions on identical slices in a side-by-side evaluation. Ratios of ROI values obtained in healthy cartilage compared to repair tissue were determined and the Pearson correlation coefficient was calculated to evaluate associations between gagCEST and sodium imaging.

Results:

The average asymmetry in gagCEST z-spectra summed over all offsets from 0 to 1.3 ppm was significantly higher ($p < 0.004$) in native cartilage (8.01 ± 2.79 % (mean \pm SD)) than in repair tissue (4.65 ± 2.23 %) (Fig.1). This is in good agreement with sodium imaging, where healthy cartilage (16.53 ± 3.66) yielded significantly ($p < 0.004$) higher SNR compared to repair tissue (12.36 ± 2.46) (Fig. 2). Furthermore, a strong correlation ($R = 0.885$, $p = 0.0001$) was found between ratios of native cartilage to repair tissue obtained with gagCEST, and sodium imaging (Fig. 3). The mean dimensionless ratios between native cartilage and repair tissue were 1.39 ± 0.30 for gagCEST, and 1.34 ± 0.21 for sodium MRI. Delineation of repair tissue from native cartilage was equally well possible with both techniques employed in this study. Localizations of signal reductions as found in sodium images showed good agreement with gagCEST images (Fig. 4).

Discussion and Conclusion:

The high correlation between results obtained with the new gagCEST method, and ²³Na imaging, respectively, demonstrate the GAG specificity and reliability of the developed gagCEST imaging method. Both techniques suggest that cartilage repair tissue has lower GAG content than native tissue. This study used the beneficial properties that high magnetic field offers for both techniques. Since SAR restrictions, patient compliance, and availability of 7 T whole-body MR scanners would limit broader use of the techniques for clinical routine, a transition of the gagCEST method to 3 T is currently under investigation.

References:

- [1] Roughley PJ & Lee ER. Micros. Res. Tech. 1994;28(5):385-397
- [2] Buckwalter JA *et al.* J. Bone Joint Surg. Am. Vol. 1997;79A:612-632
- [3] Bashir A *et al.* Magn. Reson. Med. 1996;36(5):665-673
- [4] Reddy R *et al.* Magn. Reson. Med. 1997;38(2):207-214
- [5] Ling W *et al.* Proc. Natl. Acad. Sci. U S A 2008;105(7):2266-2270
- [6] Trattnig S *et al.* Radiology 2010;257(1):175-184

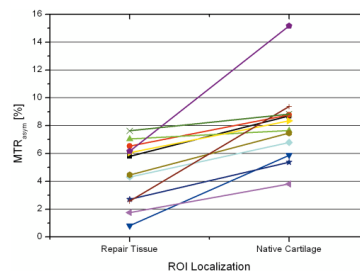


Fig. 1: MTR asymmetry values from ROIs placed in healthy cartilage, and repair tissue in each patient after cartilage repair surgery.

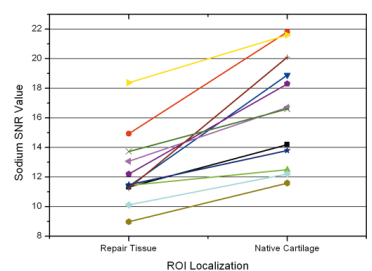


Fig. 2: Sodium SNR values from ROIs placed in healthy cartilage, and repair tissue in each patient after cartilage repair surgery.

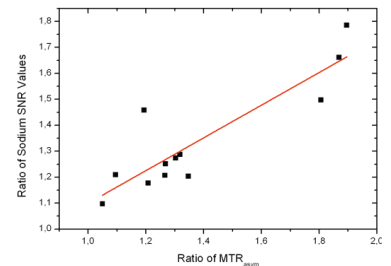


Fig. 3: Correlation analysis of the dimensionless signal ratios between native cartilage and repair tissue obtained with gagCEST, and ²³Na imaging, respectively.

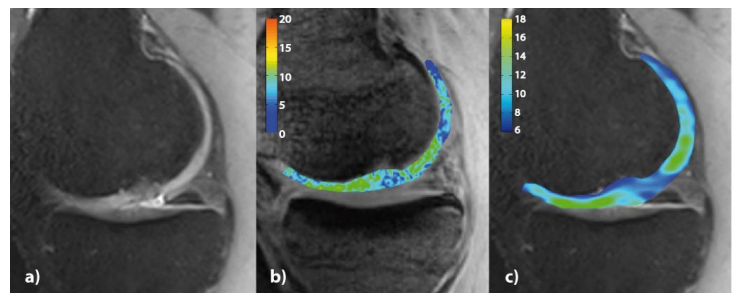


Fig. 4: Comparison of high-resolution morphological (a), gagCEST (b) and sodium (c) MR images of the knee joint cartilage of a patient after cartilage repair surgery (MACT). The MACT region is located in the lateral femoral condyle. Colorbars represent MTR_{asym} values summed over offsets from 0 to 1.3 ppm (gagCEST), and sodium SNR values, respectively. The higher spatial resolution of the gagCEST technique is beneficial in areas with thin cartilage where sodium MRI tends to show decreased GAG values due to partial volume effects with surrounding tissue.