

Contrast agents and MR protocols for molecular imaging of murine myocardial infarction

L. E. Paulis¹, B. F. Coolen¹, T. Geelen¹, K. Nicolay¹, and G. J. Strijkers¹

¹Biomedical NMR, Biomedical Engineering, Eindhoven University of Technology, Eindhoven, Netherlands

Purpose

Mouse models of (temporary) coronary artery occlusion are widely used to study specific processes after myocardial infarction, for instance cell death, inflammation and scar tissue formation. An emerging field is the application of molecular magnetic resonance imaging (MRI) for visualization of these molecular processes *in vivo*. The application of (target-specific) contrast agents provides new insights in disease progression and enables evaluation of emerging therapies. This adds to measurements of global and regional cardiac function, for which MRI is considered the gold standard. In this educational poster, we will give an overview on current applications of contrast agents in molecular imaging of myocardial infarction, as well as on the development of dedicated protocols for contrast-enhanced MRI of the mouse heart. To conclude, we will reflect on some future perspectives of molecular MRI of myocardial infarction.

Outline of contents

1. Introduction

An overview on mouse models of myocardial infarction and subsequent left ventricular (LV) remodeling processes will be given. Furthermore, the basic principles of molecular MRI will be discussed.

2. Molecular imaging of myocardial infarction

Cell death: Cell death of cardiomyocytes occurs in the acute phase after myocardial infarction. Imaging of different parameters has been explored: infarct size with small Gd-chelates [1], cell viability with manganese [2], and apoptotic cells with annexin A5-conjugated contrast agents [3].

Inflammation: In response to cell death, inflammatory cells migrate to infarcted myocardium. Besides the phagocytosis of dead cells, they promote LV remodeling. Macrophages have been visualized with iron oxides [4] and emulsions of perfluorocarbons [5]. Moreover, myeloperoxidases, which are secreted by neutrophils, have been imaged with an activatable Gd-probe [6].

Reparative processes: collagen-targeted Gd-based contrast agents [7] and paramagnetic quantum dots targeted against angiogenic vessels [8] have been used for the evaluation of LV remodeling.

3. MR protocols

Sequence characteristics: Several studies have dealt with the use of prospective versus retrospective triggering approaches, black-blood versus bright-blood imaging and parallel imaging.

T_1 - and T_2 -weighted imaging: Paramagnetic contrast agents are routinely visualized with T_1 -weighted sequences. The application of inversion recovery (IR) and steady-state gradient echo (GE) sequences has been evaluated [9]. Furthermore, the optimal sequence parameters, timing after contrast agent injection and nulling mechanisms for healthy myocardium have been explored [10]. Iron oxides are imaged with T_2/T_2^* -weighted scans, which have been particularly optimized in terms of image quality and imaging time windows [3, 11].

T_1 and T_2 mapping: Although T_1 - and T_2 -weighted imaging can visualize the accumulation of contrast agent, T_1 and T_2 mapping are more powerful in terms of quantification. Lately, T_1 and T_2 mapping for mouse myocardium has been introduced [12, 13].

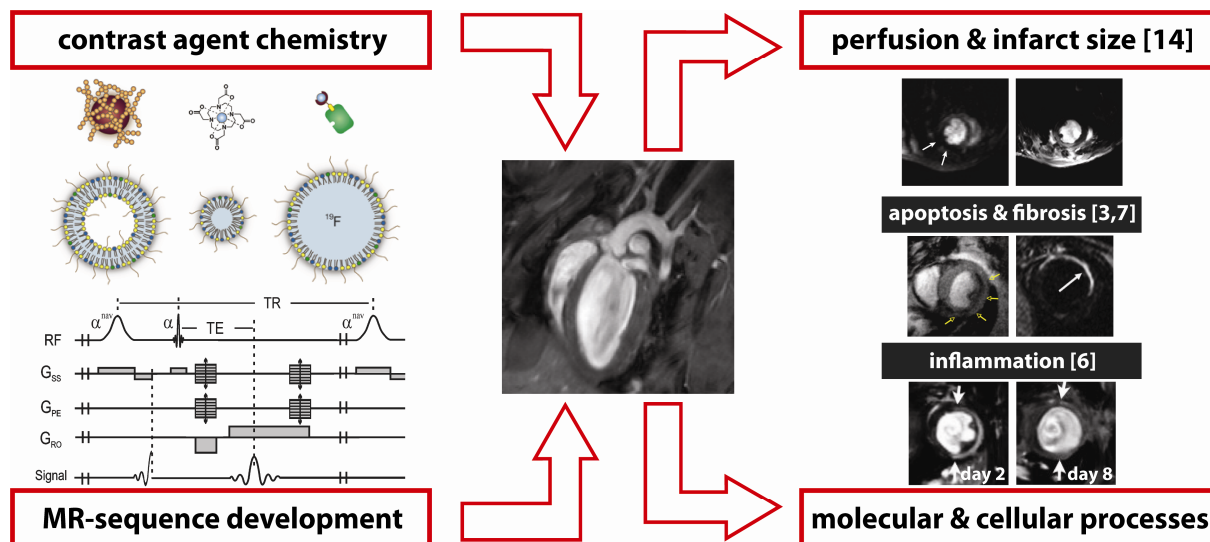
First-pass perfusion: Imaging of the first-pass of a bolus of contrast agent is a clinically used protocol to measure the perfusion status of the heart. Recently, this protocol has been implemented in mice using fast MR methods [14, 15].

4. Future perspectives

New or improved MRI protocols for mouse myocardial infarction imaging are still under development. Examples are UTE sequences for T_1 -weighted visualization of iron oxides or the application of diffusion tensor imaging (DTI) in the mouse heart to study cardiac remodeling.

Summary

Recently, major progress has been made in the field of molecular MRI of mouse myocardial infarction. Contrast agents have been designed and successfully applied to image cell death, inflammation and LV remodeling. To visualize these contrast agents, dedicated MRI sequences are required. Specifically, T_1 - and T_2 -weighted sequences have been optimized, quantitative T_1 and T_2 mapping protocols have been developed and first-pass perfusion measurements have been implemented. This has led to improved evaluation of biological processes after myocardial infarction.



Key references

[1] Yang, Circulation 2004
[2] Hu, NMR Biomed 2004
[3] Sosnovik, Circ Cardiovasc Imaging 2009
[4] Yang, Magn Reson Med 2010
[5] Flögel, Circulation 2008

[6] Nahrendorf, Circulation 2008
[7] Helm, Radiology 2008
[8] Oostendorp, Circulation 2010
[9] Protti, J Magn Reson Imaging 2010
[10] Bohl, Am J Physiol – Heart C 2009

[11] Beyers, J Cardiovasc Magn R 2010
[12] Coolen, NMR Biomed 2010
[13] Schneider, J Magn Reson Imaging 2003
[14] Coolen, Magn Reson Med 2010
[15] Makowski, Magn Reson Med 2010