

Non-contrast-enhanced Hepatic MR Angiography with Time Spatial Labeling Inversion Pulse

H. Isoda¹, T. Okada¹, K. Shimada¹, S. Kawahara¹, H. Shimizu¹, and K. Togashi¹

¹Kyoto University, kyoto, kyoto, Japan

Purpose

The aim of this presentation is to describe the theory and features of non-contrast-enhanced hepatic MR angiography sequences, including balanced steady-state free-precession (bSSFP) and half-Fourier fast spin-echo (FSE), and time spatial labeling inversion pulse (T-SLIP) method. In this exhibit, we also introduce the various techniques to selectively visualize the hepatic vessels with T-SLIP and demonstrate new developments on the horizon, including 3T non-contrast-enhanced hepatic MR angiography.

Outline of content

1. To describe features of bSSFP and half-Fourier FSE on non-contrast-enhanced hepatic MR angiography, and important parameters influencing image quality.
2. To show technical basis of T-SLIP.
3. To demonstrate appropriate T-SLIP placement and setting of the inversion time which are important factors for selective visualization of the hepatic vessels.
4. To show non-contrast-enhanced hepatic MR angiography in healthy volunteers; hepatic MR arteriography, hepatic MR venography, and hepatic MR portography respectively (Fig. 1-3).
5. To present new useful techniques to improve image quality and limitation of non-contrast-enhanced hepatic MR angiography with T-SLIP technique.
6. To demonstrate non-contrast-enhanced hepatic MR angiography at 3T.

Summary

T-SLIP can provide selective inflow information by placing the inversion pulse anywhere. Optimized application of T-SLIP with non-contrast-enhanced hepatic MR angiography enables successful selective visualization of hepatic vessels. The inversion time, appropriate location and width of the inversion pulses are the important factors. Shortening of the acquisition time for selective hepatic vessel visualization is feasible without deterioration of the image quality by combined usage of STIR and 2D-pararell imaging methods. This method will open a new way for further use of non-contrast-enhanced hepatic MR angiography.

Figure 1. The hepatic artery images the same TI of 1200 msec in time-SLIP bSSFP with STIR fat suppression. The signal of the liver parenchyma is well suppressed with the STIR technique. Some branches of the hepatic artery are well depicted on the STIR image.

Figure 2. Successful selective visualization of the hepatic venous system without contrast administration using T-SLIPs. The hepatic vein and the IVC were both well visualized. Also, a large accessory right hepatic vein of 9.5 mm in diameter, draining liver segment VI, flows directly into the IVC. Signal suppression of the portal venous signal at periphery was also sufficient.

Figure 3. MR portography with true SSFP. Signals of the hepatic arterial and venous system are well suppressed and the portal venous system is selectively visualized in detail without an exogenous contrast agent.

Fig. 1

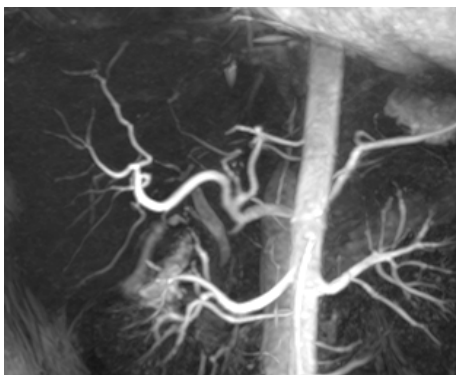


Fig. 2

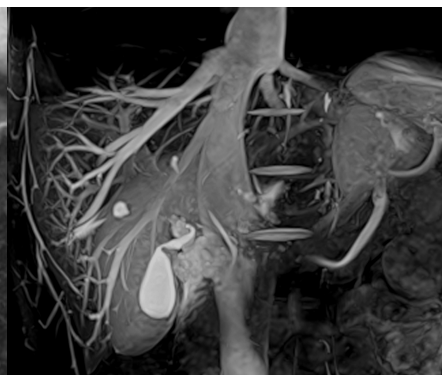


Fig. 3

