

## A multimodal imaging study of never-medicated adults with schizophrenia

E. Canu<sup>1</sup>, R. Gasparotti<sup>2</sup>, F. Agosta<sup>1</sup>, P. Valsecchi<sup>3</sup>, G. Comi<sup>4</sup>, E. Pagani<sup>1</sup>, E. Sacchetti<sup>3</sup>, and M. Filippi<sup>1</sup>

<sup>1</sup>Neuroimaging Research Unit, Institute of Experimental Neurology, Division of Neuroscience, Scientific Institute and University Hospital San Raffaele, Milan, Italy; <sup>2</sup>Department of Diagnostic Imaging, University of Brescia, Spedali Civili, Brescia, Italy; <sup>3</sup>Department of Psychiatry, Brescia University School of Medicine, Brescia, Italy; <sup>4</sup>Department of Neurology, Scientific Institute and University Hospital San Raffaele, Milan, Italy

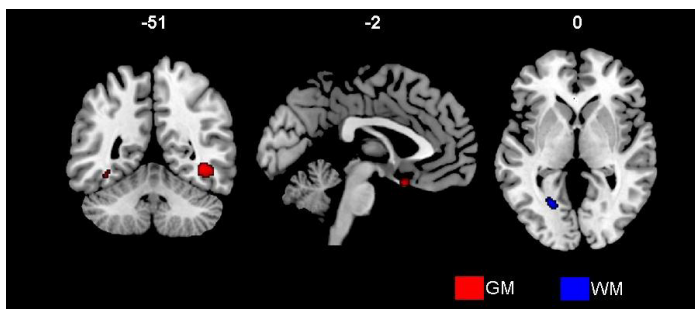
**Introduction.** Recent imaging studies showed grey (GM) and white (WM) matter abnormalities in patients with schizophrenia compared with healthy controls<sup>1</sup>. However, these findings are not consistent, probably due to the effect of antipsychotic treatment and clinical heterogeneity of the samples<sup>2</sup>.

**Objective.** To explore both volume loss and microstructural diffusion changes in adult patients with schizophrenia that never have been medicated.

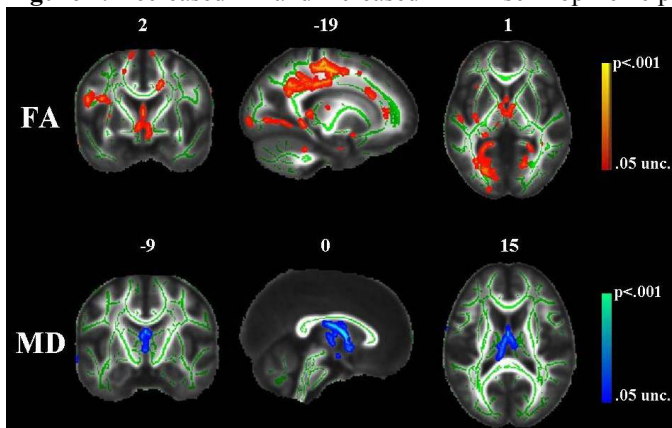
**Methods.** Thirty-seven never-medicated schizophrenic patients (age  $32.6 \pm 10.9$ , women 48%) and 17 age- and gender-matched healthy controls (age  $29.8 \pm 8.3$ , women 35%) were studied. Schizophrenia was diagnosed according to the DSMIV criteria and patients were invited to participate in the study before starting any treatment. All participants underwent 3D T1-weighted and diffusion tensor (DT) MRI scans. Voxel Based Morphometry (VBM) in Statistical Parametric Mapping (SPM8) was used to obtain GM and WM volume loss differences in patients vs. healthy controls. Tract-based spatial statistics (TBSS) in FSL was used to compare mean diffusivity (MD), fractional anisotropy (FA), as well as axial (axial D) and radial (radial D) diffusivity maps between groups.

**Results.** Compared with controls, schizophrenic patients showed GM volume loss in the middle temporal lobe bilaterally, with a predominant involvement of the right side, and WM volume loss in a region underneath the left lingual gyrus (**Figure 1**). Patients compared to controls showed increased MD in the fornix, while decreased FA was found in the body and splenium of the corpus callosum, posterior cingulum, and parahippocampal region bilaterally (**Figure 2**). The pattern of increased radial D in patients vs. controls resembled that of decreased FA, while increased axial D was found in the fornix only.

**Figure 1.** Gray and white matter volume loss in schizophrenic patients vs. healthy controls



**Figure 2.** Decreased FA and increased MD in schizophrenic patients compared to healthy controls.



**Conclusion.** This is the first study investigating both volumetric and microstructural diffusion changes in a never-medicated sample of adults patients with schizophrenia. Schizophrenic patients demonstrated a complex pattern of parieto-temporo-occipital damage. This pattern is consistent with regions well known to be related to the typical auditory hallucinations<sup>3</sup>, and neurofunctional networks thought to be involved in the pathophysiology of schizophrenia.

**References.** 1. Shenton et al. *Dialogues Clin Neurosci* 2010 12:317-32; 2. Honea et al. *Am J Psychiatry* 2005;162:2233-45; 3. Jardri et al. *Am J Psychiatry* Epub Ahead of Print