

Quantitative Assessment of the Cortico-Spinal Tracts in Neonates With Congenital Heart Disease Following Cardiopulmonary Bypass Surgery.

M. I. Makki¹, R. Liamlahi², H. Dave³, I. Scheer¹, W. Knirsch², B. Latal⁴, A. Schmitz⁵, V. Berner⁶, and C. Kellenberger¹

¹Diagnostic Imaging, University Children Hospital, Zurich, Switzerland, ²Cardiology, University Children Hospital, Zurich, Switzerland, ³Congenital Cardiovascular Surgery, University Children Hospital, Zurich, ⁴Child Development Center, University Children Hospital, Zurich, Switzerland, ⁵Anesthesia, University Children Hospital, Zurich, Switzerland, ⁶Pediatric Intensive Care, University Children Hospital, Zurich, Switzerland

Introduction: It has been shown that cerebral lesions in patients with congenital heart disease (CHD) may occur during fetal life, after birth or before, during and after cardiopulmonary bypass surgery (CPB) with a high incidence of neurocognitive and neuromotor deficits in infancy, childhood, and adolescence [1, 2]. Studies of microstructural development of fiber bundle integrity and maturation of white matter (WM) myelin (internal capsule, frontal lobe, posterior lobe, cortico-spinal tracts etc.) have been performed bilaterally on healthy neonates [3-5] and infants [6, 7]. These studies showed a symmetric development of neonate and infants brain. Brain DTI studies demonstrated a left-right asymmetry in the posterior limb of the internal capsule of extremely-low-birthweight preterm [8], but not in extremely preterm infants [9]. The aim of this study was to apply advanced diffusion tensor imaging (DTI) to investigate whether or not the cortico-spinal tracts of neonates with CHD are asymmetrically developed following CPB.

Material and Methods: Single shot spin-echo EPI with double refocusing pulses and parallel imaging (factor of 2) was performed on 3T scanner with sensitization gradients ($b = 700 \text{ s/mm}^2$) applied in 35 non-collinear directions and one T2W scan. All patients were monitored by an anesthesiologist in the scan room. To reduce exposure to acoustic noise neonatal ear muffs were used in addition to ear plugs. Full MRI exam was successfully acquired in seven patients presurgically and in six post-surgically. For DTI indices, manual structural delineation of the cerebral peduncles (CP) the corticospinal tracts (CST), and the posterior limbs of the internal capsule (PLIC) was achieved bilaterally by 2 independent observers. Parallel diffusion (λ_1), averaged perpendicular (λ_{23}) diffusion, apparent diffusion coefficient (ADC) and fractional anisotropy (FA) were measured in each selected structure in both hemispheres using DTIstudio software (H. Jiang and S. Mori; Johns Hopkins University; <http://mrstudio.org>). Repeated measures analysis of covariance was performed separately for the CST, PLIC and CP. Side was entered as within-subject variable, pre and post surgery as between-subject variables, and age at the time of MRI acquisition as covariate.

Results: There was no significant difference (λ_1 , λ_{23} , ADC and FA) between left and right side neither in the CP nor in the CST. In addition we did not observe any significant difference for these structures when comparing side-by-side the 2 groups (pre vs post surgery). However, it is noteworthy to say that there was a bilateral increase of λ_{23} and decrease of FA in post-surgical scan compared to the pre-surgical scans but this did not reach significance. In healthy neonates we expect the opposite pattern due to WM maturation. In the PLIC there was a significant side effect seen on parallel diffusion within the pre-surgery group: $\text{left } \lambda_1 < \text{right } \lambda_1$, ($p = 0.005$) yielding a significant difference in anisotropy with $\text{left } FA < \text{right } FA$, ($p = 0.003$). This anisotropic asymmetry was maintained within the post-surgery group as well: $\text{left } FA < \text{right } FA$, ($p = 0.022$).

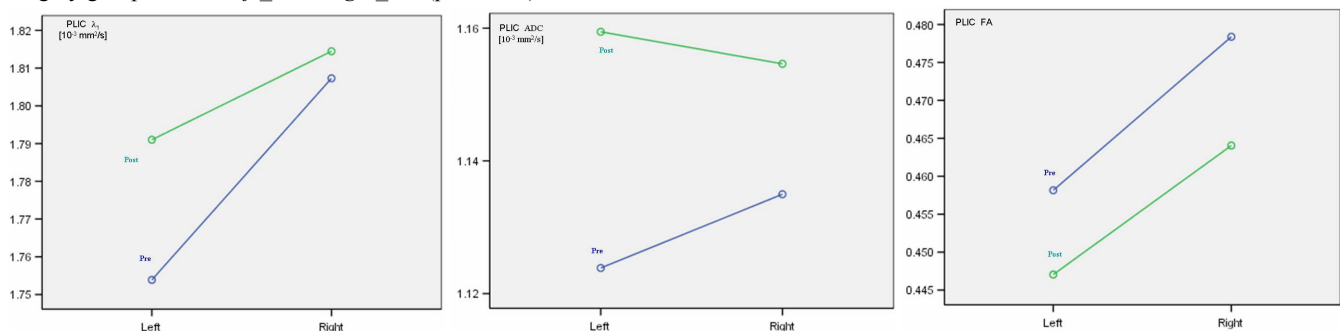


Figure 1: Estimated marginal means showing the PLIC has an asymmetric perpendicular diffusion pre-surgery (A), whilst ADC is symmetric with no group difference (pre vs post). The FA was asymmetric pre and post surgery with left smaller than right.

Conclusion: Myelin maturation of motor pathway is a hallmark of WM maturity and few studies have reported delayed brain myelination and perinatal WM injury of the whole brain [10, 11]. To the best of our knowledge, this is the 1st study showing that altered WM structures in the PLIC of neonates with CHD have a hemispherical predominance. Asymmetric myelination of the PLIC has been shown to be a strong indicator for future hemiplegia in children with periventricular hemorrhagic infarction [12]. This delay might be the origin of fine motor dysfunction reported for children with CHD.

References: [1] Majnemer A, *J Pediatr* (2006); [2] Licht DJ, *J Thorac Cardiovasc Surg* (2009); [3] Huppi PS, *Pediatr Res* (1998); [4] Gao W, *AJNR* (2009); [5] Gilmore JH, *Am J Neuroradiol* (2007); [6] McGraw P, *Am J Roentgenol* (2002); [7] Rose J, *Dev Med Child Neurol* (2009); [8] Anjari M, *Neuroimage* (2007); [9] Skiold B, *Acta Paediatrica* (2010); [10] Limperopoulos C, *J Pediatr* (2000); [11] Miller SP, *N Eng J Med* (2007); [12] De Vries LS, *Neuropediatrics*, (1999).