

## Pain or no pain: Paradigm to image lower back pain with fMRI

H. A. Sharma<sup>1</sup>, R. Gupta<sup>2</sup>, and W. Olivero<sup>3</sup>

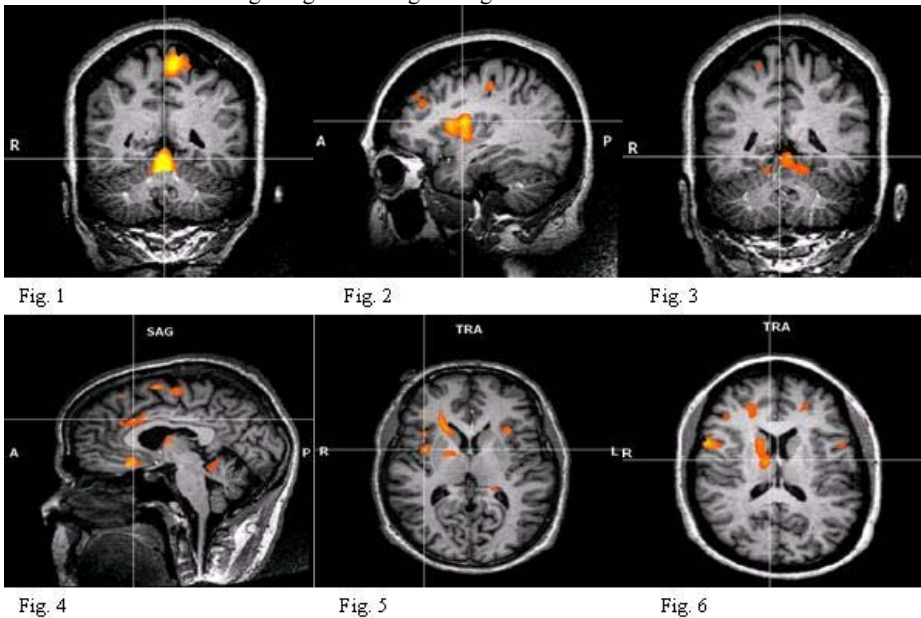
<sup>1</sup>Department of Medical Biophysics, University of Western Ontario, London, ON, Canada, <sup>2</sup>Medicine, University of Illinois, <sup>3</sup>Neurosurgery, Carle Foundation Hospital

### Introduction:

Low back pain affects millions of patients. fMRI studies have made significant contributions to the understanding of how the brain processes pain. However, most of the studies have involved normal subjects subjected to painful stimuli during fMRI. Studying patients with acute pain has been difficult because of motion artifact and the difficulty in altering the patients painful experience during fMRI. We elected to study patients with back pain and radiculopathy from a herniated disc at the L4-5 or L5-S1 levels using various maneuvers like leg raise, dorsiflexion of the foot and tensing of the muscles of thigh in an attempt to alter the pain perception to determine if we could reliably obtain fMRI images when the patients pain scale rating changed during the maneuvers.

**Methods:** Back pain patients were imaged in a 3T Siemens Allegra scanner using a single channel quadrature coil. A Block design was used for fMRI stimulus design. The blocks consisted of 20s task and 20s rest. Task included dorsiflexion of right foot, muscle tensing of right foot, and right leg raise. A T2\*-weighted EPI sequence (TR/TE/FA = 2000ms/30ms/77°) was used to acquire whole brain volumes (32 slices) at a voxel dimension of 3.8x3.8x4. High resolution T1-weighted anatomical images were acquired with an MPrage sequence. fMRI data were analyzed using Brainvoyager QX. The standard sequence of preprocessing steps were performed for the fMRI data, including slice scan time correction, high pass filtering and spatial smoothing. 3D head motion correction was performed to detect and correct for small head movements. Estimated translation and rotation parameters were inspected. In order to account for hemodynamic delay and dispersion, each of the predictors was derived by convolution of an appropriate boxcar waveform with a doublegamma hemodynamic response function Using hypothesis driven, voxelwise standard analyses (GLM), we tested for overall task related effects.

**Results:** Figure 1- 6 summarize the main results of the hypothesis driven GLM analysis. Significant effect of pain from right leg raise was seen in the thalamus, caudate, anterior cingulate and insula (fig 4,5 6). Figure 1 and 2 show cerebellum and insular activity for back pain induced by tightening the muscles of right leg. Figure 3 shows cerebellum activity for dorsiflexion of right foot. Figure 1 also shows the cerebral motor activation in the left motor cortex due to the right leg muscle tightening.



### Conclusions:

After inspecting the motion files from the fMRI data, we determined that the maneuvers we used to induce differential pain in the block design did not create large motion artefacts that prevented analyses and interpretation. Any motion that was present was easily corrected by motion correction algorithm in Brainvoyager QX. Thus, we are now confident that these maneuvers can be used in the block design for the fMRI experiments to study pain processing. In terms of data analysis, we observed cerebral activation in the thalamus, caudate, cerebellum and insula during maneuvers that elicited pain. During no-pain maneuver there were no activations in those regions.

### References:

(1) Apkarian, A (2005), *Eur Journal of Pain*, 9: 463-484. (2) Huettel, S(2001), *Functional MRI*, Sinauer publisher (3) Jeanmonod, D(1993), *Neuroreport*, 4: 475-478 (4) Marwan, N (2006) *Journal of Neuroscience*, 26( 47):165-173.