

Proton spectroscopy for lipid characterisation in paediatric brain tumours

A. Napolitano¹, F. Savvopoulos¹, T. Jaspán², R. G. Grundy², and D. P. Auer¹

¹Academic Radiology, University of Nottingham, Nottingham, Nottinghamshire, United Kingdom, ²The Children's Brain Tumour Research Centre, University of Nottingham, Nottingham, Nottinghamshire, United Kingdom

Introduction:

Brain tumours in children represents about 25-30% of all cancers. Functional imaging with MRI such as proton MRS is increasingly used for lesion characterisation. MRS provides a noninvasive biochemical profile of the tumour tissue with typical patterns for high and low grade tumours and contributory information for the differential diagnosis and prognosis of brain lesions. Pilocytic astrocytoma (PA), the most common low grade glioma in childhood, however, may show imaging, metabolic and histopathological features which are commonly attributed to more malignant tumours. There are reports on hypermetabolism [1-2], high Choline [3] and high lipids [4] in PA. The high lipid content could be particularly confusing as it is considered to be a marker of necrosis and typically only seen in highly aggressive tumours. Mobile lipids in particular are typically considered to indicate necrosis [5] and differences in the lipid pattern were observed between high grade gliomas and metastasis in adults [6]. Necrosis is not a feature of PA at the histopathological level, hence we hypothesise that the signal pattern detected in the lipid range in patients with PA is different from that present in high grade tumours suggesting different underlying biochemical composition.

Methods:

¹H-MRS was performed in children with brain tumours as part of the CCLG clinical MR protocol. A total of 26 patients (10 ± 5 years 3-15 years of age) with histologically proven brain tumours were included: 9 Pilocytic Astrocytomas (PA); 8 low grade gliomas (LGG), and 9 high grades (HG) (Germinoma, Pineoblastoma, Glioblastoma, Medulloblastoma, anaplastic Ependymoma, PNET). Parents gave informed consent for all participating patients. Data analysis MRS was acquired with a standard PRESS sequences (TE=35 ms, TR=2s, NSA=1024, voxel size=3.4±2 ml). MRI was performed on a 3.0 T Philips Achieva MR scanner at time of diagnosis prior to any chemotherapy, radiotherapy, biopsy or surgery. Spectra were analyzed using LCModel to fit individual metabolites, macromolecules and lipids (see Figure 1). Two-tailed t-tests were performed using Matlab statistic toolbox to investigate differences between the three groups (PA, LGG, HG). The fitted components were also averaged for display purposes.

Results:

Due to the highly unreliable fitting of the separate components of the broad visible peaks resonanting at about 1.3 and 0.9 ppm only sums of them (Lip+MM) as reported by LCModel fit were used for tumour differentiation. Using The peak resonanting roughly at 1.3 ppm was referred as the sum of Lip13+Lip14+MM14+MM12 (Lipid13) whereas those resonanting at 0.9 ppm as MM09+Lip09 (Lipid09). Pilocytic astrocytomas showed similarly high levels of Lipid09 and Lipid13 compared to HG tumours. In contrast, the Lipid09/Lipid13 ratio differed between PA and HG with relatively higher ratios for PA (PA: 0.46 ±0.12; HG: 0.33±0.10, $p<0.035$). PA differed from LGG by showing higher Lipid13 concentrations (PA: 19.49±6.88 a.u.; LG: 13.50±5.40 a.u.; $p<0.036$). As expected, LG differed from HG showing significantly lower concentrations of Lipid13 (high grade: 46.01±38.32 a.u.; low grade: 13.50±5.40 a.u.; $p<0.03$), a trend for lower Lipid09 ($p<0.06$), and a significantly higher 0.9/1.3 ratio (low grade: 0.34±0.10; high grade: 0.54±0.12; $p<0.004$) (see Figure 2).

Discussion:

This study confirms elevated lipid signals in pilocytic astrocytomas and high grade pediatric brain tumours. When computing the ratio of Lipid09/Lipid13 signals, we were able to characterise different lipid tumour profiles that allowed us to differentiate pilocytic astrocytomas from high grade paediatric brain tumours. The use of the ratio of Lipid09/Lipid13 in characterizations of brain tumours have been previously described in adults (6). The elevated lipid signals, especially Lip13 are in line with the hypothesis that Lip-MM originate from necrotic tissues as suggested in previous study showing a correlation between tumour grade and lipids contents [7]. Interestingly, pilocytic astrocytoma revealed a difference in the ratio compared to high grade tumours suggesting differences in the biochemical composition. It is conceivable that the relatively higher peaks at 0.9 are a consequence of elevated macromolecules in addition to lipid accumulation in patients with PA. It remains to be tested whether large amounts of macromolecules are present in PA causing thus an increase on the visible 'lipid' peak. Alternatively, it is also plausible that the lipid profile is different in terms composition, size and mobility between PA and HG. As we only have acquired short echo time spectra, we cannot assess any T_2 differences rising from differences in lipids and macromolecules' composition, size and mobility. Similar to what was suggested in adults, the observed difference may be TE-dependent, and further investigations such as HMAS are warranted to understand the nature of the observed differences. In conclusion, we have shown that calculation of the 0.9/1.3 lipid ratio may be useful to differentiate pilocytic astrocytoma from high grade pediatric brain tumors.

References:

[1] Allen M. Kaplan Neurosurg Focus 8 (2000) [2] Daniel D. et al. The journal of Nuclear Medicine 41 (2000) [3] Porto L. et al. Childs Nerv. System. 26 (2010) [4] Kovanlikaya A. et al. Radiology 236 (2005) [5] Kirstie S. et al. NMR Biomed. 21 (2008) [6] Kirstie S. et al. JMRI (2004) 20: 187-192 [7] Kuesel et al. NMR Biomed. 7 (1994).

Acknowledgement : This work was funded by a CRUK/EPSRC/MRC/NIHR Cancer Imaging Programme Grant.

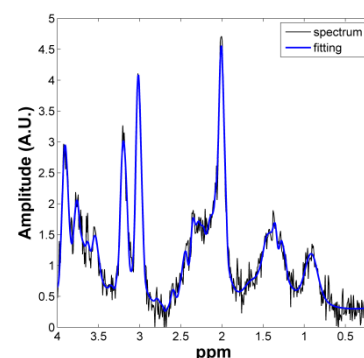


Figure 1: Pilocytic Astrocytoma spectrum Lipid13 and Lip09 are visible in the spectrum

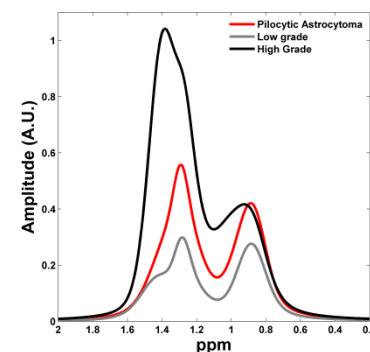


Figure 2: Illustration of the LCModel fitting of Lipid13+Lip09 for the three cases described. The spectra are averaged across all the subjects and normalized by voxel size