

The visual ventral stream in posterior cortical atrophy

F. Agosta¹, R. Migliaccio^{1,2}, E. Pagani¹, E. Canu¹, S. Sala¹, F. Caso³, G. Magnani³, A. Marcone⁴, S. Cappa^{4,5}, E. Scola⁶, A. Falini⁶, G. Comi³, P. Bartolomeo², and M. Filippi¹

¹Neuroimaging Research Unit, Institute of Experimental Neurology, Division of Neuroscience, Scientific Institute and University Hospital San Raffaele, Milan, Italy,

²U975 Centre de Recherche de l'Institut du Cerveau et de la Moëlle Epinière, INSERM, Paris, France, ³Department of Neurology, Scientific Institute and University Hospital San Raffaele, Milan, Italy, ⁴Department of Clinical Neurosciences, San Raffaele Turro Hospital, Milan, Italy, ⁵Vita Salute University, Milan, Italy,

⁶Department of Neuroradiology and CERMAC, Scientific Institute and University Hospital San Raffaele, Milan, Italy

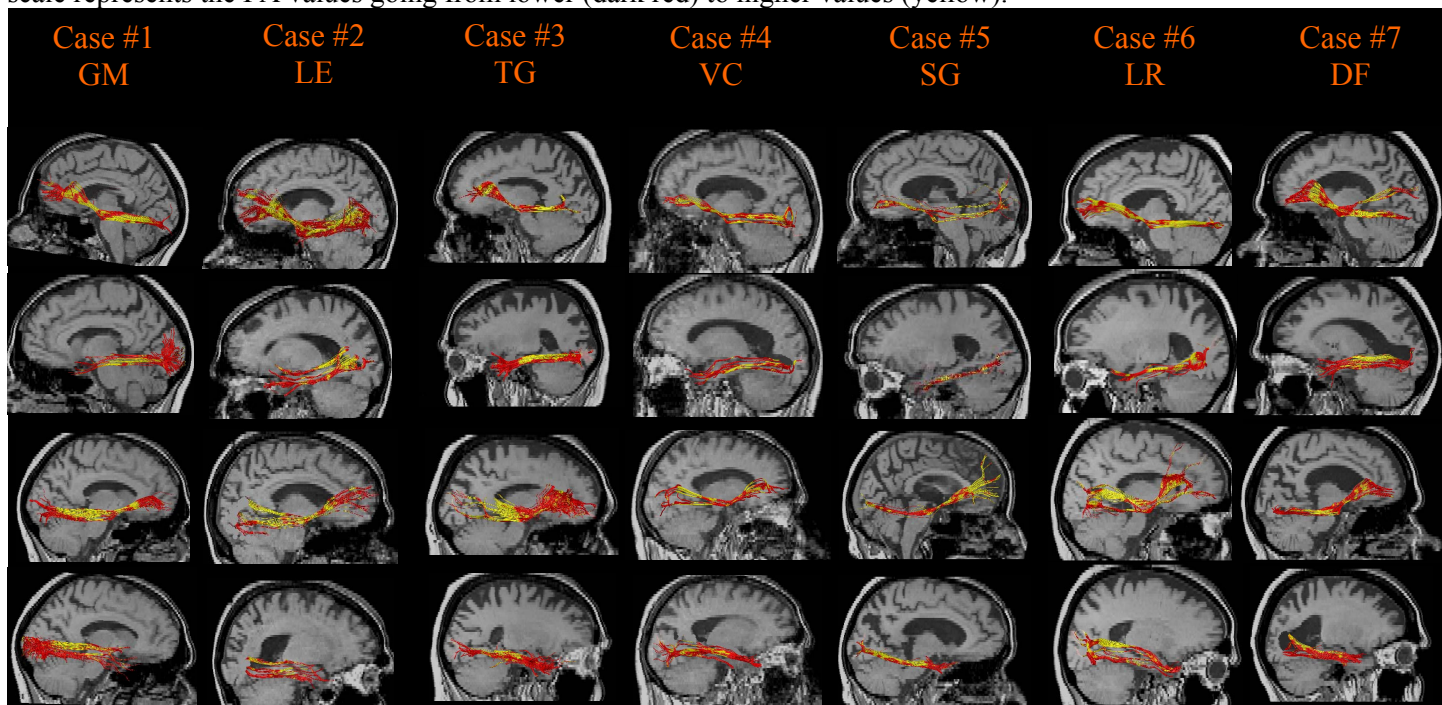
Introduction. Posterior cortical atrophy (PCA) is a neurodegenerative condition, which typically presents with visual and visuo-motor symptoms reflecting a widespread posterior cerebral dysfunction [1,2]. The classification into dorsal and ventral subtypes has been proposed.

Objective. To explore the structural integrity of brain networks underlying the cognitive deficits in patients with PCA.

Methods: Clinical, cognitive, and structural and diffusion tensor (DT) MRI data were collected from seven PCA patients. Using DT MRI tractography [3], bilateral inferior longitudinal (ILF), inferior fronto-occipital (IFOF), arcuate, and fronto-parietal superior longitudinal (SLF) fasciculi were obtained in patients and 13 healthy controls (HC). The corpus callosum (CC) and cortico-spinal tracts (CST) were also studied. From each tract, mean diffusivity (MD), fractional anisotropy (FA), as well as axial and radial diffusivity (D) were obtained. Grey (GM) and white matter (WM) atrophy was assessed using voxel-based morphometry.

Results: PCA patients showed a clinical syndrome mainly characterized by visual agnosia and prosopagnosia. Compared with HC, patients had significantly higher MD, axial D, and radial D, and lower FA in left ILF and IFOF. Right ILF demonstrated significantly higher MD and radial D and lower FA, and the CC showed higher MD relative to HC. On the contrary, fronto-parietal SLF, arcuate fasciculus, and CST were spared, bilaterally. When compared to HC, PCA showed GM atrophy in posterior bilateral temporal, inferior parietal and occipital cortices, and WM atrophy in the right ventral occipito-temporal region. WM tract microstructural changes were not related to WM atrophy.

Figure. Inferior fronto-occipital and inferior longitudinal fascicule are rendered as maps of FA in all patients. The color scale represents the FA values going from lower (dark red) to higher values (yellow).



Conclusions. PCA patients showed damage to the ventral visual WM pathways of both hemispheres, with relative sparing of dorsal fronto-parietal connections. In agreement with these findings, the patients showed mainly deficits on recognizing faces and objects. These results may contribute to our understanding of the anatomical changes that occur in PCA and to explaining the variability of the phenotypical expressions of the disease.

References. [1] Benson et al., Posterior cortical atrophy. Arch Neurol 1988;45:789–793. [2] Migliaccio et al., Neurology 2009;73:1571-8. [3] Catani et al., Cortex 2008;44:1105-32.