

Thalamic Microstructural Changes in Neonates with Congenital Heart Disease: A DT-MRI Study Before and After Cardiopulmonary Bypass Surgery.

M. I. Makki¹, R. Liamlahi², B. Latal³, W. Knirsch², H. Dave⁴, A. Schmitz⁵, V. Bernet⁶, C. Kellenberger¹, and I. Scheer¹

¹Diagnostic Imaging, University Children Hospital, Zurich, Switzerland, ²Cardiology, University Children Hospital, Zurich, Switzerland, ³Child Development Center, University Children Hospital, Zurich, Switzerland, ⁴Congenital Cardiovascular Surgery, University Children Hospital, Zurich, ⁵Anesthesia, University Children Hospital, Zurich, Switzerland, ⁶Pediatric Intensive Care, University Children Hospital, Zurich, Switzerland

Introduction: Brain MRI studies of neonates undergoing open-heart surgery show in up to 50% white matter (WM) injury, cerebral infarctions, haemorrhages and decreased grey matter (GM) volume [1, 3]. The aim of this study was to investigate microstructural changes of the thalamus (TH) considered as a central relay station with extensive cortical connections using diffusion tensor MRI (DT-MRI). We hypothesized that neonates with severe congenital heart disease (CHD) suffering from brain injury and WM impairment at birth and during cardiopulmonary bypass (CPB) surgery may also show an abnormal development of their thalamus which may serve as imaging marker for possible later neurological dysfunction.

Materials and Methods: DT-MRI was carried out on a 3T scanner using single shot spin-echo echo-planar imaging with double RF pulses and parallel imaging factor of 2. We prescribed 35 gradient directions (sensitization gradient $b = 700 \text{ s/mm}^2$), FOV=22 cm, matrix = 128x128 size reconstructed on 256x256 using homodyne and slice thickness = 2.5 mm covering the whole brain. All our patients with d-type transposition of the great arteries ($n=8$) or hypoplastic left heart syndrome ($n=1$) undergoing CPB surgery in the neonatal period were born at term (mean gestational age = 39.2 ± 1.1 weeks, mean birth weight = 3230 ± 381 g) and were scanned in natural sleep after they were orally fed. Overall we successfully acquired 13 DT-MRI data sets: 7 pre-surgical, 6 post-surgical scans and among these 5 accomplished both. Images were processed with DTIStudio software (John Hopkins University, www.mristudio.org). Two GM structures were selected: the thalamus and the head of the caudate nucleus (CN). Manual ROI were carefully drawn on axial images by 2 observers (one did test re-test) to reduce subjectivity of manual ROI drawing. The 3 measurements were combined in one value and repeated measures analysis of variances was performed with the level of statistical significance fixed to $p = 0.05$. Age at MRI was entered as a covariate and MRI (*pre vs post*) was entered as between-subjects factor.

Results: Both intra- and inter-rater reliabilities for minor, middle and major eigenvalues (λ_1 , λ_2 , and λ_3) were very high with correlation coefficients higher than 0.94. As expected we did not observe any significant side effect on the CN neither before nor after cardiopulmonary bypass. In addition there was no significant change in the microstructure of the CN due to surgical procedure. In the pre-surgery group, the left TH showed a significantly lower parallel diffusion ($p = 0.022$) and a significantly higher perpendicular diffusion ($p < 0.001$) compared to the right side. The mean diffusion and the anisotropy were symmetrical. In the post-surgical group we noticed an asymmetry in the parallel diffusion with left $\lambda_1 < \text{right } \lambda_1$ ($p = 0.030$) as well as in the anisotropy left FA < right FA ($p = 0.018$).

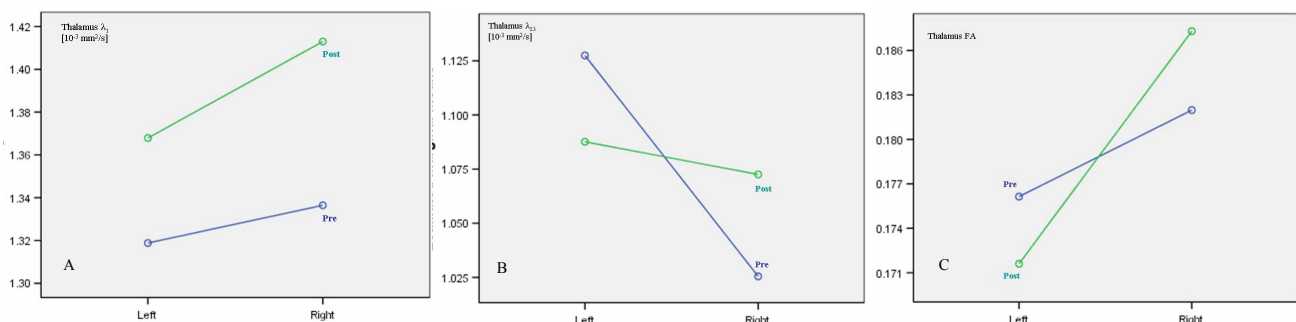


Figure 1: Estimated marginal means demonstrating the significant parallel diffusion differences (A) between left and right sides on pre-surgical ($p = 0.022$) and post-surgical ($p = 0.030$) MRI. On (B) we can clearly appreciate the significant left-right difference ($p = 0.001$) on pre-surgery perpendicular diffusion, and on (C) one can also observe the significant post-surgery difference between left and right anisotropy ($p = 0.018$).

Conclusion: Microstructural impairment of the TH in neonates with CHD has not been evaluated so far. Our study demonstrates a left-right asymmetry in the TH of neonates with CHD in both the pre-surgical (left $\lambda_1 < \text{right } \lambda_1$; left $\lambda_{23} > \text{right } \lambda_{23}$) and post-surgical groups (left $\lambda_1 < \text{right } \lambda_1$; left FA < right FA). The thalamus could be affected via hypoxic injury of white matter tracts connected to various thalamic nuclei, by neuronal loss or the expansion of extracellular space. Thalamic microstructural asymmetry obtained by DT-MRI may serve as a simple imaging marker of future neurological impairment in neonates with CHD.

References: [1] Licht DJ, *J Thorac Cardiovasc Surg*, (2009); [2] Watanabe K., *J Thorac Cardiovasc Surg*, (2009); [3] Mahle WT, *Circulation*, (2002).