

MULTIPARAMETRIC IMAGING OF RAT GLIOMA AFTER INTRA TUMORAL INJECTION OF CODBAIT, A SMALL MOLECULE MIMICKING DNA DAMAGE FOR SENSITIZING TUMORS TO RADIOTHERAPY

N. Coquery^{1,2}, N. Pannetier^{1,2}, R. Farion^{1,2}, D. Clarençon³, J.-S. Sun⁴, M. Dutreix⁴, E. Barbier^{1,2}, and C. Rémy^{1,2}

¹Grenoble Institute of Neuroscience, Grenoble, France, ²Université Joseph Fourier, Grenoble, France, ³Centre de Recherches du Service de Santé des Armées, La Tronche, France, ⁴Institut Curie Hospital, Department of Translational Research, Orsay, France

Introduction. Tumor resistance to radiotherapy is often associated with enhanced DNA repair activity [1]. Short and stabilized DNA molecules (Dbait) have been recently proposed as an efficient strategy to inhibit DNA repair in tumor [2]. Dbait is thus a serious candidate to sensitize glioma to radiotherapy [3]. Here, we use Dbait coupled with cholesterol (CoDbait) to sensitize rat glioma to a fractionated radiotherapy. We characterize the effect of several treatment combinations on animal survival and tumor properties using *in vivo* multiparametric MRI [4,5].

Materials and methods. **Experimental design (Fig1A):** Fischer 344 rats (n = 44, 8 weeks old) were orthotopically implanted with RG2 Glioma (5.10³ cells) at day 0 (D0) under anesthesia. Treatment started 8 days after tumor implantation (D8). Treatment consisted of two intratumoral injections of CoDbait (10mg/mL) or vehicle (glucose 5%) by convection enhanced delivery (CED; 10 μ L, 2 μ L/min; D8-D14) followed each by one selective irradiation of the head under anesthesia (IR; 6 Gy; D9-D15). Four groups were performed: Vehicle, CoDbait, Vehicle+IR, CoDbait+IR. Anesthesia was always done with Isoflurane 2-2.5%. **Multiparametric MRI:** MRI was performed at 4.7 T (Avance III console; Bruker). T₂-weighted (T₂W) images were acquired at D7, D13 and D17 to determine tumor growth. Multiparametric analysis of tissue properties was performed before (D7) and two days after treatment (D17) on three regions of interest (ROIs): tumor, tumor periphery and contralateral striatum (Fig1B). The apparent diffusion coefficient (ADC) was mapped (TR/TE = 3000/28.6 ms, b=900 s/mm²). Vascular integrity was assessed by using a dynamic contrast enhanced MRI approach as previously described [5]. Briefly, multiple T1-weighted images (n = 60, 15.6 s per image) were acquired (TR/TE: 800/4.2 ms). After acquisition of ten baseline images, a bolus of Gd-DOTA (200 μ mol/kg, flushed with 250 μ L of saline) was administered through the tail vein. The Area Under Curve of Gd-DOTA (AUC_{Gd-DOTA}) was calculated with the consecutive 40 images. Relative Cerebral Blood Volume (CBV) and Vessel Size Index (VSI, [6]) were obtained from a second bolus injection using a first-passage approach with a spiral gradient echo, spin echo sequence (2 shots, TR/TE_{GE}/TE_{SE}:250/16.5/50.1 ms). The CBV value of the contralateral striatum ROI was set at 3%. **Statistic:** Log-rank test was used to detect statistical significance in survival. Repeated Measurement of ANOVA was performed with SPSS to detect significant effects on tumor properties of CoDbait, Irradiation or combined treatments. A p value < 0.05 was chosen as significant.

Results. **Survival (Fig2A):** Kaplan-Meier survival analysis revealed statistically significant prolongation of survival in the Vehicle+IR group (median, 22 days) compared with the Vehicle and CoDbait groups (median, 18 and 17 days respectively). This prolongation was larger in the CoDbait+IR group (median, 24 days) than in the Vehicle+IR group. **Tumor growth (Fig2B):** CoDbait treatment reduced tumor growth between D7 and D13 whereas irradiation reduced tumor growth between D13 and D17. **Multiparametric MRI (Fig3):** No difference was observed in the contralateral striatum between groups and over time. Irradiation reduced CBV and VSI in tumor between D7 and D17 whereas CoDbait treatment increased ADC in tumor periphery between D7 and D17.

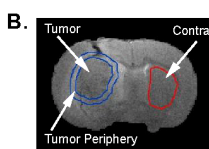
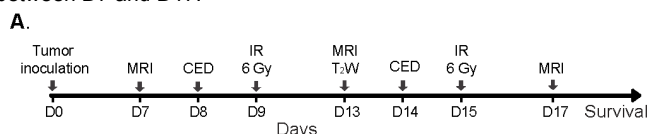


Figure 1 A. Experimental Design. CED: intra-tumoral injection by convection enhanced delivery, IR: head irradiation of 6 Gy, MRI: multiparametric MRI, MRI T₂W: anatomic MRI. B. T₂W image with depicted ROIs.

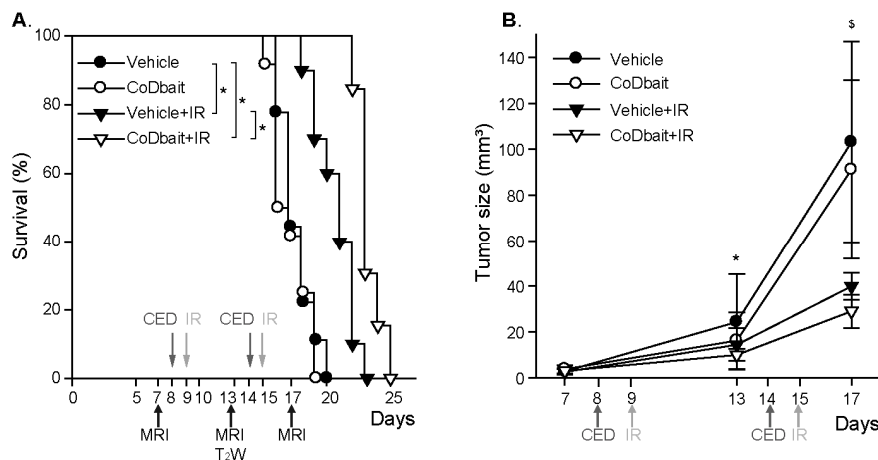


Figure 2 Effect of CoDbait and Irradiation on animal survival and tumor growth. A. Kaplan-Meier survival plot, *: p<0,05. B. Tumor size measured with T₂W MRI during treatment. *: effect of CoDbait between day 7 and 13, p<0,05. \$: effect of irradiation between days 13 and 17, p<0,05. Mean +/- SD.

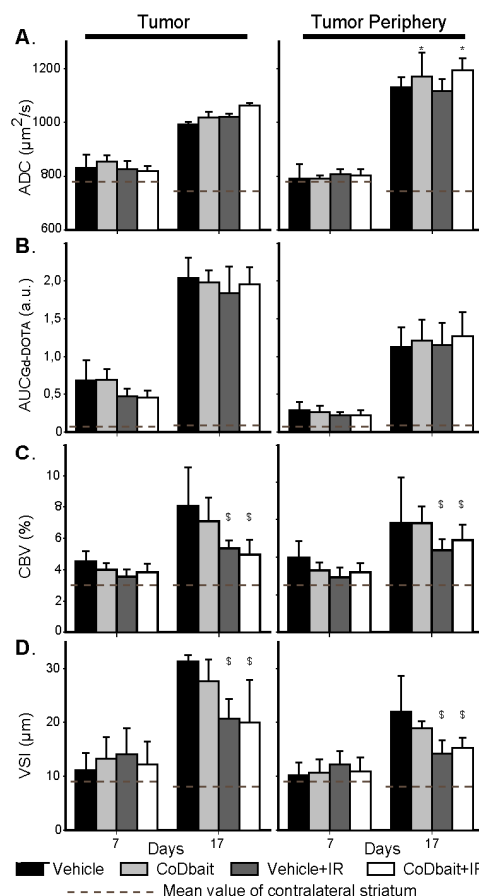


Figure 3 Effect of CoDbait and Irradiation on tumor properties determined by multiparametric MRI. A. ADC: Apparent Diffusion Coefficient. B. AUC_{Gd-DOTA}: Area Under Curve of Gd-DOTA extravasation. C. CBV: percentage of Cerebral Blood Volume. D. VSI: Vessel Size Index. *: effect of CoDbait between day 7 and 17, p<0,05. \$: effect of irradiation between days 7 and 17, p<0,05. Dotted line: mean value of contralateral striatum. Mean +/- SD.

Conclusion: These results show that multiparametric MRI is suited to depict a differential impact of combined treatments on tumor properties. The effective impact of CoDbait on animal survival seems to be related to an effect on tumor proliferation rather than on tumor microvasculature. Conversely, irradiation induces multiple effects on tumor growth and tumor vasculature.

References: [1] Otomo et al., *J. Radiat. Res.*, 2004; [2] Quanz et al., *PLoS One*, 2009; [3] Quanz et al. *Clin. Cancer Res.*, 2009; [4] Beaumont et al., *JCBFM*, 2009; [5] Lemasson et al., *Radiology*, 2010; [6] Kisselev et al., *MRM*, 2005.