

Hydrocephalus detection using intrinsically-activated MRE

K. D. Paulsen^{1,2}, A. J. Pattison¹, I. M. Perreard³, J. B. Weaver^{1,3}, and D. W. Roberts³

¹Thayer School of Engineering, Dartmouth College, Hanover, New Hampshire, United States, ²Norris Cotton Cancer Center, Lebanon, New Hampshire, United States, ³Dartmouth-Hitchcock Medical Center, Lebanon, New Hampshire, United States

Introduction:

Hydrocephalus (HC) is a disease characterized by obstruction of cerebrospinal fluid (CSF) flow in either the lateral ventricles (non-communicating) or subarachnoid space (communicating), resulting in an increase in ventricular size and a subsequent increase in intracranial pressure (ICP). Currently, magnetic resonance imaging or computed tomography assist in diagnosis, but these imaging studies only detect ventricular enlargement, which can be confused with cerebral atrophy or periventricular leukomalacia where the ventriculomegaly instead results from shrinkage of the periventricular white matter. Magnetic resonance elastography (MRE) may be able to differentiate these two types of ventricular enlargement based on poroelastic mechanical property differences, thus offering a new imaging signature for definitive HC diagnosis. In this report, a previously described¹ ‘intrinsic activation’ method was applied to estimate poroelastic brain tissue mechanical properties in a series of patients suffering from HC. Results from the HC patient group were compared with the poroelastic mechanical property responses from a set of normal controls.

Methods:

A phase-contrast MR angiography sequence was used to measure the natural pulsation velocity of brain tissue, which was acquired at 8 distinct phase offsets gated to the cardiac cycle. Since velocity is related to displacement, a 3D deformation field can be extracted and used for poroelastic image reconstruction. Similar processing techniques described in previous works^{1,2} were applied to estimate the shear modulus and pore fluid pressure throughout the MRE acquisition volume. Four normal subjects were scanned 3 times each on 3 separate days. A group of 5 hydrocephalus patients were scanned using the identical methods. Mean shear modulus and pore fluid pressure in the ventricles and the rest of the brain parenchyma were calculated and compared across the two groups.

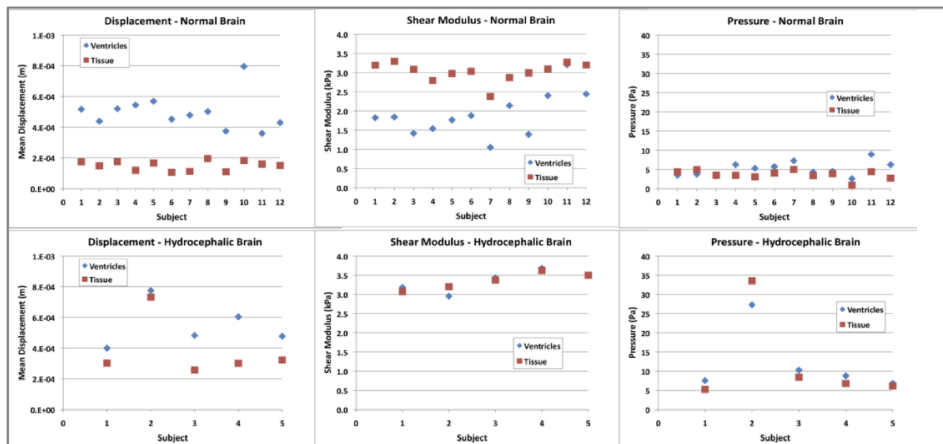


Figure 1 - Mean displacement (left column), shear modulus (middle) and pore-pressure (right) for all normal (top row) and hydrocephalic patients (bottom).

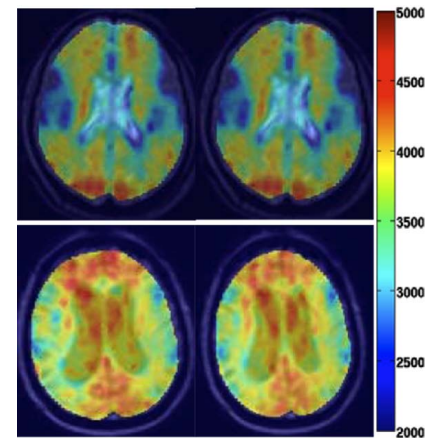


Figure 2 - Shear modulus elastograms of normal (top row) and HC (bottom) patients (in Pascals).

Results:

Significant differences were seen between groups. The acquired displacement fields show differences in magnitude, especially noticeable in the ventricles ($p < 0.01$, seen in Fig. 1). Shear reconstructions are quite different as well, with a significantly higher value in the ventricles of HC patients versus normal subjects ($p < 0.001$, seen in Fig. 1 and Fig. 2). Thirdly, the pore-pressure estimates show an increase in global pore-pressure for HC patients when compared to normal subjects ($p = 0.02$, seen in Fig. 1).

Conclusions:

Measuring the intrinsic pulsatile motion of the brain is sufficient for estimating poroelastic brain tissue properties and eliminates the need for more cumbersome external actuation methods. Preliminary results shown here indicate that the technique may offer a new imaging signature for definitive HC diagnosis which currently is not available through standard MRI or CT exams. Acquired displacements, estimated shear modulus, and estimated pore-pressure all show statistically significant differences in HC patients relative to a group of normal control subjects.

References:

- Pattison, et al. "Poroelastic MRE reconstructions of brain acquired with intrinsic activation" Proceedings of ISMRM. 2010; 18(3404): Stockholm, Sweden.
- Perrinez et al. "Magnetic resonance poroelastography: An algorithm for estimating the mechanical properties of fluid-saturated soft tissues" *IEEE transactions on medical imaging*. 2010; 29(3):746-55.