

SELECTIVE GRAY MATTER ATROPHY IN THE PAIN-MATRIX NETWORK IN CLUSTER HEADACHE

M. Absinta^{1,2}, M. A. Rocca^{1,2}, B. Colombo², A. Falini³, G. Comi², and M. Filippi^{1,2}

¹Neuroimaging Research Unit, Institute of Experimental Neurology, Division of Neuroscience, Scientific Institute and University Hospital San Raffaele, Milan, Italy, ²Department of Neurology, Scientific Institute and University Ospedale San Raffaele, Milan, Italy, ³Department of Neuroradiology, Scientific Institute and University Hospital San Raffaele, Milan, Italy

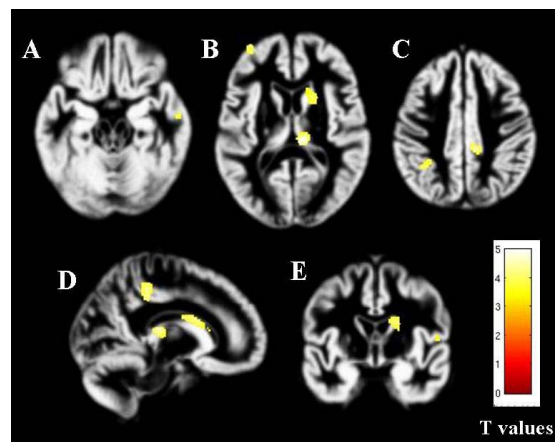
Introduction. Morphologic and functional imaging studies [1] have indicated that a primary hypothalamic dysfunction might have a role in the pathogenesis of cluster headache (CH), whereas a few neurophysiologic and metabolic studies have suggested a more global dysfunction of central modulation of peripheral stimuli in these patients [2].

Objective. Aim of this study is to assess the pattern of regional abnormalities in the white matter (WM) and gray matter (GM) in patients with CH, using tract-based spatial statistics (TBSS) and voxel-based morphometry (VBM).

Methods. Using a 3.0 Tesla scanner, dual-echo, diffusion tensor (DT) and 3D T1-weighted scan were acquired from 15 patients with chronic CH (10 with a right and 5 with a left lateralization of the cluster attacks), and 19 sex- and age-matched controls. TBSS analysis was performed using FMRIB's Diffusion Toolbox. From 3D T1-weighted images, VBM was performed using SPM8 and DARTEL. This latter analysis was performed with and without mirroring the hemispheres of 5 patients with a left lateralization of the attacks.

Results. No abnormalities of the brain WM were detected in patients with CH. Compared to controls, CH patients showed GM atrophy in the right (R) thalamus, head of the R caudate nucleus, bilateral (B) posterior cingulate cortex, B middle frontal gyrus, left (L) precuneus, R middle temporal gyrus and R precentral gyrus ($p < 0.001$, cluster extent more than 10 voxels) [Figure 1]. Similar results were obtained after mirroring of the hemispheres in 5 patients. This latter analysis showed no volume abnormalities in the hypothalamus. MFG atrophy was significantly correlated with disease duration ($r = -0.79$, $p < 0.001$).

Figure 1. Gray matter areas which were significantly atrophied in CH patients vs. healthy controls.



Conclusions. Similar to other chronic pain condition [3-6], CH patients have structural abnormalities in GM regions that are part of the antinociceptive system.

References 1) May A. et al., Lancet 1998; 2) May A. J Headache Pain 2006; 3) Schmidt-Wilcke T et al. Neurology 2005; 4) Schmidt-Wilcke T et al. Pain 2006; 5) Rodriguez-Raecke R et al. J Neurosci 2009; 6) Draganski B et al. Neuroimage 2006.