

HIGH-RESOLUTION SMALL FIELD-OF-VIEW 3 TESLA MRI WITH 32-CHANNEL HEAD COIL BY APPROPRIATELY SELECTED COIL ELEMENTS RECONSTRUCTION METHOD

A. Yamamoto¹, M. Kanagaki¹, T. Okada¹, S. Kozawa², K. Sakai³, and K. Togashi¹

¹Department of Diagnostic Imaging and Nuclear Medicine, Kyoto University Hospital, Kyoto, Kyoto, Japan, ²Clinical Radiology Service, Kyoto University Hospital, Kyoto, Kyoto, Japan, ³Department of Human Health Science, Kyoto University Graduate School of Medicine, Kyoto, Kyoto, Japan

BACKGROUND AND PURPOSE

3-T MRI has been introduced into clinical examinations and is widely used [1]. High-resolution imaging is often essential as a clinical study for the diagnosis of diseases that show only subtle changes in the brain [2]. Since the 32-channel phased-array head coil offers a superb signal-to-noise ratio (SNR), high-quality images can be obtained when used with a 3-T MRI scanner [3]. A small field-of-view (FOV) technique has been proposed to obtain high-resolution images. However, a small FOV will yield images with a phase wrap-around artifact. Several methods are available to reduce phase wrap-around artifacts, such as using spatial saturation bands or phase oversampling methods [4]. If phase oversampling is employed, the number of phase encoding steps increases, prolonging scanning time. When using a 32-channel phased-array head coil, the final images as well as images of each coil element can be obtained. We hypothesized that images could be reconstructed without phase wrap-around artifacts by selecting the appropriate combination of images from 32-coil elements. The purpose of this study was to evaluate an image reconstruction method with a small FOV technique created to avoid the phase wrap-around artifact on the final image.

MATERIALS AND METHODS

A 3T scanner (TrioTim VB15 software version, SIEMENS, Erlangen, Germany) equipped with a 32-channel receive-only phased-array coil was used in this study. A fast spin-echo T2-weighted sequence was obtained.

Scan parameters were as follows: repetition time (TR), 3200 ms; echo time (TE), 79 ms; slice thickness, 3 mm; 35 slices obtained; imaging matrix, 372*448. Phase oversampling and parallel imaging were not used. FOV settings were 182*220 mm (normal) and 91*110 mm (small). In-plane resolution was 0.5*0.5 and 0.25*0.25 mm, respectively. Scanning time was 3 min for each scan. A healthy volunteer was scanned with normal and small FOV settings. After the first scan using a normal FOV, all 32 elements were used for reconstructing the final images. After the second scan using a small FOV, all 32 elements were used for reconstructing the final images. In addition, images from each coil element were reconstructed individually. Reconstructed images were evaluated visually irrespective of whether the phase wrap-around artifact of the image was prominent. After visual evaluation of images for each coil element, appropriate images that showed no prominent phase wrap-around artifact were selected for the reconstruction of final images. The final image reconstruction was performed using ImageJ software (version 1.42) on a 64-bit Windows Vista PC. The sum of square calculations was used to combine images from each channel into the final image.

RESULTS

With a FOV setting of 182*220 mm, T2-weighted image showed no phase wrap-around artifact (Fig. 1). With FOV=91*110 mm, a final image reconstructed from all 32 elements showed a prominent phase wrap-around artifact (Fig. 2). Coil images from the small FOV setting showed prominent phase wrap around in 17 elements (Fig. 3). A final image reconstructed using 15 selected images showed almost no phase wrap-around artifact (Fig. 4). Finer structures were evaluated on the small FOV images.

DISCUSSION

This study obtained high-resolution T2-weighted images without phase wrap-around artifact using a small FOV technique with an appropriately selected coil elements reconstruction method. Since high-resolution 3-T MRI has become widespread [2], this technique will greatly affect clinical studies.

The 32-channel coil offers superb SNR and yields very high quality images [3]. As a result, 3-T MRI with a 32-channel coil represents a very good imaging tool. The 32-channel coil consists of small-diameter surface loop coils. These 32 elements are distributed equally around the head. In routine examinations, images are reconstructed from all 32-channels. When the FOV of the image is smaller than the diameter of the target object, a general reconstruction method with coil images using all 32-elements makes images with prominent phase wrap-around artifact. These phase wrap-around artifacts can obscure the real anatomy being scanned and may interfere with diagnosis. The diameter of each element is relatively small and thus has limited effective sensitivity areas. Individually reconstructed images from each coil element show various degrees of phase wrap-around artifact due to spatial position. These images without prominent phase wrap-around artifact can be reconstructed into the final image. High-resolution images are often essential for diagnosis of brain diseases [2]. With this technique, we can obtain high-resolution images by appropriately selecting images from each coil element. Limitations are as follows. In this study, visual inspection was used for selecting each coil element image for reconstructing final images. In the future, systems for automatically selecting coil elements may be developed for small FOV high-resolution MRI using a 32-channel coil system.

CONCLUSION

High-resolution 3-T MRI using a small FOV technique with appropriately selected coil elements images may be feasible for clinical study and represents a promising tool for clinical studies, such as evaluation of multiple sclerosis, white matter disease, or age-related white matter change.

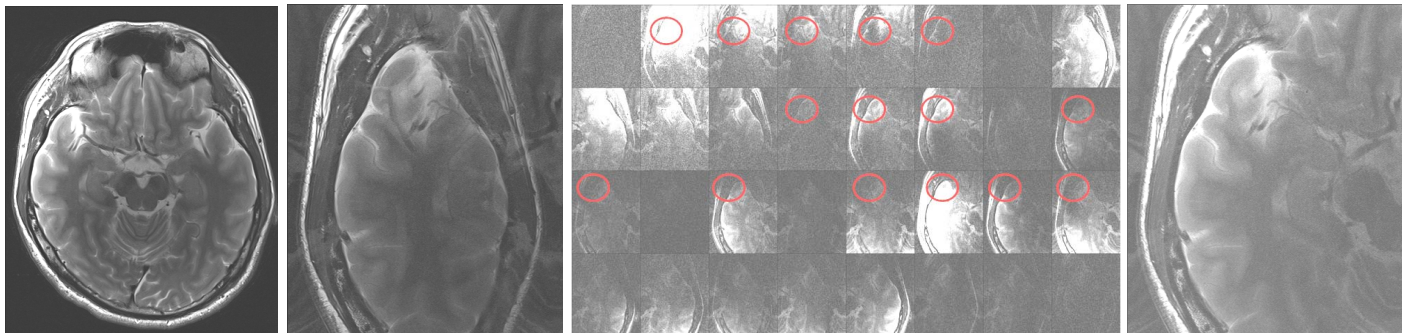


Figure 1

Figure 2

Figure 3

Figure 4

Figure 1. Normal FOV (182*220 mm) T2-weighted image.

Figure 2. Small FOV (91*110 mm) T2-weighted image reconstructed from images from all 32 elements, showing prominent phase wrap around artifact that interferes with evaluation of the right temporal lobe.

Figure 3. Images from each coil element, with red circles showing appropriate images.

Figure 4. Small FOV T2-weighted image reconstructed from appropriate images, showing almost no phase wrap around artifact.

REFERENCES

1. Alvarez-Linera J. 3T MRI: advances in brain imaging. *Eur J Radiol* 2008; 67:415-426.
2. Edelman RR, et al. Rapid whole-brain magnetic resonance imaging with isotropic resolution at 3 Tesla. *Invest Radiol* 2009; 44:54-59.
3. Wiggins GC, et al. 32-channel 3 Tesla receive-only phased-array head coil with soccer-ball element geometry. *Magn Reson Med* 2006; 56:216-223.
4. Stadler A, et al. Artifacts in body MR imaging: their appearance and how to eliminate them. *Eur Radiol* 2007; 17:1242-1255.